

The Value of Yolk Sac Diameter at Vaginal Ultrasonography as a Predictor of the First Trimester Pregnancy Outcome

khaled S. Mousa, Amr Mohamed El- Helaly and Mahmoud Abd El-Aziz

Department of Obstetrics and Gynecology, Faculty of Medicine, Ain Shams University
amrelhelaly@hotmail.com

Abstract: Objective: The aim of this work was to determine the value of using ultrasonographic measurement of both yolk sac diameter and gestational sac diameter in the first trimester for prediction of pregnancy outcome. **Subjects and Methods:** This prospective observational study included 100 pregnant females in their first trimester of singleton pregnancy with no medical diseases. All women were examined by vaginal ultrasound during the 6th week of gestation to measure yolk sac diameter (YSD) and gestational sac diameter (GSD). During the 13th week of gestation, abdominal ultrasound was done to remeasure the sacs and confirm fetal well-being. This examination was the cutoff point of success of pregnancy. **Results:** The YS was measurable in 72 cases, absent in 16 cases and band-shaped in 2 cases. The latter 2 cases are combined with cases of absent YS in one group. YSD had good positive correlation with GSD ($r = 0.709$, $p < 0.001$) and GA ($r = 0.646$, $p < 0.001$). The outcome at the 13th week was normal in 74 women and abnormal in 26. Absence of the yolk sac was significantly associated with abnormal outcome (Odds Ratio (OR): 10.3, 95% CI: 5.3-19.8). Cases with abnormal outcome had significantly smaller yolk sacs and YSD/GSD ratio. $YSD \leq 3.1$ mm predicts abnormal outcome with a sensitivity of 75% and specificity of 63.5%, while $YSD/GSD \leq 0.2$ shows the absolute sensitivity and specificity (100%). $YSD/GA \leq 0.065$ predicts abnormal outcome with 100% sensitivity and specificity. **Conclusion:** Measurement of yolk sac diameter is a good predictor of bad neonatal outcome especially as a ratio to gestational sac diameter. [khaled S. Mousa, Amr Mohamed El- Helaly and Mahmoud Abd El-Aziz. **The Value of Yolk Sac Diameter at Vaginal Ultrasonography as a Predictor of the First Trimester Pregnancy Outcome.** *Life Sci J* 2014;11(1):236-240]. (ISSN:1097-8135). <http://www.lifesciencesite.com>. 35

Keywords: Yolk sac, Gestational sac, Fetal well-being, Vaginal ultrasonography

1.Introduction:

A group of clinical factors including maternal age, race, smoking and history of vaginal bleeding were suggested for prediction of subsequent miscarriages. In addition, ultrasound measurements during the first trimester including crown-rump length (CRL), embryonic heart rate (HR), gestational sac diameter (GSD) and yolk sac diameter (YSD) were utilized. Numerous studies reported contradictory results of the value of these measurements in the prediction of subsequent miscarriage.[1-10]

In the first trimester, the yolk sac is one of the most important conceptional structures that can be assessed using ultrasonography. Yolk sac is the primary route of embryo-mother exchange during embryonic development. Before complete establishment of placental circulation, it has nutritional, metabolic, immunologic, endocrine, and hematopoietic functions essential in early embryonic life.[11] Sonographic evaluation of the yolk sac can be beneficial in confirmation of an intrauterine pregnancy and prediction of gestational outcome through assessment of its shape, size, and internal structure.[12,13]

Transvaginal sonography can detect the yolk sac as early as the 5th week of pregnancy.[12] It should

be clearly observed when the gestational sac measures more than 8 mm.[14] Normally, it appears as a round structure with an anechoic center surrounded by a uniformly thick and well-defined echogenic wall.[15] Usually the inner diameter of the yolk sac measures 3-5 mm. Its size increases progressively from the 5th gestational week to the end of the 10th gestational week; subsequently it decreases in size gradually.[16]

The yolk sac size and shape have been suggested as sensitive predictors of pregnancy outcome. Several studies investigated the importance of the yolk sac size and echogenicity in early pregnancy to determine pregnancy outcome.[7,11,17-20] Fewer studies focused on the importance of the yolk sac shape in early pregnancy.[11,19,20] Absence of the yolk sac is generally associated with subsequent embryonic death. [11,19,21]

Gestational sac diameter has been described in first-trimester gestations from 5 weeks from the last menstrual period onwards.[22-24] Prior to 5 weeks of gestation measurement of gestational sac did not prove useful in predicting outcome of the pregnancy. However, a number of studies have shown that a smaller than expected gestational sac diameter predicts imminent pregnancy loss from 5.5 weeks' gestation and above.[2,25,26]

The aim of this work was to determine the value of using ultrasonographic measurement of both yolk sac diameter and gestational sac diameter in the first trimester for prediction of pregnancy outcome.

2. Subjects and Methods:

This prospective observational study was performed in the antenatal care department, Maternity Hospital, Ain-Shams University during the period from July 2008 to July 2009. It included 100 pregnant females in their first trimester with singleton pregnancy. All women were below 35 years old. Gestational age was confirmed by sure date of the last menstrual period (LMP). Pregnancies complicated by medical diseases as diabetes mellitus, hypertension, SLE, etc. were excluded.

After careful general medical examination, complete urine analysis, blood sugar and complete blood count were performed. All women were examined by vaginal ultrasound during the 6th week of gestation to measure yolk sac diameter (YSD) and gestational sac diameter (GSD). During the 13th week of gestation, abdominal ultrasound was done to remeasure the sacs and confirm fetal well-being. This examination was the cutoff point of success of pregnancy. The ultrasound apparatus was SonaAce 1500 (Medison Corporation) with a 6.5 MHz vaginal probe and a convex 3.5 MHz abdominal one. All women provided a verbal informed consent.

Vaginal ultrasonography procedure:

The woman was advised to empty her bladder before examination. Gestational age diameter was confirmed by measurement of the crown-rump length. After gaining a clear image on the monitor and visualization of gestational sac (GS) and yolk sac (YS), the internal diameters of both sacs were measured in two perpendicular planes and the mean diameters were calculated. One image of the YS and GS is taken for the apparent normal cases at the sixth week. If YS is absent in the first sonar or there is abnormality in the shape or size of the GS, a follow up vaginal ultrasound is taken, up to four times in some cases. In these cases, up to four or five images are taken. Involved women were instructed to report

any vaginal bleeding or pelvic pain to the investigators. If no complications have occurred, they were invited a follow up visit on the 13th week, for abdominal ultrasonography checking success of pregnancy. At the thirteenth week, the outcome of pregnancy is evaluated. Outcome is considered normal if intact gestational sac with a living fetus on abdominal ultrasonography is visualized. Women with inevitable abortions during previous weeks and those with non-viable pregnancy on confirmed by abdominal ultrasonography were considered abnormal outcome.

Some pregnant females, at their sixth week of gestation, refused to perform vaginal ultrasound they are excluded and replaced. Also, some other women were lost to the follow up visit during the 13th week. All these cases were also replaced.

Statistical Analysis:

Data was analyzed using IBM SPSS Advanced Statistics version 20 (SPSS Inc., Chicago, IL). Numerical data were expressed as mean and standard deviation or median and range as appropriate. Qualitative data were expressed as frequency and percentage. For quantitative data, comparison between two groups was done using Mann-Whitney test. Spearman-rho method was used to test correlation between numerical variables. Odds ratio (OR) with it 95% confidence interval (CI) were used for risk estimation. The Receiver Operating Characteristic (ROC) curve was used for prediction of cut off values. A *p*-value < 0.05 was considered significant.

3. Results:

Table 1 shows maternal age, gestational age and diameters of YS and GS of the whole group of 100 women. The YS was measurable in 72 cases, absent in 16 cases and band-shaped in the remaining two cases. For statistical purposes, the two cases of the band-shaped YS are combined with cases of absent YS in one group. YSD had good positive correlation with GSD ($r = 0.709$, $p < 0.001$) and GA ($r = 0.646$, $p < 0.001$).

Table 1: Maternal age, gestational age and diameters of YS and GS of the whole studied group (n = 100)

| | Mean±SD | Median (Range) |
|------------------------------|------------|---------------------|
| Maternal Age (years) | 26.77±4.33 | 26.50 (19.00-34.00) |
| Duration of pregnancy (days) | 46.40±4.01 | 45.00 (41.00-60.00) |
| GSD (mm) | 13.83±4.37 | 13.75 (2.00-25.00) |
| YSD (mm)* | 3.64±0.78 | 3.50 (2.70-7.00) |
| GSD/YSD ratio* | 3.99±0.93 | 3.75 (2.68-7.00) |
| YSD/GSD ratio* | 0.26±0.05 | 0.27 (0.14-0.37) |

* data for only 72 cases with measureable YS

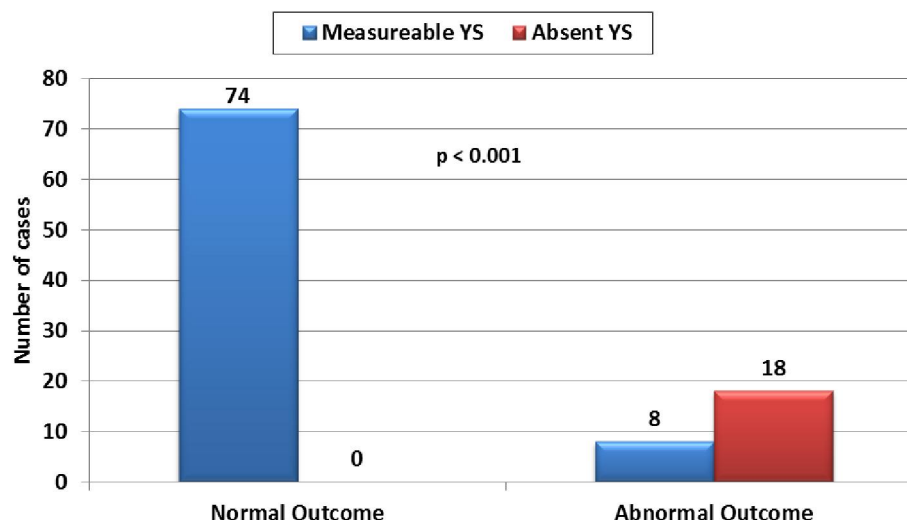


Figure 1: Relation between condition of the yolk sac and the outcome of pregnancy

During the follow up visit during the 13th week, the outcome of the study was determined and accordingly, women were classified into two groups; those with normal outcome ($n = 74$) and others with abnormal outcome ($n = 26$). Figure 1 shows relation between the outcome and condition of the yolk sac. Absence of the yolk sac was significantly associated

with abnormal outcome ($p < 0.001$) with an Odds Ratio (OR) of 10.3 (95% CI: 5.3-19.8). Table 2 shows a comparison between normal and abnormal outcome groups regarding diameters of GS and YS and their ratios. Cases with abnormal outcome had significantly smaller yolk sacs and YSD/GSD ratio.

Table 2: Diameters of GS and YS and their ratios in cases with normal and abnormal outcome

| | Abnormal Outcome | | Normal Outcome | | <i>p</i> value |
|----------------|------------------|------------|----------------|------------|----------------|
| | <i>n</i> | Mean±SD | <i>n</i> | Mean±SD | |
| GSD (mm) | 26 | 13.68±5.93 | 74 | 13.88±3.72 | 0.903 |
| YSD (mm)* | 26 | 3.13±0.35 | 74 | 3.70±0.80 | 0.019 |
| GSD/YSD ratio* | 8 | 6.53±0.45 | 74 | 3.72±0.39 | < 0.001 |
| YSD/GSD ratio* | 8 | 0.15±0.01 | 74 | 0.27±0.03 | < 0.001 |

Using ROC curve analysis, $YSD \leq 3.1$ mm predicts abnormal outcome with a sensitivity of 75% and specificity of 63.5%. However, the YSD/GSD ratio ≤ 0.2 shows the absolute sensitivity and specificity (100%) for prediction of abnormal outcome of pregnancy. Similarly, YSD/GA (in days) ≤ 0.065 predicts abnormal outcome with 100% sensitivity and specificity.

4. Discussion:

This study demonstrated that absence of yolk sac during the 6th week of gestation is a predictor of abnormal outcome of pregnancy with an Odds Ratio of 10.3 (95% CI: 5.3-19.8). A ratio of yolk sac diameter to gestational sac diameter ≤ 0.2 had a 100% sensitivity and specificity for prediction of abnormal outcome of pregnancy. Yolk sac diameter only was a weaker predictor of abnormal outcome (75% sensitivity and 63.5% specificity).

Absent yolk sac was previously investigated as a sonographic predictor of early pregnancy failure. Nyberg et al. found that absence of yolk sac with a GSD ≥ 20 mm had a low sensitivity, but 100% specificity for prediction of abnormal outcome.[27,28] The two studies included women with threatened abortion. Using endovaginal US, the absence of a yolk sac predicted a nonviable pregnancy with a sensitivity of 67% and a specificity of 100% in 59 patients with gestation sacs ≥ 8 mm.[29] In a prospective study of 211 pregnancies complicated by threatened abortion and empty gestation sacs diagnosed by transvaginal ultrasound a mean sac diameter ≥ 13 mm without visible yolk sac was the most sensitive criterion for prediction of non-viable pregnancy (96% sensitivity and 100% specificity).[30]

The combination of absence of cardiac activity and absence of a yolk sac on transvaginal sonography appeared to be a highly specific criterion of non-

viability whenever the mean sac diameter is ≥ 16 mm.[31] However, in a large retrospective study of 2,655 first-trimester US scans, reliability of absent YS was questioned by Rowling *et al.* They reported normal pregnancy outcome in 22% of patients without yolk sacs.[32]

In the current study, YSD as a sole parameter was a rather weak predictor of abnormal outcome of pregnancy. Low sensitivity of small YSD was reported in previous studies. A YS diameter 2SD below the mean predicted an abnormal pregnancy outcome with a sensitivity of 15.6% and a specificity of 95.3%.[11] Stampone *et al.* reported a sensitivity of 68.7% and a specificity of 99%. [7] Similar figures (sensitivity 65% and specificity of 97%) were also reported by Küçük *et al.*[19].

A recent prospective cohort study of 219 women concluded that absence or small yolk sac can predict poor pregnancy outcome during the first 12 weeks with a good accuracy. Combination of gestational age and YSD resulted in an area under the ROC curve of 0.858.[33] On the contrary, Chama *et al.* reported a higher sensitivity for a small sized YS for predicting abnormal pregnancy outcome. They found that a YSD above or below 2 SD from the mean predicted abnormal pregnancy outcome with a sensitivity of 91.4%, specificity of 66%. In addition a normal YS size predicted normal pregnancy outcome with a sensitivity of 66%, specificity of 91.4%.[34]

In the current study, ratio of YSD to GSD or gestational age predicts poor outcome with 100 sensitivity and specificity. We believe that using the YSD/GSD ratio is a better measure for prediction of pregnancy outcome owing to the wide variability in the sac diameters and the rate of growth of gestational sac.

A recent study of 1060 intrauterine pregnancies of uncertain viability reported an overlap in mean sac diameter growth rates between viable and non-viable pregnancies without a definite cut-off to mark viability. Based on these findings, they consider criteria to diagnose miscarriage based on growth in gestational sac and even crown-rump length potentially unsafe.[35]

Corresponding author

Amr Mohamed El- Helaly

Department of Obstetrics and Gynecology, Faculty of Medicine, Ain Shams University
amrelhelaly@hotmail.com

References:

1. Jauniaux E, Jurkovic D, Henriot Y, Rodesch, Hustin J. Development of the secondary human yolk sac: correlation of sonographic and

anatomical features. Hum Reprod. 1991;6:1160-6.

2. Nazari A, Check JH, Epstein RH, Dietterich C, Farzanfar S. Relationship of small-for-dates sac size to crown-rump length and spontaneous abortion in patients with a known date of ovulation. ObstetGynecol. 1991;78:369-3.
3. Dickey RP, Gasser R, Olar TT, Taylor SN, Curole DN, Rye PH, Matulich EM. Relationship of initial chorionic sac diameter to abortion and abortus karyotype based on new growth curves for the 16th to 49th post-ovulation day. Hum Reprod. 1994a;9:559-65.
4. Dickey RP, Gasser RF, Olar TT, Curole DN, Taylor SN, Matulich EM, West JD, Tsien F. The relationship of initial embryo crown—rump length to pregnancy outcome and abortus karyotype based on new growth curves for the 2–31 mm embryo. Hum Reprod. 1994b;9:366-73.
5. Wisser J, Dirscheid P. Embryonic heart rate in human dated embryos. Early Hum Dev. 1994;37:107-15.
6. Ikegawa A. Prediction of first-trimester miscarriage from embryonic bradycardia and embryonic growth delay. J ObstetGynaecol. 1995;21:537-44.
7. Stampone C, Nicotra M, Muttinelli C, Cosmi E V. Transvaginalsonography of the yolk sac in normal and abnormal pregnancy. J Clin Ultrasound. 1996;24:3-9.
8. Reljic M. The significance of crown-rump length measurement for predicting adverse pregnancy outcome of threatened abortion. Ultrasound Obstet Gynecol. 2001;17:510-2.
9. Makrydimas G, Sebire NJ, Lolis D, Vlassis N, Nicolaides KH. Fetal loss following ultrasound diagnosis of a live fetus at 6–10 weeks of gestation. Ultrasound Obstet Gynecol. 2003;22:368-72.
10. Chittachoen A, Herabutya Y. Slow fetal heart rate may predict pregnancy outcome in first-trimester threatened abortion. Fertil Steril. 2004;82:227-9.
11. Lindsay DJ, Lovett IS, Lyons EA, et al. Yolk sac diameter and shape at endovaginal US: predictors of pregnancy outcome in the first trimester. Radiology. 1992; 183:115-8.
12. Makikallio K, Tekay A, Jouppila P. Yolk sac and umbilicoplacental hemodynamics during early human embryonic development. Ultrasound Obstet Gynecol. 1999; 14:175–9.
13. Tan S, Ipek A, Pektas MK, Arifoğlu M, Teber MA, Karaoğlu M. Irregular yolk sac shape: is it really associated with an increased

- risk of spontaneous abortion? *J Ultrasound Med*. 2011; 30:31-6.
14. Lyons EA, Levi CS. The first trimester. In: Rumack CM, Wilson SR, Charboneau JW (eds). *Diagnostic Ultrasound*. 3rd ed. St Louis, MO: CV Mosby Co; 2005:1070-100.
 15. Levi CS, Dashefsky SM, Lyons EA, Holt CS, Lindsay DJ. First-trimester ultrasound. In: McGahan JP, Goldberg BB (eds). *Diagnostic Ultrasound: A Logical Approach*. 1st ed. Philadelphia, PA: Lippincott-Raven. 1997:134-48.
 16. Nyberg DA, Mack LA, Harvey D, Wang K. Value of the yolk sac in evaluating early pregnancies. *J Ultrasound Med*. 1988;7:129-35.
 17. Berdahl DM, Blaine J, Van Voorhis B, Dokras A. Detection of enlarged yolk sac on early ultrasound is associated with adverse pregnancy outcomes. *Fertil Steril*. 2010; 94:1535-7.
 18. Harris RD, Vincent LM, Askin FB. Yolk sac calcification: a sonographic finding associated with intrauterine embryonic demise in the first trimester. *Radiology* 1988;166:109-10.
 19. Küçük T, Duru K, Yenen MC, Dede M, Ergün A, Başer I. Yolk sac size and shape as predictors of poor pregnancy outcome. *J Perinat Med*. 1999;27:316-20.
 20. Cho FN, Chen SN, Tai MH, Yang TL. The quality and size of yolk sac in early pregnancy loss. *Aust NZ J Obstet Gynaecol*. 2006;46:413-8.
 21. Levi CS, Lyons EA, Martel MJ. Sonography of multifetal pregnancy. In: Rumack CM, Wilson SR, Charboneau JW (eds). *Diagnostic Ultrasound*. 3rd ed. St Louis, MO: CV Mosby Co; 2005:1185-6.
 22. Britten S, Soenksen DM, Bustillo M, Coulam CB. Very early (24–56 days from last menstrual period) embryonic heart rate in normal pregnancies. *Hum Reprod*. 1994;9:2424-6.
 23. Coulam CB, Britten S, Soenksen DM. Early (34–56 days from last menstrual period) ultrasonographic measurements in normal pregnancies. *Hum Reprod*. 1996;11:1771–4.
 24. Coulam CB, Goodman C, Dorfmann A. Comparison of ultrasonographic findings in spontaneous miscarriages with normal and abnormal karyotypes. *Hum Reprod*. 1997;12:823-6.
 25. Bromley B, Harlow BL, Laboda LA, Benacerraf BR. Small sac size in the first trimester: a predictor of poor fetal outcome. *Radiology*. 1991;178:375-7.
 26. Dickey RP, Olar TT, Taylor SN, Curole DN, Matulich EM. Relationship of small gestational sac-crown-rump length differences to abortion and abortus karyotypes. *Obstet Gynecol*. 1992;79:554-7.
 27. Nyberg DA, Laing FC, Filly RA. Threatened abortion: sonographic distinction of normal and abnormal gestation sacs. *Radiology*. 1986;158:397-400.
 28. Nyberg DA, Mack LA, Laing FC, Patten RM. Distinguishing normal from abnormal gestational sac growth in early pregnancy. *J Ultrasound Med* 1987;6:23-7.
 29. Levi CS, Lyons EA, Lindsay DJ. Early diagnosis of non-viable pregnancy with endovaginal ultrasound. *Radiology*. 1988;167:383-5.
 30. Tongsong T, Wanapirak C, Srisomboon J, Sirichotiyakul S, Polsrisuthikul T, Pongsatha S. Transvaginal ultrasound in threatened abortions with empty gestational sacs. *Int J Gynaecol Obstet*. 1994;46:297-301.
 31. Schouwink MH, Fong BF, Mol BW, van der Veen F. Ultrasonographic criteria for non-viability of first trimester intra-uterine pregnancy. *Early Pregnancy*. 2000;4(3):203-13.
 32. Rowling SE, Coleman BG, Langer JE, Arger PH, Nisenbaum HL, Horii SC. First-trimester US parameters of failed pregnancy. *Radiology*. 1997;203(1):211-7.
 33. Varelas FK, Prapas NM, Liang RI, Prapas IM, Makedos GA. Yolk sac size and embryonic heart rate as prognostic factors of first trimester pregnancy outcome. *Eur J Obstet Gynecol Reprod Biol*. 2008;138(1):10-3.
 34. Chama CM, Marupa JY, Obed JY. The value of the secondary yolk sac in predicting pregnancy outcome. *J Obstet Gynaecol*. 2005;25(3):245-7.
 35. Abdallah Y, Daemen A, Guha S, Syed S, Naji O, Pexsters A, Kirk E, Stalder C, Gould D, Ahmed S, Bottomley C, Timmerman D, Bourne T. Gestational sac and embryonic growth are not useful as criteria to define miscarriage: a multicenter observational study. *Ultrasound Obstet Gynecol*. 2011;38(5):503-9.