

## Light and Electron Microscopic Study on the Effect of Different Forms of Allopurinol on the Kidney and Liver of Adult Male Albino Rat

Ashraf H. Abd-Elhakem

Anatomy Department, Assiut University, College of Medicine, Assiut-Egypt

**Abstract:** Allopurinol is used in the treatment of gout, leishmaniasis, renal stone formation and in prophylaxis of hyperuricemia and its complications associated with radiation therapy. Allopurinol is associated with multiple side effects in certain cases which include glomerulonephritis, nephritis, elevated hepatic enzymes, hepatic necrosis, leucopenia, purpura and allergic diseases. Little researches showed that a steep dose-response relationship exists between allopurinol and its side effects. Some of these researches on the microcapsulation of allopurinol, which can reduce its side effects to a great extent. The aim of the present study was to investigate and compare the effects of sustained release microcapsule, no uric allopurinol and pure allopurinol on the kidney and liver of adult male albino rats. The present study was conducted on 40 adult male albino rats of Sprague-Dawley strain (from Assiut University animal house). The rats were randomly classified into four groups (ten rats each). The control group, rats of which were left in animal house without any treatment and received vehicle only. The three treated groups received three different forms of allopurinol at dose 25 mg/kg of body weight daily for 14 consecutive days. Group II (the sustained release allopurinol microcapsule group) rats of which were given the allopurinol microcapsule suspension which proved sustained release. Group III (the No-Uric group) rats of which were given no-uric suspension. Group VI (the pure allopurinol group) rats of which were given pure allopurinol suspension. Both kidneys and liver of the four groups were removed from the animals and processed for routine histological and electron microscopic examination. Kidney and liver of group II (the sustained release allopurinol microcapsule group) is more or less similar to the control group. In group III (the No-Uric group) and group IV (the pure allopurinol group) the glomerular space is significantly dilated, the proximal convoluted tubules are significantly reduced in their epithelial height and areas of hemorrhage observed between the tubules and deposits inside the loop of Henle. The electron microscopic picture of the glomeruli shows partial thickening of the glomerular basement membrane, disturbed capillary endothelium, irregularity of the minor processes of the podocytes and areas of glomerular sclerosis. The proximal and distal convoluted tubules show cytoplasmic vaculation, cytoplasmic dense bodies, degenerated mitochondria and decrease basal enfolding. The proximal convoluted tubules show destruction of the microvilli. The liver of group III (the No-Uric group) and group IV (the pure allopurinol group) shows areas of hemorrhage both in the central part of the hepatic lobule and on the peripheral part. The electron microscopic picture of the hepatocytes show vacuolated cytoplasm, necrotic changes and the cord pattern is disturbed. The electron microscopic picture of the hepatocytes show marked reduction of the cytoplasmic organelles, degenerative changes in the mitochondria and little amount of rough endoplasmic reticulum. The nucleus is shrunken, little chromatin material and the nuclear membrane is irregular. Conclusion: the sustained release microcapsule allopurinol may lead to prolonged activity with avoidance of renal and hepatic side effects of frequent administration of allopurinol. These results may have clinical significance in the prevention of some side effects of allopurinol on kidney and liver.

[Ashraf H. Abd-Elhakem. **Light and Electron Microscopic Study on the Effect of Different Forms of Allopurinol on the Kidney and Liver of Adult Male Albino Rat.** *Life Sci J* 2012;9(3):1100-1112]. (ISSN: 1097-8135). <http://www.lifesciencesite.com>. 153

**Key words:** Allopurinol, Kidney, Liver, Histological Effect.

### 1. Introduction

Allopurinol is a xanthine oxidase inhibitor used widely in treatment of gout, leishmaniasis, renal stones and complications associated with radiation therapy (Martindale, 1999; Tausche *et al.*, 2008 and Aldaba-Muruato *et al.*, 2012). Allopurinol is widely used and generally well-tolerated (Dawson *et al.*, 2009 and Woo *et al.*, 2012). However, in certain cases it may have toxic effects, such as vasculitis, toxic epidermal necrolysis, eosinophilia, hepatitis, reduced renal function and bone marrow suppression,

known as allopurinol hypersensitivity syndrome (Liu *et al.*, 2008; Teo *et al.*, 2011 and Biagioni *et al.*, 2012). But this syndrome is rare (Arabi *et al.*, 1996; El-Gibaly, 1998 and Horiuchi *et al.*, 2000). Several studies in the past two decades have suggested that elevated serum uric acid levels are associated with cardiovascular diseases (Viazzì *et al.*, 2006; Lippi *et al.*, 2008; Neogi *et al.*, 2011 and Krishnan *et al.*, 2011). Simultaneous reduction in uric acid levels by allopurinol might contribute to the reduction in its

side effects (Stocker & Kearney, 2004; Glantzounis *et al.*, 2005 and Puddu *et al.*, 2012).

George *et al.* 2006 showed that a steep dose-response relationship exists between allopurinol and its effects on endothelial dysfunction in patients with chronic heart failure.

Limited work has been reported on the different forms of allopurinol, which can reduce the side effects of the drug to a great extent (Spiegel & Abd-El-Fatah, 1977 and El-Gibaly *et al.*, 2003).

Various techniques of sustained release microcapsulation can be employed for the production of multiparticulated sustained-released polymeric drug delivery system (Deasy, 1984 and Arshady, 1989). The oil-in-water meltable disperse-phase encapsulation method has been reported to be simple and useful in the preparation of beeswax matrix microspheres loaded with appropriate drugs without using harmful organic solvents (Bodmeier *et al.*, 1992; Adeyeye and Price, 1994; Giannola *et al.*, 1995 and Uddin *et al.*, 2001).

#### **Aim of the Work:**

The aim of the present work is to investigate and compare the effects of different forms of allopurinol in adult male albino rat's kidney and liver.

#### **2. Material and Methods**

The present study was conducted on 40 adult male albino rats of Sprague-Dawley strain (from Assiut University animal house). Rats were selected for age (2-3 months) and weight (150-200 grams). They were put at constant normal temperature with the natural light dark cycle. Manipulations throughout test were carried out by the same person. The rats were fed a standard diet of commercial rat chow and tap water and left to acclimatize to environment for two weeks prior to inclusion in the experiment. All experiments were performed during the same time of day, between 10 am and 1pm to avoid variations due to diurnal rhythms.

The rats were randomly classified into four groups (ten rats each) and received the tested compound by gastric intubation (in 0.1 M NaHCO<sub>3</sub> containing 0.02% of Tween 80, PH7.4). All treatments were administered into rats following 12 hours of fasting. All the materials used in this study were of analytical reagent grade and were used as received.

Group I: control group, rats of which was left in animal house without any treatment and received vehicle only.

Group II: the sustained release allopurinol microcapsular group, rats of which was given the allopurinol microcapsule suspension (mean size 120  $\mu$ m) (1 gm / 20 ml) at dose 25 mg/kg of body weight daily for 14 consecutive days.

Group III: the no-uric group, rats of which was given No Uric 100 mg tablet in the form of suspension by mouth (100 mg/12 ml) at dose 25 mg/kg of body weight daily for 14 consecutive days.

Group IV: the pure allopurinol group, rats of which was given pure allopurinol suspension (8 mg/ ml) at dose 25 mg/kg of body weight daily for 14 consecutive days.

#### **Preparation of allopurinol loaded microparticle formulations:**

Microparticle formulations are produced using the modified emulsion encapsulation procedure adopted (Vilivalam and Adeyeye, 1994). The microparticles formulations were prepared by melting the wax components (4g), unless otherwise specified, consisting of beeswax and wax modifiers. This constitutes the organic or oil phase. The drug was dispersed in the respective molten wax (in a 1:4 drug to wax ratio) under continuous stirring using a magnetic stirrer (J.P. Selecta, s.a., Spain) until a homogeneous blend was attained. This mixture was then poured into 100 ml of the encapsulation dispersant (PF-68: 0.25g) solution (aqueous phase) with constant stirring using a mechanical stirrer (Wheaton Instrument, Millville, NJ, USA) at a predetermined speed of 400 rpm to form an oil-in-water emulsion. During the emulsification step (1 min), the temperature of the aqueous phase was kept slightly higher (~5°C) than the highest melting point of any of the oil phase. The molten mass upon dispersion in the aqueous medium formed a spherical oily particle, which solidified enveloping the drug upon rapid cooling of the emulsion using chilled water (4 °C). The resultant microparticles were then filtered extensively washed with deionized water and air dried at room temperature for 48hrs.

#### **Histological Methods:**

Liver and kidney were removed from animals and fixed in 10% formaldehyde, dehydrated in ascending grades of alcohol, and then after embedded in paraffin wax. Serial sections (10  $\mu$ m) thickness were prepared and stained with Haematoxylin and Eosin stain and others by Van Gisson stain, then examined by light microscopy (Drury & Willington, 1980 and Bancroft & Stevens, 1982).

Other specimens of the kidney and liver were prepared for electron microscopic study according to (Griffith *et al.*, 1973). The specimens were fixed in 2.5% gluteraldehyde for 2 hours. Then washed 3 times (5 minutes each) in phosphate buffer and were postfixed in 1% osmium tetroxide for 2 hours, then washed 3 times (5 minutes each) in phosphate buffer.

The specimens were dehydrated in ascending grades of ethyl alcohol: 50%, 60%, 70%, 80 %,90 % and in absolute alcohol (two changes, 30 minutes

each), then in propylene oxide (two changes, 30 minutes each). They were ultimately immersed in a propylene-epon mixture (1:1) for 24 hours.

The specimens were embedded in plastic capsules containing epon and left to polymerize in an incubator at 60 °C for 3 days. The ultrathin sections were stained with 1% uranyl acetate and 1% lead citrate and examined by transmission electron microscope.

### Morphometric Methods:

The glomerular diameter, glomerular space and the tubular epithelial thickness (of the proximal convoluted tubules) were measured by using a scale slide and Lucida lens. Five slides from each animal were used for these measurements. The slides were chosen from mid area of the kidney and the hilum was taken as a guide for this site. The equation used was:  $Magnification = Image\ length / Natural\ length$ .

Statistical analysis of the data was done using student t-test and the data expressed in mean and stander deviation.

### 3. Results

#### Kidney Results

The structure of the kidney of the rats received the microcapsular allopurinol preparation is more or less similar to the control group both by Haematoxylin and Eosin stain (fig. 1,2, 9&10) and also by Van Gisson stain (fig. 5,6, 13&14). The glomeruli are surrounded by proximal and distal convoluted tubules. The glomerular capillaries have darkly-stained nuclei. The glomerular capsule is surrounded by the glomerular space that lined externally by flat darkly stained nuclei. The afferent arteriole is adherent to one pool of the glomerulus. The proximal convoluted tubules stained more deeply relative to the distal tubules and have an obvious brush border. The proximal convoluted tubules tend to be larger in diameter and more irregular than those of distal convoluted tubules. The distal convoluted tubules are paler and the nuclei of their cells appear more regularly arranged (fig. 1 & 2). The glomerular capillaries are composed of condensed capillary tuft with deeply stained nuclei and deeply stained cytoplasm. The parietal part of glomerular capsule show flat darkly stained nuclei (fig. 1 & 2).

The glomeruli of the rats received no-uric and pure allopurinol show significant dilatation of their

glomerular space (fig. 3& 4 and tab. 1) on comparing with the control rats. They also show significant reduction in their size (figs 3& 4 and tab. 1) on comparing with the control rats.

The proximal convoluted tubules of the rats received no-uric and pure allopurinol show significant reduction. epithelial thickness on comparing with the control rats (fig. 3&4 and tab. 1), and areas of hemorrhage (fig. 7, 8, 11 & 12) in between them. Casts inside the loop of Henle (fig. 15&16) also observed.

The electron microscopic picture of the renal glomeruli of the rats received no-uric and pure allopurinol show partial thickening of the glomerular basement membrane, disturbed capillary endothelium, irregularity of the minor processes of the podocytes and areas of glomerular sclerosis (figs. 27 and 28) comparing with the control animals (fig. 25). The electron microscopic picture of the renal glomeruli of the rats received the sustained release microcapsular preparation (fig. 26) is more or less similar to the control group (fig. 25).

The electron microscopic picture of the proximal convoluted tubules of the rats received no-uric (fig. 31) and pure allopurinol (fig. 32) show vacuolated cytoplasm, cytoplasmic dense bodies, bizarre shape mitochondria, secondary lysosomes, partial loss of the apical microvilli and decrease basal infolding. The nucleus is shrunken and the nuclear membrane is irregular comparing with the control animals (fig. 29). The electron microscopic picture of the proximal convoluted tubules of the rats received the sustained release microcapsular preparation (fig. 30) is more or less similar to the control group.

The electron microscopic picture of the distal convoluted tubules of the rats received no-uric (fig. 35) and pure allopurinol (fig. 36) show vacuolated cytoplasm, less cytoplasmic organelles, cytoplasmic dense bodies, degenerated mitochondria and decrease basal infolding. The nucleus is shrunken and the nuclear membrane is irregular comparing to the control animals (fig. 33). The electron microscopic picture of the distal convoluted tubules of the rats received the sustained release microcapsular preparation (fig. 34) is more or less similar to the control group.

**Table (1):-** The mean values of the glomerular diameter, glomerular space and tubular epithelial height (of the proximal convoluted tubules) of the control group compared with that of the sustained release microcapsule group, no-uric group and pure allopurinol group.

	Control (C)	Micro-capsule (M)	No-uric (N)	Pure-drug (P)	CvM	CvN	CvP
Glomerular Diameter	50.7 $\mu$ ± 1.9	49.5 $\mu$ ± 1.8	46.0 $\mu$ ± 2.1	45.6 $\mu$ ± 2.8	0.1 <sup>ns</sup>	0.001 <sup>**</sup>	0.004 <sup>**</sup>
Glomerular space	11.1 $\mu$ ± 1.6	11.7 $\mu$ ± 1.2	12.5 $\mu$ ± 1.3	12.5 $\mu$ ± 1.3	0.09 <sup>ns</sup>	0.03 <sup>*</sup>	0.04 <sup>*</sup>
Epithelial height	11.7 $\mu$ ± 1.2	11.49 $\mu$ ± 1.0	10.1 $\mu$ ± 0.9	10.1 $\mu$ ± 1.4	0.6 <sup>ns</sup>	0.01 <sup>*</sup>	0.03 <sup>*</sup>

### Liver Results

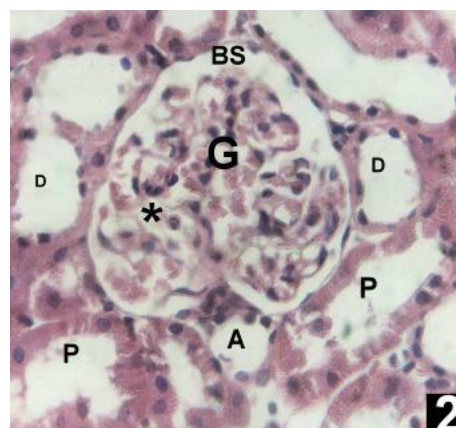
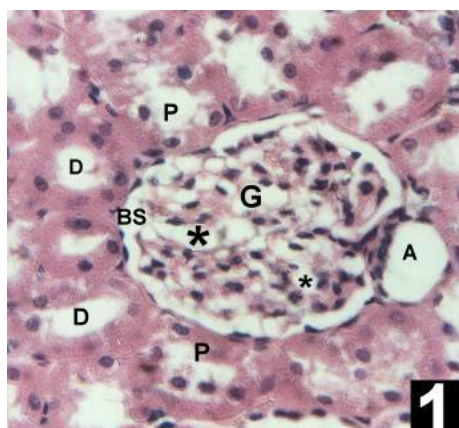
In the control group the liver cords arranged in rays around the central vein. The central vein is lined by healthy flattened endothelial cell and is surrounded by healthy liver cell cords (figs. 17&21).

The histological picture of the rats received sustained release microcapsules preparation is more or less similar to the control group both by Haematoxylin and Eosin stain (fig. 18) and by Van Gisson stain (fig. 22).

The histological picture of the rats received no-uric and pure allopurinol show areas of hemorrhage between the cords near to the central vein. The central veins are dilated, liver cords are of disturbed

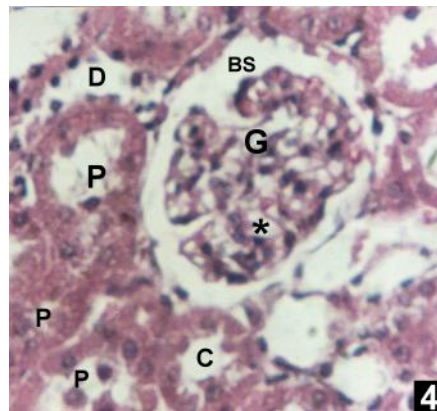
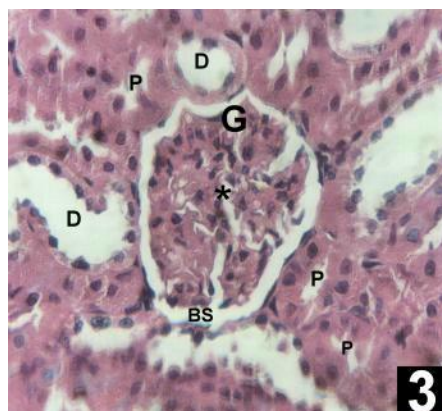
pattern. The hepatocytes are vacuolated with necrotic changes (figs. 19, 20, 23&24).

The electron microscopic picture of the hepatocytes of the rats received no-uric (fig. 39) and pure allopurinol (fig.40) show marked reduction of the cytoplasmic organelles, destructive mitochondria and little amount of the endoplasmic reticulum. The nucleus is shrunken, little chromatin material and the nuclear membrane is irregular comparing to the control animals (fig. 37). The electron microscopic picture of the hepatocytes of the rats received the microcapsular preparation (fig. 38) is more or less similar to the control group.



**Fig. (1)** shows: glomerulus (G), proximal convoluted tubules (P), distal convoluted tubules (D), glomerular capillaries (\*), glomerular space (BS) and afferent arteriole (A) of control albino rat kidney. (Hx&E X 400)

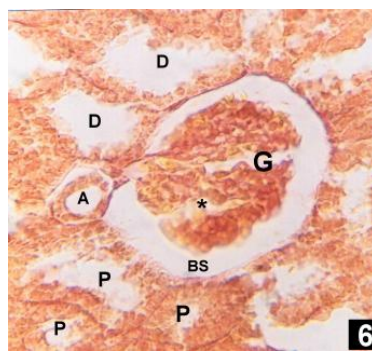
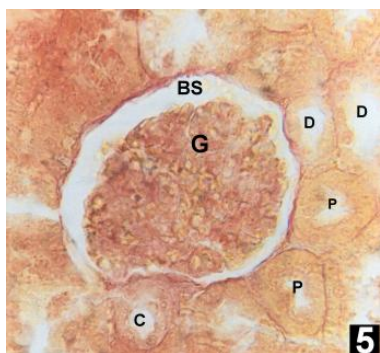
**Fig. (2)** shows: glomerulus (G), proximal convoluted tubules (P), distal convoluted tubules (D), glomerular capillaries (\*), afferent arteriole (A) and glomerular space (BS) of albino rat kidney receiving sustained release microcapsules preparation of allopurinol. (Hx&E X 400)



**Fig. (3)** shows: glomerulus (G), proximal convoluted tubules (P), distal convoluted tubules (D), glomerular capillaries (\*), glomerular space (BS) of albino rat kidney receiving no-uric preparation. (Hx&E X 400)

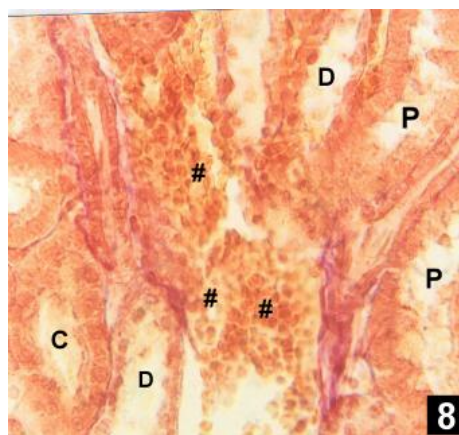
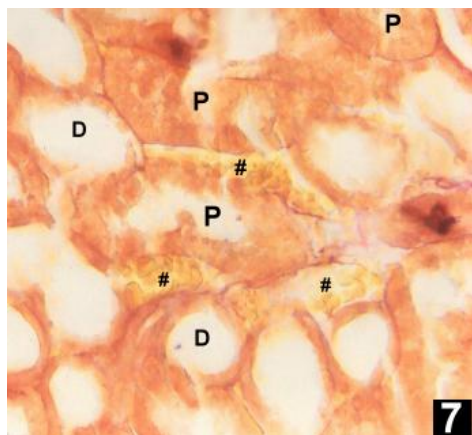
**Fig. (4)** shows: glomerulus (G), proximal convoluted tubules (P), distal convoluted tubules (D) and glomerular space (BS) of albino rat kidney receiving pure allopurinol preparation. The glomerular capillaries (\*) are lined by more compact cells relative to the control with deeply-stained nuclei and cytoplasm. (Hx&E X 400)





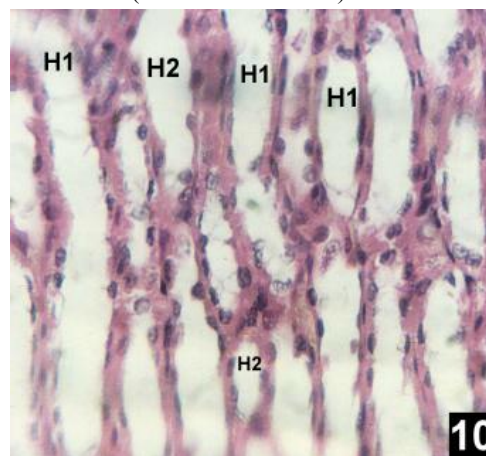
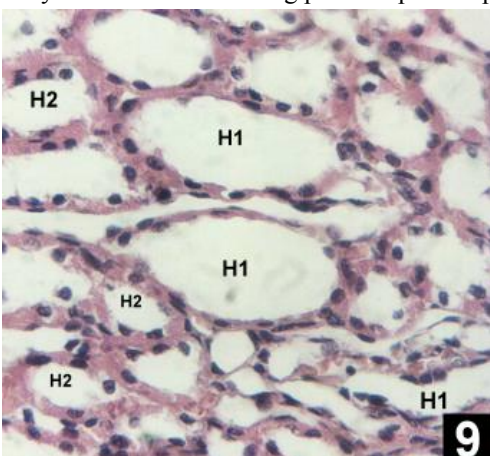
**Fig. (5)** shows: glomerulus (G), the proximal convoluted tubules (P), distal convoluted tubules (D), collecting tubules (C) and glomerular space (BS) of control albino rat. (Van Gisson X 400)

**Fig. (6)** shows: glomerulus (G), proximal convoluted tubules (P), distal convoluted tubules (D), glomerular capillaries (\*), glomerular space (BS), afferent arteriole (A) of albino rat kidney receiving sustained release microcapsule preparation. (Van Gisson X 400)



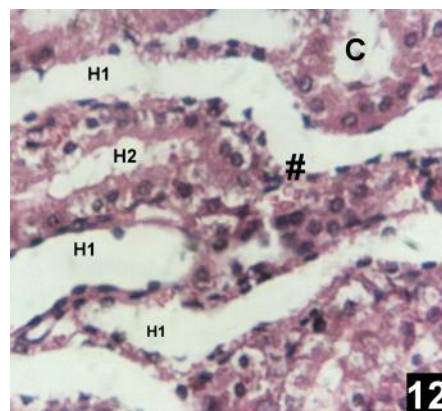
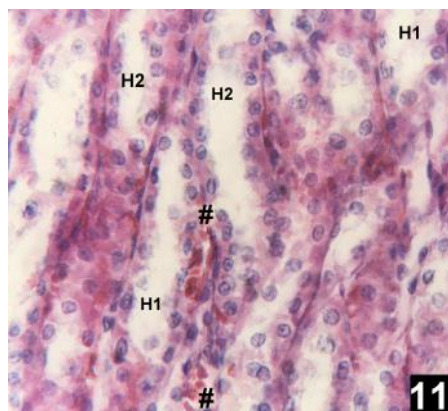
**Fig. (7)** shows: areas of hemorrhage (#) in between the proximal (P) and distal (D) convoluted tubules of albino rat kidney receiving no-uric preparation. (Van Gisson X 400)

**Fig. (8)** shows: the areas of hemorrhage (#) in between the proximal (P) and distal (D) convoluted tubules of the kidney of albino rat receiving pure allopurinol preparation. (Van Gisson X 400)



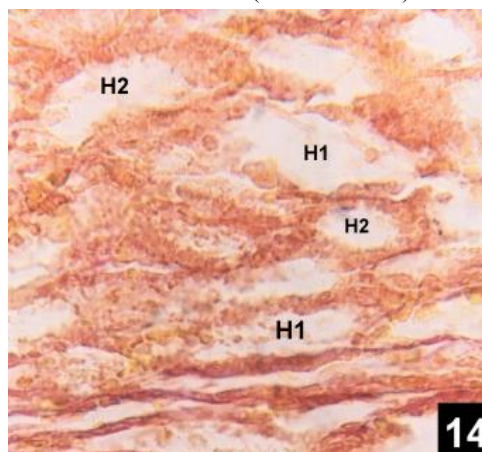
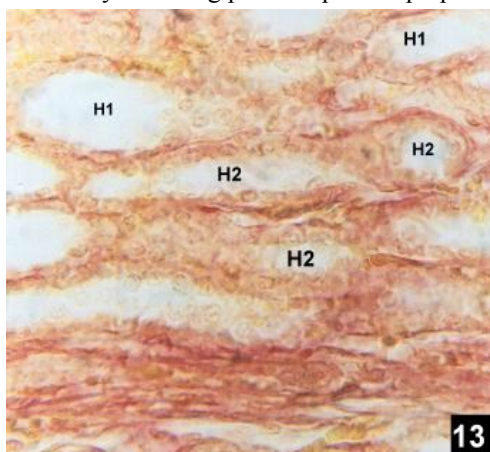
**Fig. (9)** shows: ascending loop of Henle (H1) lined by squamous epithelium and descending loop (H2) lined by columnar epithelium of control albino rat kidney. (Hx&E X 400)

**Fig. (10)** shows: the ascending loop of Henle (H1) and the descending loop (H2) of albino rat kidney receiving sustained release microcapsule preparation. (Hx&E X 400)



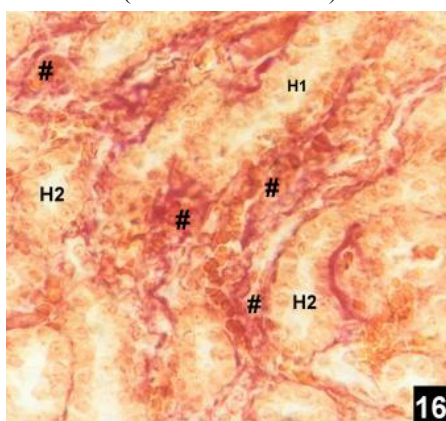
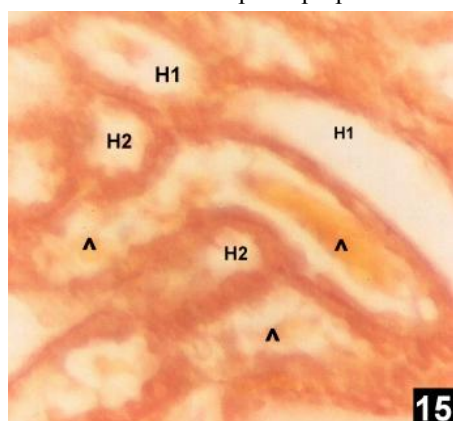
**Fig. (11)** shows: ascending loop of Henle (H1), descending loop (H2) and areas of hemorrhage (#) in between of albino rat kidney receiving no-uric preparation. (Hx&E X 400)

**Fig. (12)** shows: the ascending loop of Henle (H1), the descending loop (H2) and areas of hemorrhage (#) in albino rat kidney receiving pure allopurinol preparation. (Hx&E X 400)



**Fig. (13)** shows the ascending loop of Henle (H1) and the descending loop (H2) of control albino rat kidney. (Van Gisson X 400)

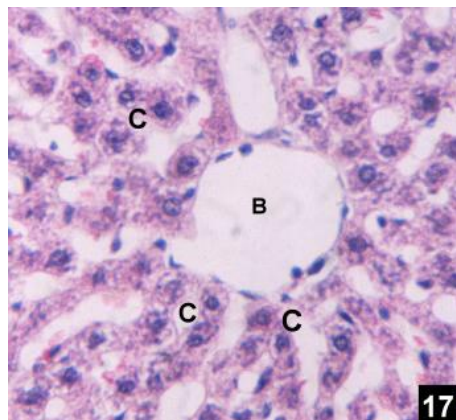
**Fig. (14)** shows: the ascending loop of Henle (H1) and the descending loop (H2) of albino rat kidney receiving sustained release microcapsule preparation. (Van Gisson X 400)



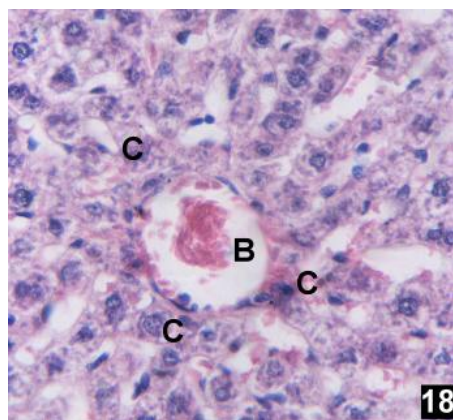
**Fig. (15)** shows: collections (^) inside the ascending (H1) and the descending loop (H2) of albino rat kidney receiving no-uric preparation. (Van Gisson X 400)

**Fig. (16)** shows: areas of hemorrhage (#) in between the ascending loop of Henle (H1) and the descending loop (H2) of albino rat kidney receiving pure allopurinol preparation. (Van Gisson X 400)

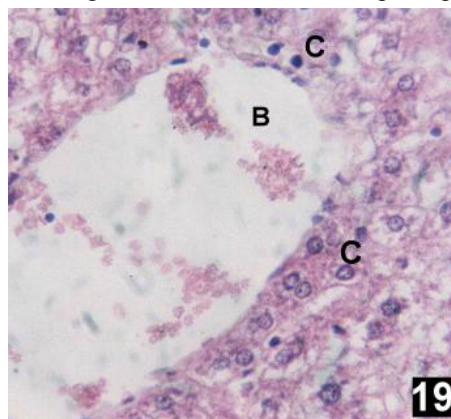




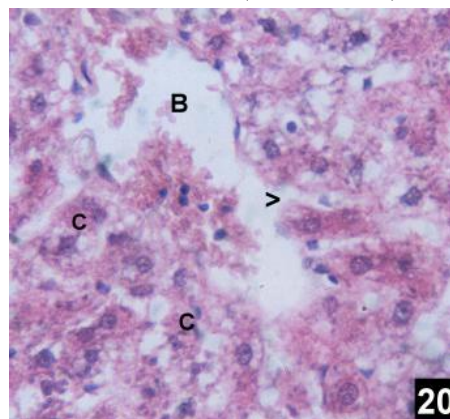
**Fig. (17)** shows: central vein (B) surrounded by liver cell cords (C) in part of hepatic lobule of control albino rat liver. (Hx&E X 400)



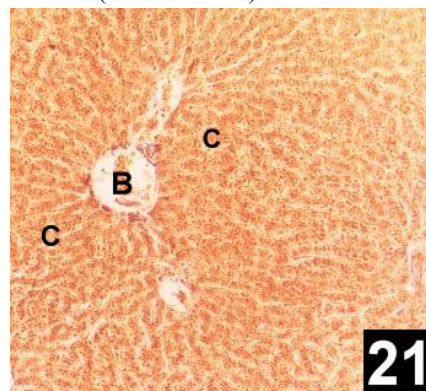
**Fig. (18)** shows: central vein (B) surrounded by healthy liver cell cords (C) in part of hepatic lobule of albino rat liver receiving sustained release microcapsule preparation. (Hx&E X 400)



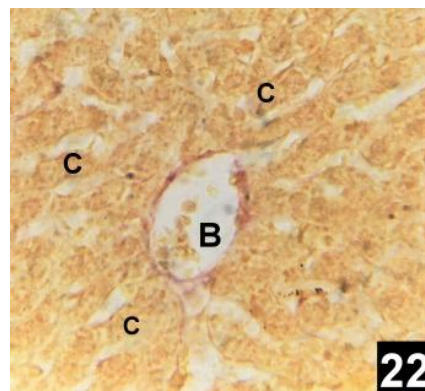
**Fig. (19)** shows: dilated central vein (B) lined by interrupted endothelium, areas of hemorrhage between the disrupted liver cell cords (C) in part of hepatic lobule of albino rat liver receiving no-uric preparation. (Hx&E X 400)



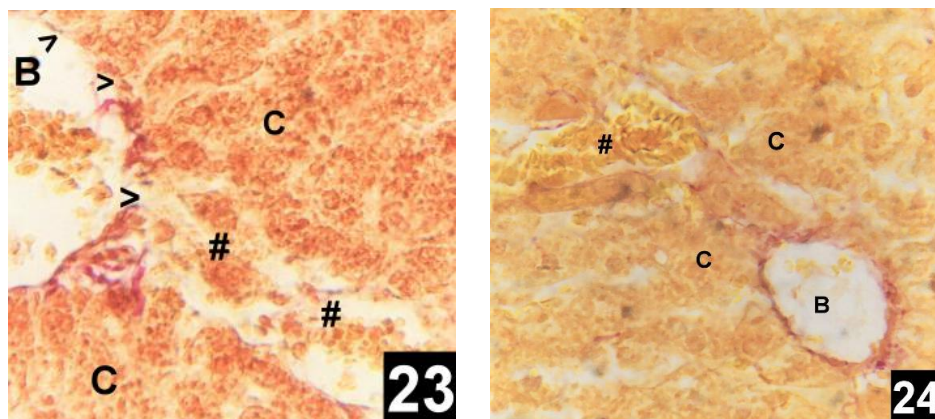
**Fig. (20)** shows: areas of hemorrhage between the disrupted liver cell cords (C) and dilated central vein (B) lined by interrupted endothelium (>) in part of hepatic lobule of albino rat liver receiving pure allopurinol preparation. (Hx&E X 400)



**Fig. (21)** shows: central vein (B) surrounded by healthy liver cell cords (C) in part of hepatic lobule of control albino rat liver. (Van Gieson X 100)

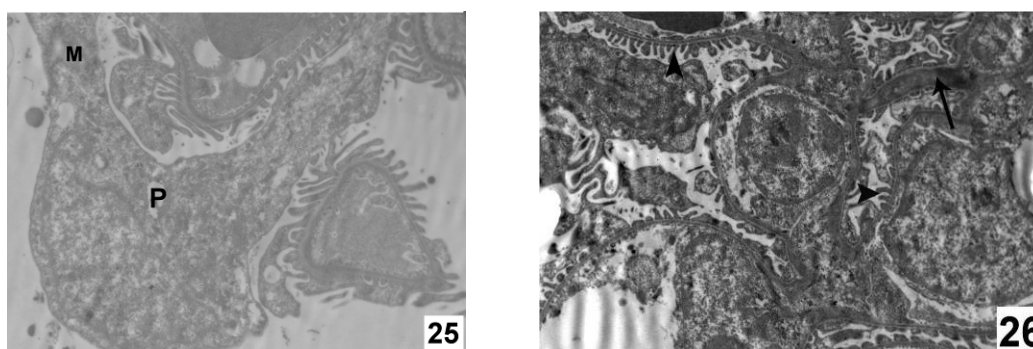


**Fig. (22)** shows: central vein (B) surrounded by healthy liver cell cords (C) in part of hepatic lobule of albino rat liver receiving sustained release microcapsule preparation. (Van Gieson X 400)



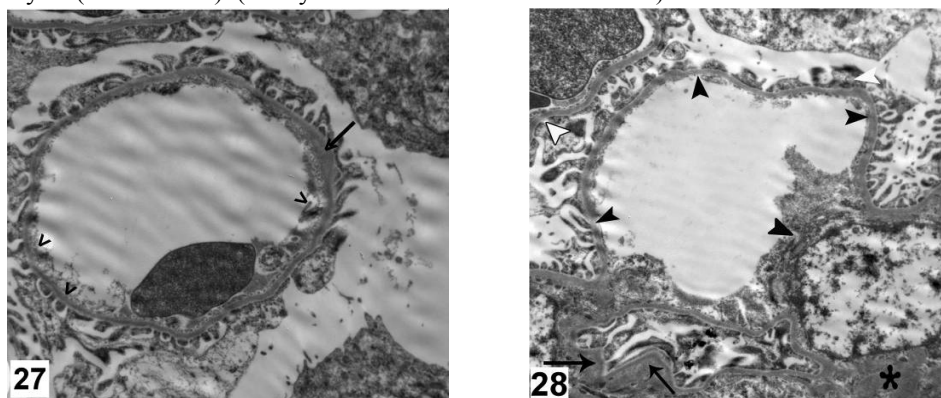
**Fig. (23)** shows: central vein (B), areas of hemorrhage (#) between the disrupted liver cell cords (C) in part of hepatic lobule of albino rat liver receiving no-uric preparation. (Van Gisson X 400)

**Fig. (24)** shows: central vein (B) with interrupted endothelium and disrupted cords (C) in part of hepatic lobule of albino rat liver receiving pure allopurinol preparation. (Van Gisson X 400).



**Fig. (25)**: an electron micrograph of the cell body of the podocyte (P) of the renal glomerular capillary and its major process (M) of control albino rat kidney. (Uranyl acetate and lead citrate X 5800)

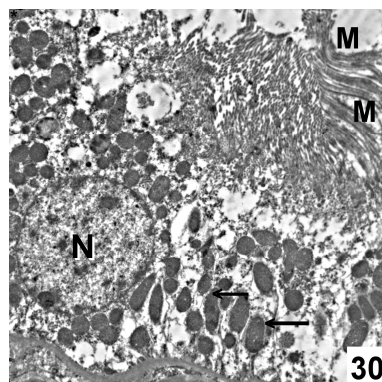
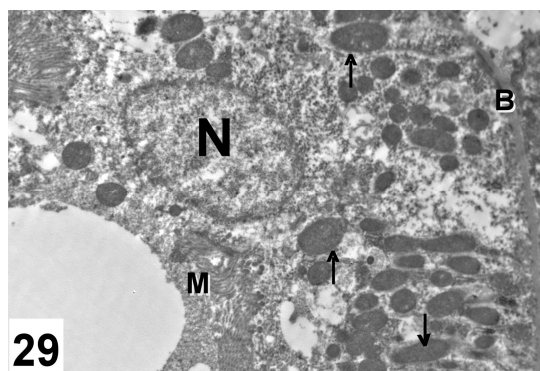
**Fig. (26)**:- An electron micrograph of the renal glomerular capillary of rat received microcapsular preparation showing an area of partial thickening of the basement membrane (arrow) and regular minor processes of podocytes (arrow heads). (Uranyl acetate and lead citrate X 4800)



**Fig. (27)**:- An electron micrograph of the renal glomerular capillary of rat received no-uric preparation showing partial thickening of the basement membrane (arrow) and disrupted capillary endothelium (>). (Uranyl acetate and lead citrate X 7200)

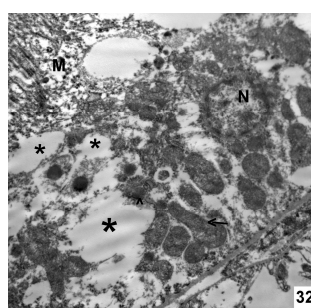
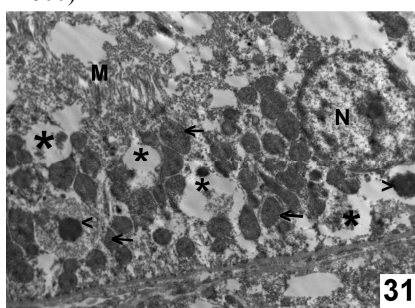
**Fig. (28)**:- An electron micrograph of the renal glomerular capillary of rat received pure allopurinol preparation showing partial thickening of the basement membrane (arrow), disrupted capillary endothelium (black arrow heads) and irregular minor processes of podocytes (white arrow heads). The asterisk (\*) points to an area of sclerosis. (Uranyl acetate and lead citrate X 7200)





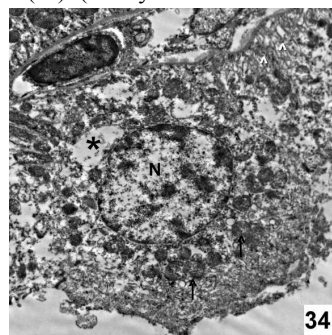
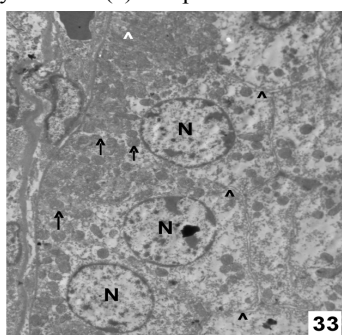
**Fig. (29):-** An electron micrograph of the proximal convoluted tubule cell of control albino rat kidney shows the open-face nucleus (N) with well defined nuclear membrane and basement membrane (B). The cytoplasm contains large number of normal mitochondria (arrow) and regular microvilli (M). (Uranyl acetate and lead citrate X 4800)

**Fig. (30):-** An electron micrograph of the proximal convoluted tubule cell of rat received microcapsular preparation showing rounded nucleus (N) with abundant nuclear sap and well defined nuclear membrane. The cytoplasm contains large number of elongated mitochondria (arrow) and regular apical microvilli (M). (Uranyl acetate and lead citrate X 4800)



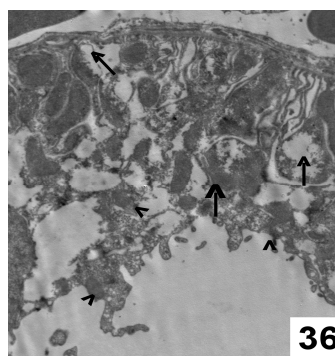
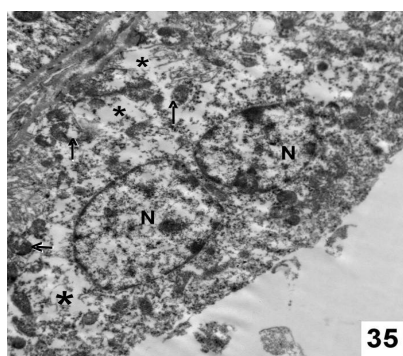
**Fig. (31):-** An electron micrograph of the proximal convoluted tubule cell of rat received no-uric preparation showing rounded nucleus (N) with abundant nuclear sap and well defined nuclear membrane. The cytoplasm contains large number of bizarre shaped mitochondria (arrow), wide cytoplasmic spaces (\*), electron dense bodies (<) and partial loss of apical microvilli (M). (Uranyl acetate and lead citrate X 4800)

**Fig. (32):-** An electron micrograph of the proximal convoluted tubule cell of rat received pure allopurinol preparation showing rounded small nucleus (N) with abundant nuclear sap and well defined nuclear membrane. The cytoplasm contains large number of bizarre shaped mitochondria (arrow), wide cytoplasmic spaces (\*), secondary lysosomes (^) and partial loss of apical microvilli (M). (Uranyl acetate and lead citrate X 7200)



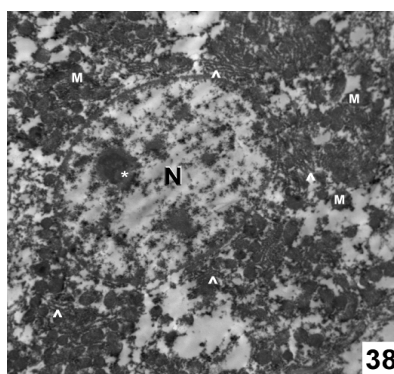
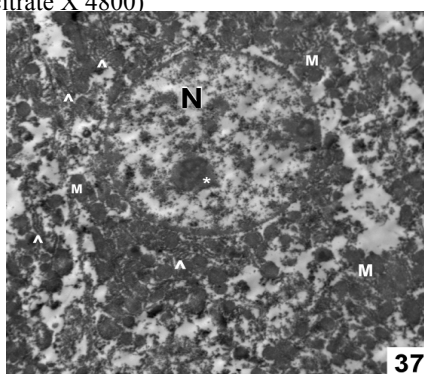
**Fig. (33):-** An electron micrograph of the cell lining of the distal convoluted tubule of control albino rat kidney shows rounded nucleus (N) with well defined nuclear membrane and abundant nuclear sap. The cell border is well defined (black arrow heads). The cytoplasm contains regular mitochondria (arrow) inside regular basal enfolding (white arrow heads). (Uranyl acetate and lead citrate X 2900)

**Fig. (34):-** An electron micrograph of the cell lining of the distal convoluted tubule of rat received microcapsular preparation showing rounded nucleus (N) with well defined nuclear membrane and abundant nuclear sap. The cytoplasm contains normal mitochondria (arrow) inside regular basal enfolding (white arrow heads) and cytoplasmic spaces (\*). (Uranyl acetate and lead citrate X 7200)



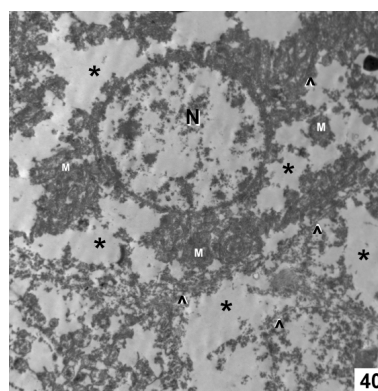
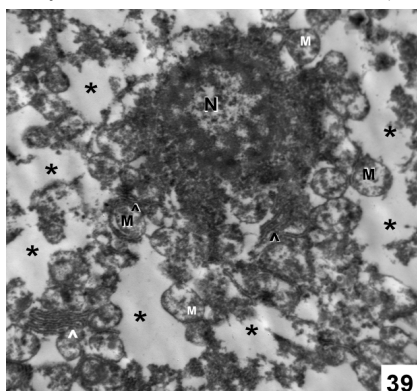
**Fig. (35):-** An electron micrograph of the distal convoluted tubule cell of rat received no-uric preparation showing nucleus (N) with abundant nuclear sap. The cytoplasm contains damaged mitochondria (arrow) and cytoplasmic spaces (\*). (Uranyl acetate and lead citrate X 7200)

**Fig. (36):-** An electron micrograph of the distal convoluted tubule cell of rat received pure allopurinol preparation showing swollen degenerated mitochondria (arrow) and luminal cytoplasmic debris (arrow heads). (Uranyl acetate and lead citrate X 4800)



**Fig. (37):-** An electron micrograph of hepatocyte of control albino rat liver. the nucleus (N) with prominent eccentric nucleolus (\*) and well defined nuclear membrane. The cytoplasm contains large number of normal mitochondria (M), free ribosomes and rough endoplasmic reticulum (^). (Uranyl acetate and lead citrate X 4800)

**Fig. (38):-** An electron micrograph of hepatocyte of albino rat liver receiving sustained release microcapsules preparation of allopurinol. The nucleus (N) with prominent eccentric nucleolus (\*) and well defined nuclear membrane. The cytoplasm contains large number of normal mitochondria (M), free ribosomes and rough endoplasmic reticulum (^). (Uranyl acetate and lead citrate X 4800)



**Fig. (39):-** An electron micrograph of hepatocyte of albino rat liver receiving no-uric preparation of allopurinol. the nucleus (N) is shrunken with clumping of the chromatin on the inner nuclear membrane. The cytoplasm contains little amount of degenerated mitochondria (M), wide cytoplasmic spaces (\*) and little rough endoplasmic reticulum (^). (Uranyl acetate and lead citrate X 10000)

**Fig. (40):-** An electron micrograph of hepatocyte of albino rat liver receiving pure allopurinol. the nucleus (N) is shrunken devoid of nucleolus. The cytoplasm contains little amount of degenerated mitochondria (M), little rough endoplasmic reticulum (^) and wide cytoplasmic spaces (\*). (Uranyl acetate and lead citrate X 4800)



#### 4. Discussion

The present study was conducted on adult male albino rats. Males have been chosen in this study to avoid the hormonal changes, which may be faced in females and may affect the results (Hamada, 1979; Messow *et al.*, 1980 and Yabuki *et al.*, 1999).

Liver and kidney have been chosen in this study because they are target organs for drug toxicity (Nakatani *et al.*, 2000 and Saraste & Pulkki, 2000).

The liver is a specialized organ in terms of its metabolic, synthetic and detoxifying function (Nakatani *et al.*, 2000 and Saraste & Pulkki, 2000). Liver and kidney are the primary target for a variety of noxious agents inducing inflammation, necrosis and fibrosis (Meki *et al.*, 2001; Yabuki *et al.*, 2003 and Ishibashi *et al.*, 2009).

Side effects of allopurinol in the present study are more pronounced in the kidney and liver of pure allopurinol treated rats and to a less extent in the kidney and liver of no-uric treated rats. The glomeruli of the rats received no-uric and pure allopurinol show significant reduction in their size on comparing to the control rats and also show significant dilatation of their glomerular space. More over significant reduction in epithelial thickness of proximal convoluted tubules with areas of hemorrhage in between them also recorded. George *et al.* 2006 showed that a steep dose-response relationship exists between allopurinol and its effects on endothelial dysfunction in patients with chronic heart failure. High-dose allopurinol will result in high plasma concentration of the drug and so more side effects. The slowly released microcapsular preparation maintain a suitable level of the drug for a long period of time so minimize the side effects (El-Gibaly and Abdel-Gaphar, 2005).

The liver in the present study showed areas of hemorrhage between the hepatic cords. These findings are in accordance with that reported by Tam and Carroll (1989), El-Gibaly and Abdel-Gaphar (2005) and Fagugli *et al.* (2008) and Lindh (2009). Tam and Carroll (1989) through autopsy reported fatal allopurinol hepatic toxicity in human in the form of central necrosis. Pereira *et al.* (1998) and El-Gibaly and Abdel-Gaphar (2005) reported that free allopurinol-treated rats showed marked hydropic degeneration of the hepatocytes at the periphery of the hepatic lobules. Besides, the hepatocytes in the center of the lobules underwent necrotic changes.

In this study allopurinol sustained release capsular formula shows the least significant side effects compared with the control group both on the kidney and liver. These findings are similar to that reported on the liver by El-Gibaly and Abdel-Gaphar (2005). They found that the liver of sustained release formula group was more or less normal.

As mentioned before the liver of microcapsule group is more or less normal. These findings considered by El-Gibaly and Abdel-Gaphar (2005) due to the modification in the dissolution rate of allopurinol and also control of the *in vivo* release by microcapsule preparation, so that prolonged absorption properties with a lower allopurinol concentration are maintained in blood over a long time. This may result in increasing the antigout efficiency of allopurinol and minimizing its dangerous effects on liver and other organs.

It is known that the pattern of release of active agent from microparticles depends on the particle size of the core material (Gence *et al.*, 1998). Higher burst release and release rate constants from this preparation were thus expected due to larger surface area and the decreased diffusion path length and wall thickness of the preparation (El-Gibaly and Abdel-Gaphar, 2005). The spherical matrix model for a heterogenous matrix can best be used to describe the overall release pattern of a dissolved drug from a spherical microcapsule form (Lewis *et al.*, 1998).

#### Acknowledgment:

I thank professor El-Gibaly, Department of Pharmaceutics, College of Pharmacy, Assiut University, for supporting me with the novel SR dosage form formulation and discussing the SR formulation of the drug.

#### Corresponding Author:

**Ashraf H. Abd-Elhakem**

Anatomy Department, Assiut University, Faculty of Medicine, Assiut-Egypt

#### 5. References

- Adeyeye CM and Price JC (1994):** Development and evaluation of sustained release ibuprofen-wax microspheres. I. Effect of formulation variables on physical characteristics. *Pharm. Res.* 8: 1377-1383.
- Aldaba-Muruato LR, Moreno MG, Shibayama M, Tsutsumi V and Muriel P(2012):** Protective effects of allopurinol against acute liver damage and cirrhosis induced by carbon tetrachloride: Modulation of NF- $\kappa$ B, cytokine production and oxidative stress. *Biochimica et Biophysica Acta* 1820: 65–75
- Arabi R, Hashemi SA and Fooladi M (1996):** Microcapsulation of allopurinol by solvent evaporation and controlled release investigation of drugs. *J. Microencapsul.* 13: 527-535.
- Arshady R (1989):** Microspheres and microcapsules: a survey of manufacturing techniques. Part 1: suspension crosslinking. *Polym. Eng. Sci.* 29: 1746-1758.

- Bancroft JD and Stevens A (1982):** Theory and practice of histologic technique, 2<sup>nd</sup> ed. Churchill Livingstone, UK.
- Biagioni E, Busani S, Rinaldi L, Marietta M, Girardis M (2012):** Acute renal failure and liver necrosis associated to allopurinol therapy. *Anaesth Intensive Care*. Jan;40(1):190-1.
- Bodmeier R, Wang J and Bhagwatwar H (1992):** Process and formulation variables in the preparation of wax microparticles by a melt dispersion technique. I. Oil-in-water technique for water-insoluble drugs. *J. Microcapsul*. 9: 89-98.
- Dawson J, Quinn T, Harrow C, Lees KR, Weir CJ, Cleland SJ and Walters MR (2009):** Allopurinol and nitric oxide activity in the cerebral circulation of those with diabetes: a randomized trial, *Diabetes Care*, 32: 135-137.
- Deasy PB (1984):** Microcapsulation and related drug processes. Marcel and Dekker, New York.
- Drury RAB and Willington EA (1980):** "Carleton's Histological Technique". 5<sup>th</sup> ed., Oxford University, Press New York Toronto.
- El-Gibaly I, (1998):** Microcapsulation of allopurinol using a fully improved non-solvent addition technique a novel binary blend based on polyvinyl chloride: factorial design application. *Pharm. Sci., Assiut Univ.*, 21: 203-228.
- El-Gibaly I, Meki AMA and Abdel-Ghaffar SK (2003):** Novel B melatonin-loaded chitosan microcapsulation: in vitro characterization and antiapoptosis efficacy for aflatoxin B1-induced apoptosis in rat liver. *Int. J. Pharm*. 260: 5-22.
- El-Gibaly I and Abdel-Ghaffar SK (2005):** Effect of hexacosanol on the characteristics novel sustained released allopurinol solid lipospheres (SLS): factorial design application and product evaluation. *Int. J. Pharm*. 294: 33-51.
- Fagugli RM, Gentile G, Ferrara G and Brugnano R (2008):** Acute renal and hepatic failure associated with allopurinol treatment. *Clin Nephrol.*;70(6):523-6.
- Gence L, Demirel MGuler E and Hegazy N (1998):** Microcapsulation of ketorolac tromethamine by means of a coacervation-phase separation technique induced by the addition of non-solvent. *J. Microcapsul*. 15: 45-53.
- George J, Carr E, Davies J, Belch JJ and Struthers A (2006):** High dose allopurinol improves endothelial function by profoundly reducing vascular oxidative stress and not by lowering uric acid. *Circulation*;114:2508-16.
- Glantzounis GK, Tsimoyiannis EC, Kappas AM and Galaris DA (2005):** Uric acid and oxidative stress. *Curr Pharm Des*;11:4145-51.
- Giannola LI, De Caro V and Rizzo MV (1995):** Preparation of white beeswax microspheres loaded with valproic acid and kinetic study of drug release. *Drug Dev. Ind. Pharm*. 21: 793-807.
- Griffith L. D.; Bulger R. E. and Trump B. F. (1973):** Light and Electron Microscopic studies of rat kidney. *Springer link Beta*, 13:321-340.
- Hamada, Y (1979):** Sex difference and fine structure on the epithelium cells of Glomerular capsule in mice. *Exp. Anim. (Tokyo)* 28: 485-490.
- Horiuchi H, Ota M, Nishimura S, Kaneko H, Kasahara Y, Ohta T and Komoriya K (2000):** allopurinol induces renal toxicity by impairing pyrimidine metabolism in mice. *Life Sciences*, 66, (21): 2051-2070
- Ishibashi H, Nakamura M, Komori A, Migita K, Shimoda S (2009):** Liver architecture, cell function, and disease, *Semin. Immunopathol*. 31: 399-409.
- Krishnan E, Pandya BJ, Chung L and Dabbous O (2011):** Hyperuricemia and the risk for subclinical coronary atherosclerosis-data from a prospective observational cohort study. *Arthritis Res Ther.*;13:R66.
- Lewis L, Boni R and Adeyeye CM (1998):** Effect of emulsifier blend on the characteristics of sustained release diclofenac microspheres. *J. Microcapsul*. 15: 283-298.
- Lindh J (2009):** Hepatic adverse effects of allopurinol. *Lakartidningen.*;106(38):2374-5.
- Lippi G, Montagnana M, Franchini M, Favaloro EJ and Targher G (2008):** The paradoxical relationship between serum uric acid and cardiovascular disease. *Clin Chim Acta*;392:1-7.
- Liu PG, He SQ, Zhang YH and Wu J (2008):** Protective effects of apocynin and allopurinol on ischemia/reperfusion-induced liver injury in mice. *World J Gastroenterol.*; 14(18): 2832-2837.
- Martindale (1999):** In Parfitt, K (Ed), *The Complete Drug Reference*, 32<sup>nd</sup> ed. The Pharmaceutical Press, London, pp. 390-392: 114-1377.
- Meki AMA, Abdel-Ghaffar SK and Elgibaly I (2001):** Aflatoxin B1 induces Apoptosis in rat liver: Protective effect of melatonin. *Neuroendocrinology Letters*; 22: 417-426.
- Messow C, Gartner K, Hackbarth H, Kangaloo M and Lunebrink L (1980):** Sex differences in kidney morphology and glomerular filtration rate in mice. *Contr. Nephrol*. 19: 51-55.
- Nakatani T, Tawaramato M, Kennedy DO, Kojima A and Mastui-Yuasa I (2000):** Apoptosis induced by chelation of intracellular zinc is associated with depletion of cellular glutathione level in rat hepatocytes. *Chem. Bio. Interact.*: 125 151-163.
- Neogi T, Terkeltaub R, Ellison RC, Hunt S and Zhang Y (2011):** Serum urate is not associated



- with coronary artery calcification: the NHLBI Family Heart Study. *J Rheumatol*; 38:111-7.
- Pereira S, Almeida J, Silva AO, Quintas M, Candeias O, Freitas F (1998):** Fatal liver necrosis due to allopurinol. *Acta Med Port.*;11(12):1141-4.
- Puddu P, Puddu GM, Cravero E, Vizioli L and Muscari A (2012):** The relationships among hyperuricemia, endothelial dysfunction, and cardiovascular diseases: Molecular mechanisms and clinical implications. *Journal of Cardiology*, 59: 235-242
- Saraste A and Pulkki K (2000):** Morphologic and biochemical hallmark of apoptosis. *Cardvascul. Res.*, 45: 528-537.
- Spiegl P and Abd-El-Fatah S (1977):** Prolonged release microcapsules of allopurinol. *Sci. Pharm.*, 45: 185-190.
- Stocker R and Keaney Jr JF (2004):** Role of oxidative modifications in atherosclerosis. *Physiol Rev.*;84:1381-478.
- Tam S and Carroll W (1989):** Allopurinol hepatotoxicity. *Am. J. Med.* 86: 357-358.
- Tausche AK, Aringer M, Schroeder HE, Bornstein SR, Wunderlich C and Wozel G (2008):** The Janus faces of allopurinol-allopurinol hypersensitivity syndrome. *Am J Med.* Mar;121(3):e3-4.
- Teo WL, Pang SM and Koh HY (2011):** Allopurinol hypersensitivity syndrome with acute generalized exanthematous pustulosis manifestations. *Cutan Ocul Toxicol.*;30(3):243-4.
- Uddin Ms Hawlader MNA and Zhu HJ (2001):** Microcapsulation of ascorbic acid: effect of process variables on product characteristics. *J. Microcapsul.* 18, 199-209.
- Viazzi F, Leoncini G, Ratto E and Pontremoli R (2006):** Serum uric acid as a risk factor for cardiovascular and renal disease: an old controversy revived. *J Clin Hypertens (Greenwich)*;8:510-8.
- Vilivalam VD and Adeyeye CM (1994):** Development and evaluation of controlled-release diclofenac microsphere and tabletted microspheres. *J. Microencapsul.* 11, 455-470.
- Woo-Yong Lee, Eun-Ji Koh and Sun-Mee Lee (2012):** A combination of ischemic preconditioning and allopurinol protects against ischemic injury through a nitric oxide-dependent mechanism *Nitric Oxide*, 26 : 1–8.
- Yabuki A, Suzuki S, Matsumoto M and Nishinakagawa H (1999):** Morphological analysis of sex and strain differences in the mouse nephron. *J. Vet. Med. Sci.* 61 (8): 891-896.
- Yabuki A, Matsumoto M, Nishinakagawa H and Suzuki S (2003):** Age-related morphological changes in kidneys of SPF C57BL/6Cr mice maintained under controlled conditions. *J. Vet. Med. Sci.* 65 (8): 845-851.