

Effect of Testosterone on Hind Limb Regeneration in Tadpoles of the Egyptian Toad, *Bufo Regularis* Reuss

Hamida Hamdi¹, Abdel-Wahab EL-Ghareeb¹, Alaa Shamakh¹ and Sakina Saeed²

¹Department of Zoology, Faculty of Science, Cairo University, Egypt

²Department of Zoology, Faculty of Science, ELMargab University, Libya

Hamdihamida@rocketmail.com

Abstract: The present study investigated the role of Testosterone on the regenerative capacity in two metamorphic stages of the tadpoles of the Egyptian toad, *Bufo regularis* Reuss, after amputation of the hind limb at the mid-shank level. It indicated an enhancing effect of Testosterone treatment on limb regeneration in the prometamorphic (stage 56), where 90% of the cases regenerated toes ranging from five to one compared with 77.3% in the control group, also the differential effect of testosterone on the number of toes was obvious in the treated animals, where 30% and 35% of the cases regenerated five and four toes respectively compared with 27.3% and 31.8% in the control group. In the metamorphic stage (stage58), the effect of testosterone was also obvious, where 38.6% of the treated cases restored toes compared with 13.3% of the cases in the control group. 45.5% of the treated cases restored part of the foot compared with 20 % of the cases in the control group. Histological observations of the treated limbs revealed that the formation of thick epithelial covering and complete skin is faster than that of the control animals. This may indicate that the enhancing effect of testosterone on limb regeneration, this may be due to the acceleration of wound healing either by its action upon the proliferative phase of healing which involves immune processes such as reepithelialization and angiogenesis or by the production of IGF-1 or by its stimulatory effect through Wnt/ β -catenin signaling resulting in the initiation of the early phases of limb regeneration.

[Hamida Hamdi, Abdel-Wahab EL-Ghareeb, Alaa Shamakh and Sakina Saeed **Effect of Testosterone on Hind Limb Regeneration in Tadpoles of the Egyptian Toad, *Bufo Regularis* Reuss**] Life Science Journal, 2011; 8(4): 269-283] (ISSN: 1097-8135). <http://www.lifesciencesite.com>.

Key Words: Limb regeneration, Amphibia, Testosterone.

List of Abbreviations:

As Astragalus BL Blastema C Cartilaginous collar CD Cellular debris CF Cartilage or procartilage formation CP Cartilaginous cap E Epiphysis FC Fibrocytes or fibrocellular accumulation M Muscle fibres or Muscle Group MG Multicellular glands ML Melanophores MS Mesenchymal cells PH Phalanges SC Scar of fibrocellular tissue TF Tibio-fibula WE Wound epithelium

Introduction

Limb regeneration is one of the best examples of organ/appendage regeneration in vertebrates and has been called 'epimorphosis' since it requires blastema formation and proliferation (Brookes, 1997; Suzuki *et al.*, 2006) though there has been criticism of the classical definition of epimorphosis and morphallaxis (Agata *et al.*, 2007). Among tetrapods, the cellular and molecular mechanisms involved in limb development are highly conserved, where fully developed limbs share a common skeletal pattern (Muneoka and Sassoon, 1992). On the other hand, the regenerative responses of limbs after amputation differ from animal to animal among tetrapods. Birds cannot regenerate limbs at any stage of development and, surprisingly, mammals have slightly better limb regenerative capacity than that of birds. Embryonic and neonatal mice can regenerate their digit tips if they are amputated through the distal phalanx (Borgens 1982; Reginelli *et al.*, 1995), and similar digit tip regeneration occurs in humans (Douglas, 1972; Illingworth, 1974). After amputation at a more proximal level, a neonatal mouse cannot regenerate

lost parts, and hypertrophy of amputated bones occurs (Masaki and Ide, 2007). In contrast, amphibians have exceptionally high regenerative capacity for limb regeneration. Urodele amphibians such as newts and salamanders can regenerate their limbs following amputation any time during their life cycles, although there is a non-regenerative mutant in axolotls (Sato and Chernoff, 2007). Anuran amphibians such as *Xenopus* are intermediate between urodele amphibians and other vertebrates in terms of their regenerative capacity, in that they can completely regenerate developing hind limb buds prior to the onset of metamorphosis, but regenerative capacity declines gradually as metamorphosis proceeds (Dent, 1962; Muneoka *et al.*, 1986; Suzuki *et al.*, 2006).

Many investigations have dealt with the factors affecting either retardation or enhancement of the regenerative capacity among urodeles and anurans, by using several experimental means such as mechanical, electrical, chemical, and hormonal means.

Hormones as well as hormone-like growth factors are well known to promote cellular

differentiation and regeneration (Leon *et al.*, 1998; De luca *et al.*, 1999).

Dyson and Joseph (1968) concluded that the treatment of rabbit females with testosterone stimulates their regenerative growth in the ear.

Beran *et al.* (1982) concluded that testosterone and some of the synthetic analogs tested exert their hemopoietic effect, at least partly, by affecting the maintenance of erythroid and granulocytic stem cells, directly by increasing their survival or proliferation or indirectly by increasing the input from multipotent stem cell pool, or by both mechanisms.

Kinderman and Jones (1993) proved that testosterone propionate administration during facial nerve injury results in an increase in ribosomal levels in hamster facial motoneuron system (FMN).

Bardin, 1996; Katznelson *et al.*, 1996; Bhasin *et al.*, 1997&2000; Swerdloff and Wang, 2003 stated that treatment with testosterone improves muscle mass and strength, bone density, and reduces visceral fat in a variety of subjects.

Brown *et al.* (2001) suggested that testosterone enhances the rate of regeneration by increasing the neuronal cytoskeletal response after axonal injury. And suggested a common mechanism for gonadal steroid action on regenerating motoneurons across species.

Ustünel *et al.* (2003) determined that testosterone can induce protein synthesis in gastrocnemius muscle fibres, and induces changes in shape and size, and also can change the appearance and the number of fibres.

Sinha-Hikim *et al.* (2003) Concluded that testosterone -induced muscle fiber hypertrophy is associated with an increase in satellite cell number, a proportionate increase in myonuclear number, and changes in satellite cell ultrastructure.

Prokai-Tatrai *et al.* (2007) stated that testosterone can activate synthesis of bcl-2 protein, which prevents cell apoptosis in the injured regions.

Cayan *et al.* (2008) showed that testosterone has a significant role to increase bladder smooth muscle, leading to improvement in bladder functions in postmenopausal women with urogenital system dysfunction.

Little *et al.* (2009) suggested that testosterone has neuroprotective effects on morphology and function in both highly androgen-sensitive as well as more typical motoneuron populations, further supporting a role for testosterone as a neurotherapeutic agent in the injured nervous system.

Wilson *et al.* (2009) suggested that Testosterone has neuroprotective effects on morphology in both males and females.

Fu *et al.* (2011) suggested that testosterone promotes cell proliferation and differentiation via G protein-coupled receptors and different downstream pathways in the L6 cell line, although the related

molecular mechanisms need to be elucidated in future studies.

The present study was deemed necessary in view of elucidating further the effect of testosterone on hind-limb regeneration in a prometamorphic stage (stage 56) and a metamorphic stage (stage 58) of the Egyptian toad, *Bufo regularis* Reuss after amputation at the mid-shank level.

2 Material and Methods:

Early tadpoles of *Bufo regularis* Reuss were collected from the ponds of Abou Rawash, Giza Governorate, Egypt. The tadpoles were reared in glass aquaria (60 x 30 x 30cm) in the laboratory at room temperature $27^{\circ}\text{C} \pm 2^{\circ}\text{C}$, in Department of Zoology, Faculty of Science, Cairo University.

Two stages were selected for this study. Staging of the individuals before the operation was carried out according to the normal table of Sedra and Michael (1961). The selected stages were numbered 56 and 58. The most distinctive external criteria of these stages are as follows:

Stage 56 (A prometamorphic stage)

Age 28 days, length 25mm and tail is 14.5 mm long. Hind limb is about 1.9 mm in Length. Landmarks between thigh, shank and foot are more distinct. Melanophores are scattered on all toes and are especially dense on the last three toes.

Stage 58 (A metamorphic stage)

Age 39 days, length 30 mm and tail is 17 mm long. Elbow of right fore-limb is piercing or has already pierced the overlying skin. The left fore-limb has passed out through the wide, spout-like opening of the branchial chamber; thus this limb is now completely exposed. About 4-5 tubercles on the palm are prominent. The fourth toe is the longest. Web clearly developed between 2-3 and 3-4 toes.

Tadpoles of each stage were randomly divided into two groups: a control group and a treated one. Chlorotone (Sigma) was used as an anaesthetic medium in tap water with the concentration 1:2000. Each operated case was then transferred to a Petri dish containing half concentration of the anaesthetic medium, then shortly to another Petri dish containing tap water in which the operated case recovered and became motile within few minutes.

For each group, amputation was carried out on the left hind-limb at the level of the mid-shank (Fig. 1). The right limb was kept intact. Amputation was carried out by using iridectomy scissors and fine watch-maker's forceps. Experimental tadpoles were injected intraperitoneally after amputation with Testosterone propionate (Testone-E, Misr Co. for Pharm Ind., Cairo, Egypt) at a single dose of $5\mu\text{l}$ / individual.

To clarify the early post-operative histological changes within the stump tissues, individuals were

selected and fixed at regular intervals, in a time series of 1, 3, 5, 7, 10 and 15 post-operative days, while the remaining tadpoles were left to reach two weeks after complete metamorphosis. A total of 250 cases were operated. Out of these, 80 cases were serially sectioned and studied microscopically.

The amputated limbs were then dehydrated through ascending grades of alcohol, cleared in cedar wood oil and finally embedded in parablax. Limbs were serially sectioned longitudinally at a thickness of 7 microns. The sections were stained with haematoxylin and eosin for general histological structures. A total of 160 cases (metamorphosed toadlets) were fixed, and morphologically examined.

To investigate the pattern of skeletal elements, transparencies of the operated limbs by using Victoria blue stain (Bryant and Iten, 1974) and Alizarin Red S stain (Sedra, 1950) were made.

Photomicrographs of representative sections and limbs of both control and treated animals were prepared at a known magnification.

3 Results

STAGE 56 Group: 1/56 (Control group) A) Histogenesis of time-series•

By the first post-amputation day, the wound surface was covered with two or three layers of epithelial cells. Epithelial covering was thicker at the most distal tip of the regenerate. Nuclei of the epithelial cells were large and rounded. The basement membrane was indistinct. The activity of macrophages in removing cellular debris was noticed at the stump surface (Fig. 4).• By the third post-amputation day, the main bulk of the blastema was fibro-cellular in nature. Some blastemal cells began to redifferentiate into cartilage cells added to the stump skeleton .• By the fifth post-amputation day, the upper layer of the epidermis was cornified. Procartilaginous streaks were evident in the distal regions as an early indication of autopodial elements on the way to redifferentiate, with indentation at the most distal part of the regenerate as a first sign of toes formation. Muscles were surrounding the skeleton of the regenerate (Fig. 5).• By the seventh post-amputation day, the epidermis was stratified and the dermis was thin and multicellular glands were embedded within the dermis. The shank region was restored completely with its skeletal support. Distally, a chondrifying centre representing the foot skeleton was observed. Muscles were surrounding the skeleton of the regenerate. Lymph spaces were seen beneath the skin. • By the tenth post-amputation day, the shank was completely restored. Distally, long skeletal elements were redifferentiated representing the autopodial skeleton. Muscles were well-redifferentiated surrounding the skeletal elements. The skeletal elements were normally articulating with each other .• By the fifteenth post-amputation

day, redifferentiation progressed distally resulting in the restoration of toes with their skeletal support (Fig. 6).

B) Final cases

i) General morphological characteristics (Table 1 & Fig.2):

- 44 cases were operated. Out of these:

- 12 cases had regenerated five toes. One of them, that was demonstrated with Victoria blue stain, weak chondrification of phalanges of the 1st toe and the terminal phalanges of 2nd toe was observed (Fig. 7).
- 14 cases had regenerated four toes each. One of them, showed that all the regenerated limb segments were normal while the fourth toe was short (Fig. 8).
- Four cases had regenerated three toes each. One of them, that was demonstrated with Alizarin red preparation, astragalus and calcaneum were short and completely fused (Fig. 9).
- Two cases had regenerated two toes each.
- Two cases had regenerated one toe each.
- Two cases had regenerated part of foot.
- Four cases had regenerated part of the shank region with a tapering end.
- Four cases had regenerated part of the shank region with a blunt end.

ii) Histological observations

Two cases were studied microscopically. Both of them showed advanced histogenesis, restored normal skeletal elements with normal configuration and articulation between phalanges. Muscles were well-restored surrounding the skeletal elements (Fig. 10).

Group: 2/56 (Testosterone -treated group):

A) Histogenesis of time-series:

- By the first post-treatment day, a thick epithelial covering closed the wound surface. Basement membrane was indistinct; the wound cover was dermis free. Activity of macrophages in removing cellular debris was noticed. Dedifferentiation of muscles began around the stump skeleton (Fig. 11).
- By the third post-treatment day, the epidermal covering was two or three cells thick. Basement membrane was discontinuous. Unicellular glands were observed. The dedifferentiated mesenchymal cells formed a blastema. The whole regenerate was in the form of a cone (Fig.12).
- By the fifth post-treatment day, melanophores and multicellular glands were spread beneath the epidermis. Mitotic activities of the blastemal cells resulted in more elongation of the regenerate with its pointed distal tip.
- By the seventh post-treatment day, the tibio-fibula was completely restored. Distally, a chondrifying centre representing the autopodial skeleton was

observed. Muscles were surrounding the skeleton of the regenerate (Fig. 13).

- By the tenth post-treatment day, more redifferentiation was observed. redifferentiation of muscles around the skeletal elements was observed
- By the fifteenth post-treatment day, further redifferentiation progressed distally resulting in the restoration of toes with its skeletal support. Skeletal elements were normally articulating with each other (Fig. 14).

B) Final cases:

i) General morphological characteristics (Table 1 & Figs. 2):

- 40 cases were operated:

- 12 cases had regenerated five toes each. One of them, that was demonstrated with Alizarin red preparation, weak ossification of terminal phalanges of 1st, 2nd, 3rd and 5th toes were noticed (Fig. 15).
- 14 cases had regenerated four toes each. In one of them, that was demonstrated with Victoria blue stain, most skeletal elements were strongly chondrified (Fig. 16).
- Five cases had regenerated three toes each. One of them, that was demonstrated with Victoria blue stain, it showed partial fusion between the basal phalanges of the 1st and 3rd toes with skeletal elements of foot region was noticed (Fig. 17).
- Two cases had regenerated two toes each.
- Three cases had regenerated one toe. In one of them, that was demonstrated with Victoria blue stain, chondrifying phalanges supporting the toe were obvious (Fig. 18).
- Two cases had regenerated part of foot.
- Two cases had regenerated part of the shank region with a tapering end.

ii) Histological observations:

Two cases were studied microscopically. In the first case, the one that regenerated three toes, restoration of most skeletal elements and soft tissues was well observed. In the second case; that regenerated two toes, most of the skeletal elements of the foot and toes were restored (Fig. 19).

STAGE 58

Group: 1/58 (Control group)

A) Histogenesis of time-series

- By the first post-amputation day, the wound surface was covered with stratified epithelium. The epithelial cells were having large and rounded nuclei. Some activity of macrophages in removing cellular debris was noticed.
- By the third post-amputation day, the epithelial covering was two or three cells thick. Basement membrane was seen discontinuous. Dermis was still hardly seen. Mitotic activities of the blastemal mesenchyme cells were noticed (Fig. 20).

- By the fifth post-amputation day, few melanophores and multicellular glands were noticed. Cartilage redifferentiation was noticed on both sides of stump skeleton. The distal part of the blastema was still fibrocellular in nature.
- By the seventh post-amputation day, the upper layer of the epidermis was cornified. Cartilage redifferentiation progressed at both sides of the tibio-fibula shaft. Mesenchymal cells of the blastema were still noticed at the distal end of the regenerate (Fig. 21).
- By the tenth post-amputation day, the upper layer of the epidermis was cornified. Melanophores and multicellular glands were noticed. cartilage redifferentiation progressed to form a cap above the collar, while blastema cells were still fibrocellular in nature.
- By the fifteenth post-amputation day, melanophores and multi-cellular glands were highly spread beneath the skin. A cartilaginous collar was formed around the distal end of the shaft of the tibio-fibula. The collar was extending apically to form a cap. A fibrous scar was surrounding the distal part of the skeleton (Fig. 22).

B) Final cases i) General morphological characteristics (Table 1 & Fig. 3)

-30 cases were operated. Out of these:

- Four cases had restored one toe each. In one of them, the shank region was straight with a thin foot ending with a toe-like protrusion. Upon demonstration with Victoria blue preparation, chondrifying phalanges supporting the toe were obvious (Fig. 23).
- Six cases had restored part of the foot. In one of them, that was demonstrated with Victoria blue stain the regenerated part of foot was small, chondrification was obvious at the base of foot (Fig. 24).
- Eight cases had restored the shank region with a tapering end. One of them, that was demonstrated with Alizarin red preparation, there was incomplete restoration of skeletal elements (Fig. 25).
- Eight cases regenerated part of the shank region with a blunt end.
- Four cases were negative.

ii) Histological observations

The examined case regenerated nearly the whole shank with a blunt end; it had a toe-like protrusion laterally, in which, multicellular glands and melanophores were well-spread within the skin. A large cartilaginous condylar cap was formed around the stump skeleton. Muscle fibres were surrounding the skeletal tissue, but merging distally into fibrous scar (Fig. 26).

Group: 2/58 (Testosterone -treated group):

A) Histogenesis of time-series:

- By the first post-treatment day, the wound surface was covered with a thin layer of epithelial cells that were condensed at the distal margin of the stump. These cells were cuboidal with rounded nuclei while the most outer cells were squamous with flattened nuclei-basement membrane and dermis was not seen. Activity of macrophages in removing cellular debris was noticed (Fig. 27).
- By the third post-treatment day, the epithelial covering was two or three cells thick. Basement membrane was discontinuous. Some blastema cells were redifferentiated into procartilage cells above the stump skeleton, while other blastema cells were still undifferentiated having fibro-cellular nature. The regenerate ended with a blunt end (Fig. 28).
- By the fifth post-treatment day, epidermal covering was formed of thick stratified squamous epithelium with underlying thin dermis. Melanophores and multicellular glands were observed. Most of the blastema cells were redifferentiated into cartilage cells and were added to the stump skeleton, while fibrocellular tissue was still observed beneath the skin. Some muscle fibres were redifferentiated at the stump edges, surrounding the skeletal elements (Fig. 29).
- By the seventh post-treatment day, the upper layer of the epidermis was cornified, melanophores and multicellular glands were seen. The addition of cartilage cells to the stump skeleton resulted in the formation of thick collar around the tibio-fibula shaft. Mesenchymal cells of the blastema were intermingled with fibres above the stump skeleton (Fig. 30).
- By the tenth post-treatment day, melanophores and multicellular glands were noticed. A chondrifying centre was formed distally and articulating with the cartilaginous cap. Muscle fibres were redifferentiated around the skeletal tissues. Loose fibrocellular connective tissue was obviously seen beneath the skin. The distal end of the regenerate was protruding outwards (Fig. 31).
- By the fifteenth post-treatment day, epidermis was cornified. The cartilaginous collar formed around the distal part of the shaft of tibio-fibula was extending apically to form a cap. Fibrous bundles were forming a scar underneath the skin (Fig. 32).

B) Final cases:

i) General morphological characteristics (Table 1 & Fig.3):

- 44 cases were operated:

- Two cases had restored two toes, One of them, that was demonstrated with Victoria blue stain, the shank region was short and the foot was considerably ending with toes appeared as two fused small protuberances (Fig.33).
- 15 cases had restored one toe, in one of them, that was demonstrated with Victoria blue preparations, the lateral toe-like protrusion was supported by chondrifying phalanges (Fig.34)

- 20 cases had restored part of the foot. In one of them, that was demonstrated with Alizarin red preparations, complete restoration of tibio-fibula and no skeletal support at the restored part of foot was shown (Fig. 35).
- Six cases had restored the part of the shank region with a tapering end.
- One case had restored part of the shank region with a blunt end.

ii) Histological observations:

The examined case had regenerated part of the foot. A cartilaginous collar was formed representing the distal epiphysis of tibio-fibula and extending distally into a cartilaginous element which is the skeletal support of the foot part (Fig. 36).

4. Discussion

The present study aimed to investigate the effect of testosterone on the restoration of the regenerative capacity in a prometamorphic stage (stage 56) and a metamorphic stage (stage 58) of the Egyptian toad, *Bufo regularis* Reuss, after amputation at the mid-shank level. Selection of the experimental stages was based on the following: Stage 56 represents the prometamorphic stage, during which the regenerative capacity starts to drop down. Stage 58 represents the metamorphic stage, where the regenerative capacity is reduced or completely lost.

Scadding (1979) stated that neither gonadectomy, nor injections of testosterone or 17-beta estradiol, had apparent effect on the rate of regeneration or histological appearance of limb regenerates in the newt *Notophthalmus viridescens*. Neither promotion nor inhibition of limb regeneration was observed.

Tarsoly *et al.*, (1979) concluded that testosterone exerts a direct peripheral effect on the callus cells, presumably on their enzyme system.

Vita *et al.*(1983) tested the effect of testosterone on the reinnervation of the anterior tibialis sciatic nerve following crush in rabbits. And showed that there is accelerative effect of Testosterone on the regeneration process.

Sassoon *et al.* (1986) concluded that testosterone induces both chondrogenesis and myogenesis in juvenile larynx and that this process may contribute to the pronounced sexual dimorphism of the adult vocal organ.

Testosterone has a documented ability to modulate the activity of immune, fibroblast, and myogenic precursor cells, which are all components of regeneration (Grounds, 1987; Zhang *et al.*, 1998; Friedl *et al.*, 2000; Horiguchi *et al.*, 2002 and Schneider *et al.*, 2003).

Jones *et al.*(2001) showed that exogenous administration of testosterone immediately after

nerve injury impacts positively on the functional recovery through actions mediated by the androgen

receptor. The mechanism by which steroidal enhancement of the regenerative properties of

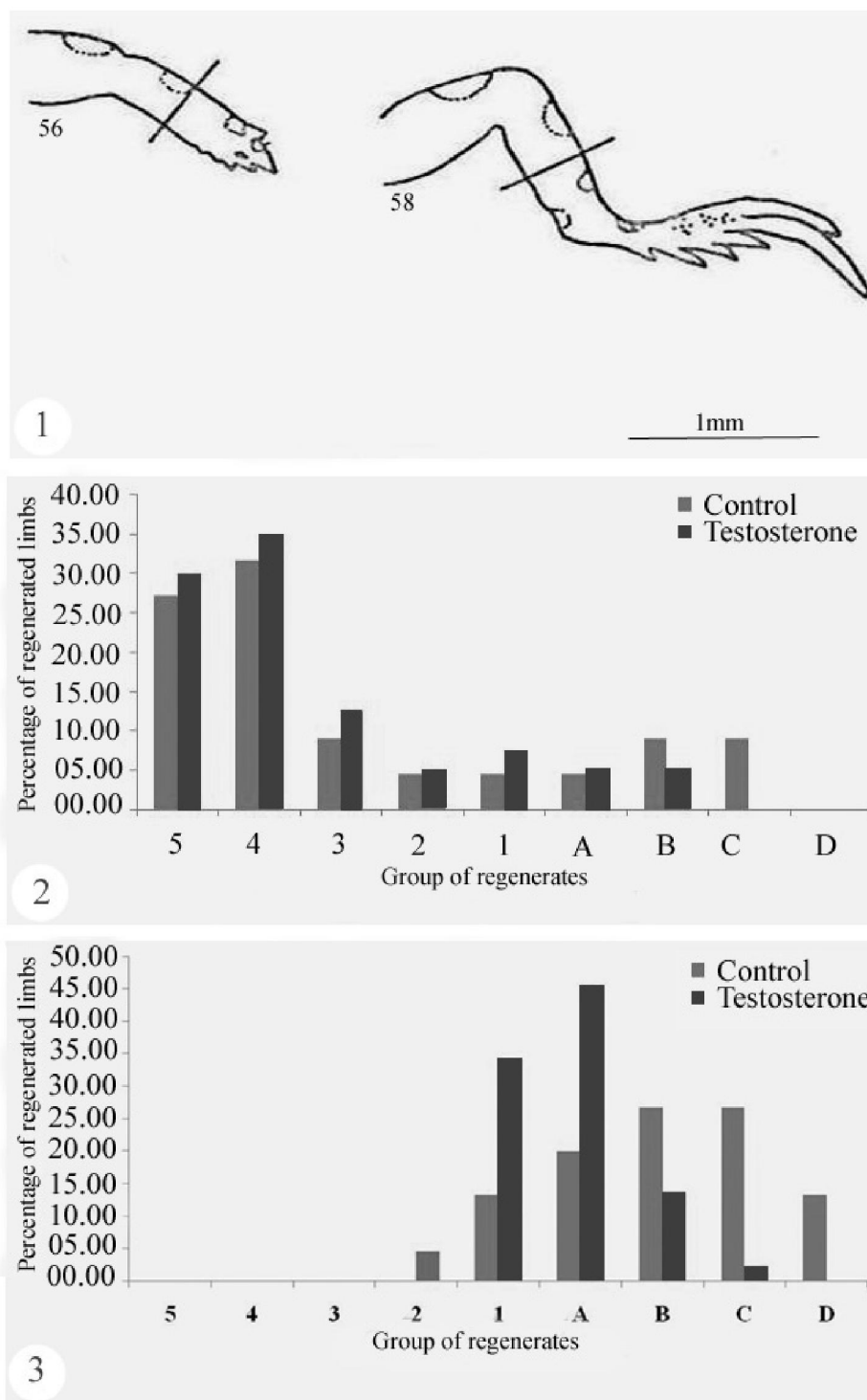


Fig. (1): Diagrammatic drawing of the left hind-limbs of stages 56 and 58 of the tadpoles of *Bufo regularis* Reuss, shown in antero-lateral view. The level of amputation is represented by a line transecting the mid-shank level.

Fig. (2): A histogram showing comparison between the regenerates of control and experimental tadpoles treated with Testosterone after amputation at the mid-shank of stage (56) of *Bufo regularis*.

Fig. (3): A histogram showing comparison between the regenerates of control and experimental tadpoles treated with Testosterone after amputation at the mid-shank of stage (58) of *Bufo regularis*.

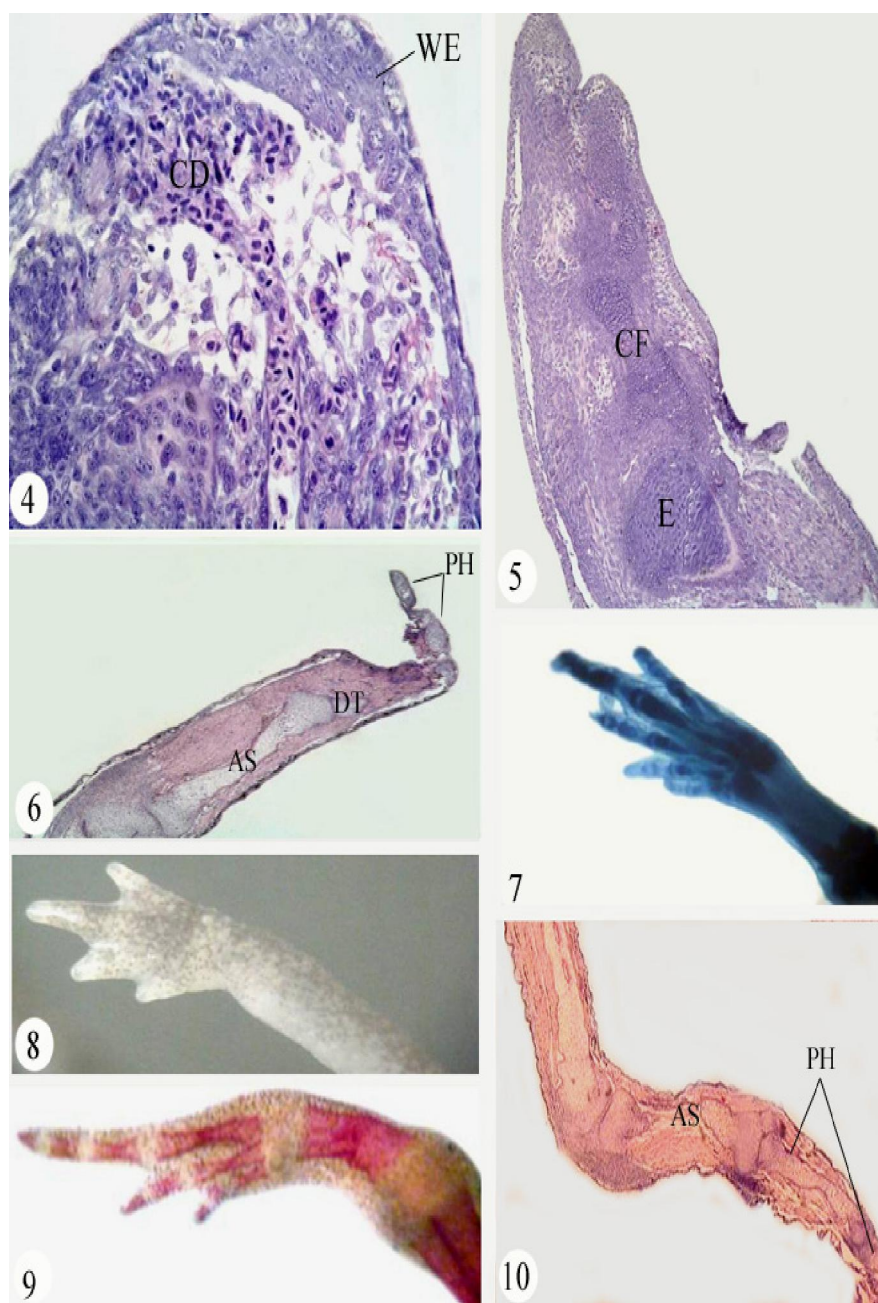


Fig. (4): A photomicrograph of a longitudinal section of a regenerate of left hind limb, fixed one day after amputation. H&E stain (X 200).

Fig. (5): A photomicrograph of a longitudinal section of a regenerate of left hind limb, fixed five days after amputation. H&E stain (X 100).

Fig. (6): A photomicrograph of a longitudinal section of a regenerate of left hind limb, fixed fifteen days after amputation. H&E stain (X 100).

Fig. (7): A photomicrograph of a regenerate of left hind limb, fixed two weeks after metamorphosis and demonstrated with Victoria blue stain (X 25).

Fig. (8): A photomicrograph of a regenerate of left hind limb, fixed two weeks after metamorphosis (X 25).

Fig. (9): A photomicrograph of a regenerate of left hind limb, fixed two weeks after metamorphosis and demonstrated with Alizarin red stain (X 25).

Fig. (10): A photomicrograph of a longitudinal section of a regenerate of left hind limb, fixed two weeks after metamorphosis. H&E stain (X 40).

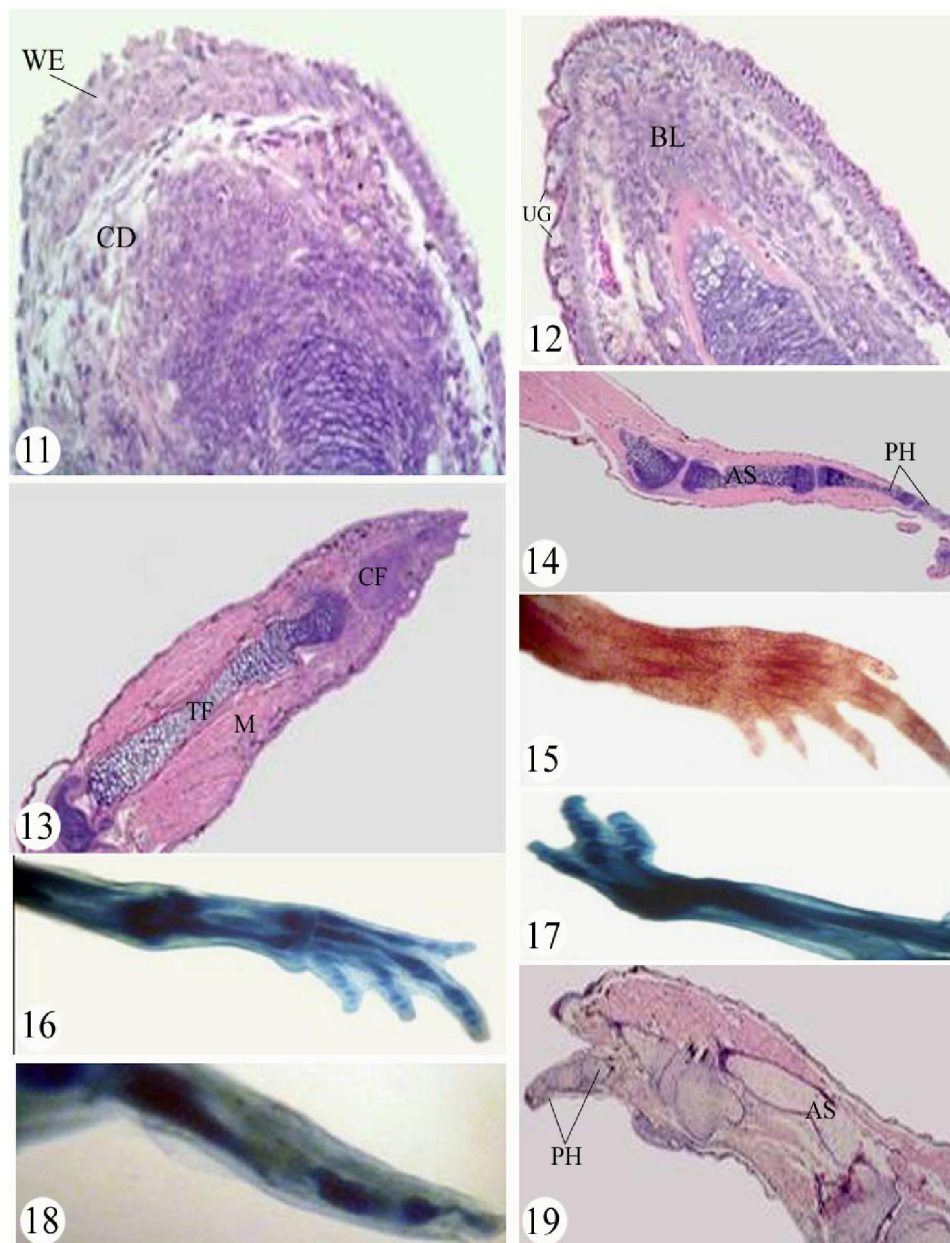


Fig. (11): A photomicrograph of a longitudinal section of a regenerate of left hind limb, fixed one day after amputation. H&E stain (X 200).

Fig.(12): A photomicrograph of a longitudinal section of a regenerate of left hind limb, fixed three days after amputation. H&E stain (X 200).

Fig.(13): A photomicrograph of a longitudinal section of a regenerate of left hind limb, fixed seven days after amputation. H&E stain (X 40).

Fig. (14): A photomicrograph of a longitudinal section of a regenerate of left hind limb, fixed fifteen days after amputation. H&E stain (X 40).

Fig. (15): A photomicrograph of a regenerate of left hind limb, fixed two weeks after metamorphosis and demonstrated with Alizarin red stain (X 25).

Fig. (16): A photomicrograph of a regenerate of left hind limb, fixed two weeks after metamorphosis and demonstrated with Victoria blue stain (X 25).

Fig. (17): A photomicrograph of a regenerate of left hind limb, fixed two weeks after metamorphosis and demonstrated with Victoria blue stain (X 25).

Fig. (18): A photomicrograph of a regenerate of left hind limb, fixed two weeks after metamorphosis and demonstrated with Victoria blue stain (X 25).

Fig. (19): A photomicrograph of a longitudinal section of a regenerate of left hind limb, fixed two weeks after metamorphosis. H&E stain (X 40).

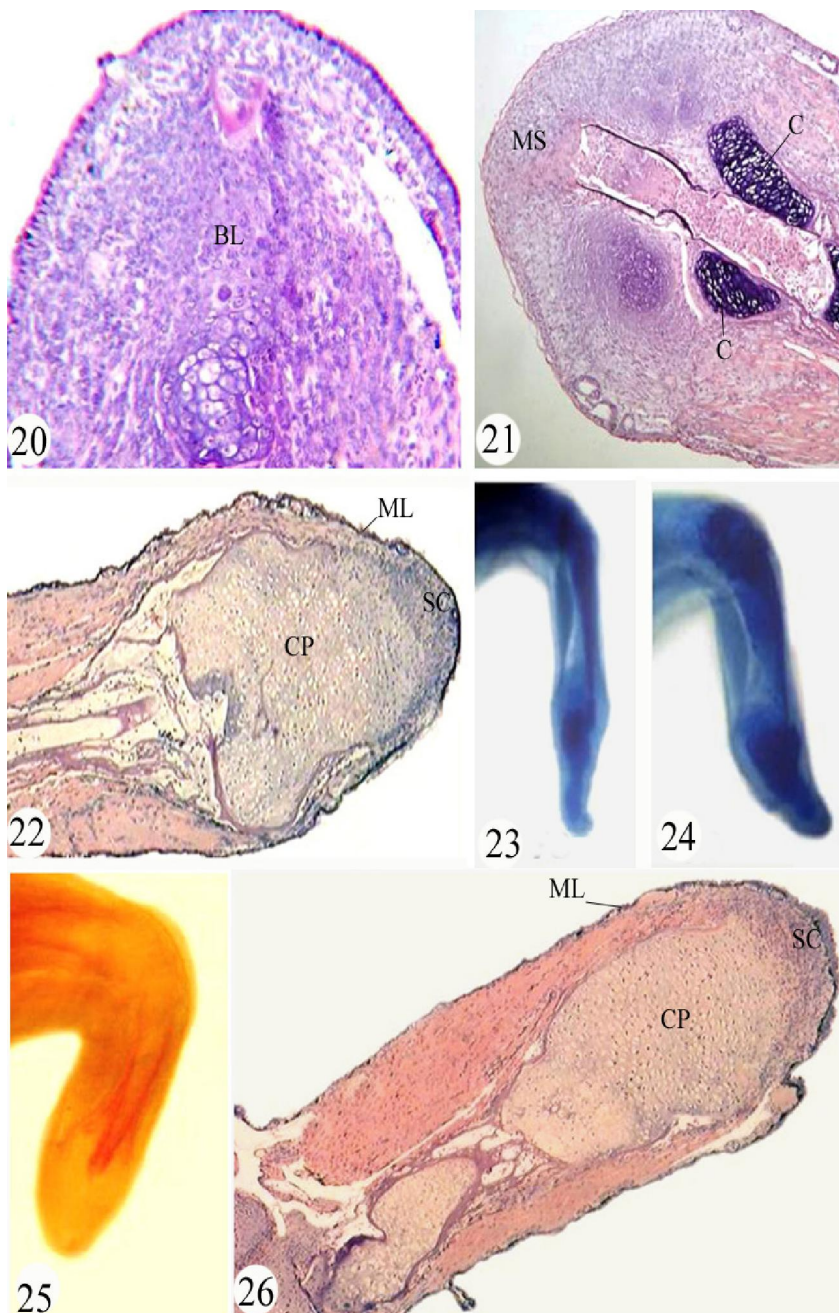


Fig. (20): A photomicrograph of a longitudinal section of a regenerate of left hind limb, fixed three days after amputation. H&E stain (X 100).

Fig. (21): A photomicrograph of a longitudinal section of a regenerate of left hind limb, fixed seven days after amputation. H&E stain (X 40).

Fig. (22): A photomicrograph of a longitudinal section of a regenerate of left hind limb, fixed fifteen days after amputation. H&E stain (X 100).

Fig. (23): A photomicrograph of a regenerate of left hind limb, fixed two weeks after metamorphosis and demonstrated with Victoria blue stain (X 25).

Fig. (24): A photomicrograph of a regenerate of left hind limb, fixed two weeks after metamorphosis and demonstrated with Victoria blue stain (X 25).

Fig. (25): A photomicrograph of a regenerate of left hind limb, fixed two weeks after metamorphosis and demonstrated with Alizarin red stain (X 25).

Fig. (26): A photomicrograph of a longitudinal section of a regenerate of left hind limb, fixed two weeks after metamorphosis. H&E stain (X 40).

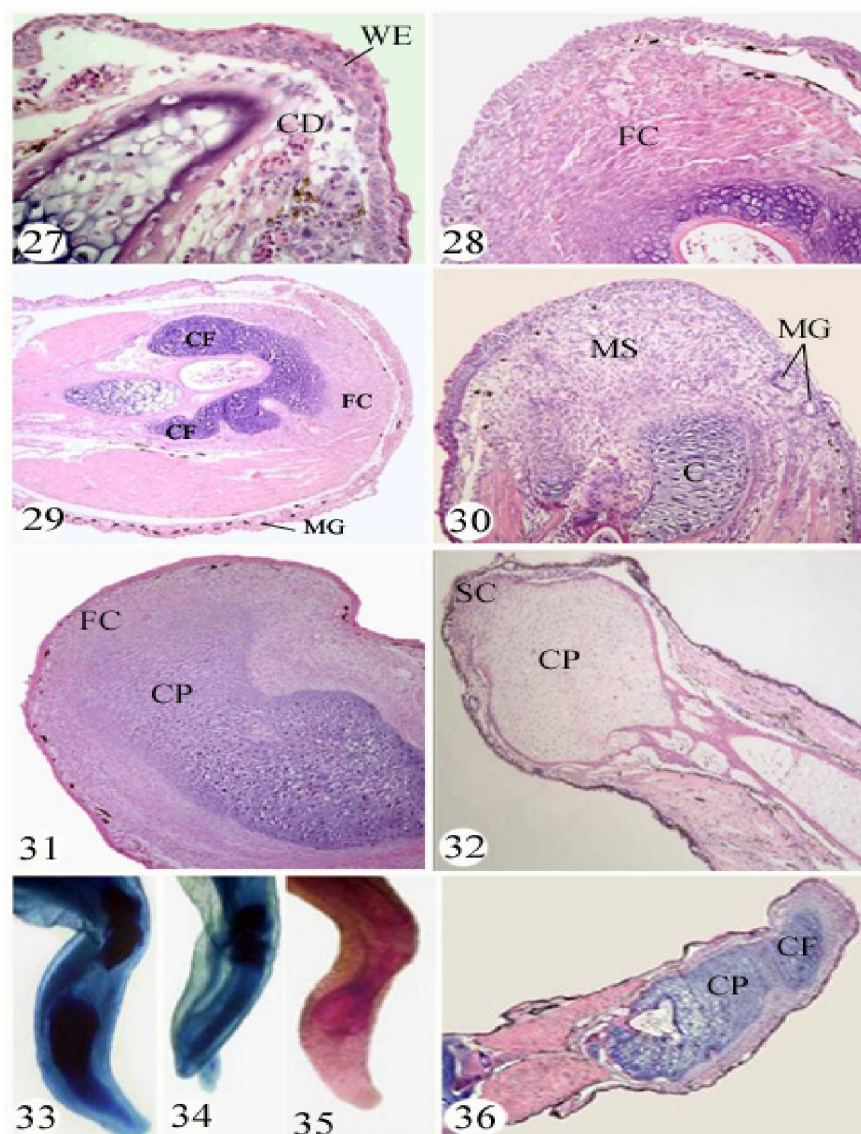


Fig. (27): A photomicrograph of longitudinal section of a regenerate of left hind limb, fixed one day after amputation. H&E stain (X 200).

Fig.(28): A photomicrograph of longitudinal section of a regenerate of left hind limb, fixed three days after amputation. H&E stain (X 200).

Fig.(29): A photomicrograph of aLongitudinal section of a regenerate of left hind limb, fixed five days after amputation. H&E stain (X 100).

Fig.(30): A photomicrograph of a longitudinal section of a regenerate of left hind limb, fixed seven days after amputation. H&E stain (X 100).

Fig.(31): A photomicrograph of alongitudinal section of a regenerate of left hind limb, fixed ten days after amputation. H&E stain (X 100).

Fig.(32): A photomicrograph of aLongitudinal section of a regenerate of left hind limb, fixed fifteen days after amputation. H&E stain (X 40).

Fig. (33): A photomicrograph of a regenerate of left hind limb, fixed two weeks after metamorphosis and demonstrated with Victoria blue stain (X 25).

Fig. (34): A photomicrograph of a regenerate of left hind limb, fixed two weeks after metamorphosis and demonstrated with Victoria blue stain (X 25).

Fig. (35): A photomicrograph of a regenerate of left hind limb, fixed two weeks after metamorphosis and demonstrated with Alizarin red stain (X 25).

Fig. (36): A photomicrograph of a longitudinal section of a regenerate of left hind limb, fixed two weeks after metamorphosis. H&E stain (X 40).

injured motoneurons occurs may involve pre-existing androgen receptors, heat shock proteins, and modulation of the cellular stress response.

Testosterone generally has immunosuppressive and anti-inflammatory properties (McCrudden and Stimson, 1991; Giglio *et al.*, 1994; Wichmann *et al.*, 1997; Savita and Rai, 1998), although there is evidence that Testosterone promotes inflammation in dermal wound healing (Ashcroft and Mills, 2002; Ashcroft *et al.*, 2003).

Testosterone increases expression of the nerve growth factor (Tirassa *et al.*, 1997) and mediates promotion of neurite growth and interneural communication through branching and arborization (Kujawa *et al.*, 1991).

Phillip *et al.* (2001) conclude that testosterone has a direct, local, GH-independent effect on growth of the tibial epiphyseal growth plate and IGF-1 receptor abundance in hypophysectomized and castrated rats.

White *et al.* (2009) showed that Nandrolone decanoate (ND) (exogenous testosterone) administration can enhance castrated mouse muscle regeneration during the recovery from bupivacaine-induced injury. ND had a main effect for increasing muscle MyoD and cyclin D1 mRNA expression at 14 days.

The present results indicated an enhancing effect of testosterone treatment on limb regeneration in stage 56, where 90% of the cases regenerated toes ranging from five to one compared with 77.3% in the control group, also the differential effect of testosterone on the number of toes was obvious in the treated animals, where 30% and 35% of the cases regenerated five and four toes respectively compared with 27.3% and 31.8% in the control group.

In the metamorphic stage (stage58), the effect of testosterone was also obvious, where 38.6% of the treated cases restored toes compared with 13.3% of the cases in the control group. And 45.5% of the treated cases restored part of the foot compared with 20 % of the cases in the control group.

The present results agree with and support the results of (Dyson and Joseph 1968; Vita *et al.*, 1983; Grounds 1987; Zhang *et al.*, 1998; Friedl *et al.*, 2000; Horiguchi *et al.*, 2002 and Schneider *et al.*, 2003). Who showed the accelerative effect of testosterone on the regeneration process.

Histological observations of the treated limbs revealed that the formation of thick epithelial covering and complete skin is faster than that of the control animals.

Demling (1999) found that anabolic agents, human growth hormone, HGH, and the testosterone analogue, oxandrolone, after severe burn injury,

significantly decreased weight and nitrogen loss and increased healing with nearly identical benefits.

Testosterone is needed for the wound healing process since decreased levels impede healing (Stanford *et al.*, 1999; Demling, 2000; Demling and Orgill 2000).

Karim *et al.* (1973); Janssens and Vanderscheuren (2000) demonstrated a significant increase in net protein synthesis, especially in muscle and skin, with high doses of Testosterone delivered parenterally.

Previous studies have shown the importance of testosterone on dermal wound healing (Ashcroft and Mills, 2002; Ashcroft *et al.*, 2003) and the modulatory effects of this hormone on immune responses (Cutolo *et al.*, 2002; Palaszynski *et al.*, 2004).

Robert and Demling (2005) showed that exogenous administration of anabolic agents ,human growth hormone, insulin-like growth factor-1, insulin, testosterone and its analogs maintained or increased lean body mass as well as directly stimulate the healing process through their anabolic and anticatabolic actions.

The anabolic properties of testosterone were defined in the 1930s. These include an increase in muscle size, synthesis, and strength. Increased skin thickness has also been noted with administration of testosterone to hypogonadal men. The importance of testosterone is evident by the complications seen with low Testosterone levels, which include sarcopenia or lost lean mass, increased rate of development of osteoporosis, anemia, thinning of skin , weakness, and impaired wound healing (Carson-Jurica *et al.*, 1990; Kuhn, 2002 and Matsumoto, 2002)

Engeland *et al.* (2009) suggested that human mucosal healing rates are modulated by testosterone levels. Based upon when between-group differences were observed, testosterone may impact upon the proliferative phase of healing which involves immune processes such as reepithelialization and angiogenesis.

Hobbs *et al.* (1993) indicated that 6 weeks treatment of normal men with testosterone leads to an increase in serum IGF-I levels.

IGF-1 is considered to be a wound healing stimulant, increasing cell proliferation and collagen synthesis (Lieberman *et al.*, 1994; Lin *et al.*, 1998; Coerper *et al.*, 2001; Blumenfield *et al.*, 2002).

From the conclusions of Stanford *et al.* (1999); Demling (2000); Demling and Orgill (2000); Engeland *et al.* (2009) it may be suggested that the enhancing effect of Testosterone on limb regeneration may be due to its acceleration of wound healing either by its action upon the proliferative phase of healing which involves immune processes such as reepithelialization and angiogenesis or by the production of IGF-1.

Bhasin et al. (2006) proposed that testosterone could promote the differentiation of mesenchymal multipotent cells into the myogenic lineage while inhibiting adipogenic differentiation by modulating nuclear translocation of β -catenin.

Singh et al. (2009) indicated that testosterone promotes the nuclear translocation of β -catenin through an AR-mediated mechanism in C3H 10T1/2 cells.

Hong et al. (2011) Concluded that testosterone regulates β -catenin protein level and proliferation rate in mesenchymal tumour (desmoid tumour).

Zhao et al. (2011) provided that Testosterone increases cellular β -catenin content which promotes the expression of β -catenin-targeted genes and myogenesis in the muscle-derived stem cells of cattle.

β -catenin is essential for adult skeletal muscle growth and regeneration *in vivo* (**Poleskaya et al., 2003; Reya and Clevers, 2005; Armstrong et al., 2006**)

Yokoyama et al. (2007) demonstrated that Wnt/ β -catenin signaling plays an essential role during the early phases of limb regeneration and is important, but not absolutely required, during the subsequent phases of limb regeneration in *Xenopus*.

From the conclusions of **Bhasin et al. (2006); Yokoyama et al. (2007); Singh et al. (2009); Zhao et al. (2011)**. It is suggested that Testosterone may enhance the limb regeneration by its stimulatory effect through Wnt/ β -catenin signaling resulting in the initiation of the early phases of limb regeneration.

Corresponding Author

Hamida Hamdi

Department of Zoology, Faculty of Science, Cairo University, Egypt

E-Mail: Hamdihamida@rocketmail.com

References

- Agata K, Saito Y, Nakajima E. (2007): Unifying principles of regeneration I: Epimorphosis versus morphallaxis. *Development, Growth and Differentiation*; 49: 73–78.
- Armstrong DD, Wong VL, Esser KA. (2006): Expression of β -catenin is necessary for physiological growth of adult skeletal muscle. *American Journal of Physiology*; 291: C185–C188.
- Ashcroft GS, Mills SJ. (2002): Androgen receptor-mediated inhibition of cutaneous wound healing. *Journal of Clinical Investigation*; 110: 615–624.
- Ashcroft GS, Mills SJ, Flanders KC, Lyakh LA, Anzano MA, Gilliver SC, Roberts AB. (2003): Role of Smad3 in the hormonal modulation of *in vivo* wound healing responses. *Wound Repair and Regeneration*; 11: 468–473.
- Bardin CW. (1996): The anabolic action of Testosterone. *New England Journal of Medicine*; 335 52–53.
- Beran M, Spitzer G, Verma DS. (1982): Testosterone and synthetic androgens improve the *in vitro* survival of human marrow progenitor cells in serum-free suspension cultures. *Journal of Laboratory and Clinical Medicine*; 99(2): 247–53.
- Bhasin S, Storer TW, Berman N, Yarasheski KE, Clevenger B, Phillips J, Lee WP, Bunnell TJ, Casaburi R. (1997): Testosterone replacement increases fat-free mass and muscle size in hypogonadal men. *Journal of Clinical Endocrinology and Metabolism*; 82(2): 407–13.
- Bhasin S, Calof OM, Storer TW, Lee ML, Mazer NA, Jasuja R, Montori VM, Gao W, Dalton JT. (2006): Drug insight: Testosterone and selective androgen receptor modulators as anabolic therapies for chronic illness and aging. *Nature Clinical Practice Endocrinology and metabolism*; 2: 146–159.
- Bhasin S, Storer TW, Javanbakht M, Berman N, Yarasheski KE, Phillips J, Dike M, Sinha-Hikim I, Shen R, Hays RD. *et al.* (2000): Testosterone replacement and resistance exercise in HIV-infected men with weight loss and low Testosterone levels. *Journal of the American Medical Association*; 283: 763–770.
- Blumenfeld I, Saiyyi S, Lanir Y. (2002): Enhancement of bone defect healing in old rats by TGF β and IGF-1. *Experimental Gerontology*; 37: 53–55.
- Borgens R B. (1982): Mice regrow the tips of their foretoes. *Science*; 217: 747–750.
- Brookes JP. (1997): Amphibian limb regeneration: rebuilding a complex structure. *Science*; 276: 81–87.
- Brown TJ, Storer P, Oblinger M, Jones KJ. (2001): Androgenic enhancement of β actin-tubulin mRNA in spinal motoneurons following sciatic nerve injury. *Restorative Neurology and Neuroscience*; 18(4): 191–8.
- Bryant, SV, Iten, LE. (1974): The regulative ability of the limb regeneration blastema of *Notophthalmus viridescens*: Experiments *in situ*. *Wilhelm Roux' Arch.*, 174: 190.
- Carson-Jurica MA, Schrader WT, O'Malley BW. (1990): Steroid receptor family: structure and functions. *Endocrine Reviews*; 11: 201–220.
- Cayan F, Tek M, Balli E, Oztuna SKarazindiyanoglu S, Cayan S, (2008): The effect of Testosterone alone and Testosterone + estradiol therapy on bladder functions and smooth muscle/collagen content in surgically menopause induced rats. *Maturitas*, 60(3–4): 248–52.
- Coerper S, Wolf S, von Kiparski S, Thomas S, Zittel TT, Ranke MB, Hunt TK, Becker HD. (2001): Insulin-like growth factor I accelerates

- gastric ulcer healing by stimulating cell proliferation and by inhibiting gastric acid secretion. *Scandinavian Journal of Gastroenterology*; 36:921-927.
- Cutolo M, Villaggio B, Cravotto C, Pizzorni C, Serio B, Sulli A. (2002): Sex hormones and rheumatoid arthritis. *Autoimmunity Reviews*; 1(5):284-9.
- De Luca A, Pierno S, Camerino C, Cocchi D, Camerino D C. (1999): Higher content of insulin like-growth factor I in dystrophic mdx mouse: Potential role in the spontaneous regeneration through an electrophysiological investigation of muscle function. *Neuromuscular disorders*; 9 (1): 11-18.
- Demling RH. (1999): Comparison of the anabolic effects and complications of human growth hormone and the Testosterone analog, oxandrolone, after severe burn injury. *Burns*; 25(3):215-21.
- Demling RH. (2000): Oxandrolone, an anabolic steroid, enhances the healing of a cutaneous wound in the rat. *Wound Repair and Regeneration*; 8:97-102.
- Demling RH, Orgill DP. (2000): The anticatabolic and wound healing effects of the Testosterone analog oxandrolone after severe burn injury. *Journal of Critical Care*; 15:12-17.
- Dent JN. (1962): Limb regeneration in larvae and metamorphosing individuals of the South African clawed toad. *Journal of Morphology*; 110: 61-78.
- Digit tip regeneration correlates with regions of *Msx1 (Hox7)* expression in fetal and newborn mice. *Development*; 121: 1065-1076.
- Douglas BS. (1972): Conservative management of guillotine amputation of the finger in children. *Australian Paediatric Journal*; 8: 86-89.
- Dyson M, Joseph J. (1968): The effect of androgens on tissue regeneration. *Journal of Anatomy*; 103(3): 491-505.
- Engeland CG, Sabzehei B, Marucha PT. (2009): Sex hormones and mucosal wound healing. *Brain, Behavior, and Immunity*; 23(5):629-35.
- Friedl R, Brunner M, Moeslinger T, Spieckermann PG. (2000): Testosterone inhibits expression of inducible nitric oxide synthase in murine macrophages. *Life Sciences*; 68: 417-429.
- Fu R, Liu J, Fan J, Li R, Li D, Yin J, Cui S. (2011): Novel evidence that Testosterone promotes cell proliferation and differentiation via G protein-coupled receptors in the rat L6 skeletal muscle myoblast cell line. *Journal of Cellular Physiology*; 227: 98-107.
- Giglio T, Imro M, Filaci G, Scudeletti M, Puppo F, De Cecco L, Indiveri F, Costantini S (1994). Immune cell circulating subsets are affected by gonadal function. *Life Science*; 54:1305-1312.
- Grounds MD. (1987): Phagocytosis of necrotic muscle in muscle isografts is influenced by the strain, age, and sex of host mice. *The Journal of Pathology*; 153: 71-82.
- Hobbs CJ, Plymate SR, Rosen CJ, Adler RA. (1993): Testosterone administration increases insulin-like growth factor-I levels in normal men. *The Journal of Clinical Endocrinology and Metabolism*; 77(3): 776-9.
- Hong H, Nadesan P, Poon R, Alman BA (2011): Testosterone regulates cell proliferation in aggressive fibromatosis (desmoid tumour). *The British Journal of Cancer*; 26;104(9):1452-8.
- Horiguchi T, Shibata MA, Ito Y, Eid NA, Abe M, Otsuki Y. (2002): Macrophage apoptosis in rat skeletal muscle treated with bupivacaine hydrochloride: possible role of MCP-1. *Muscle Nerve*; 26: 79-86.
- Illingworth CM. (1974): Trapped fingers and amputated finger tips in children. *Journal of Pediatric Surgery*; 9:853-858.
- Janssens H, Vanderscheuren D. (2000): Endocrinological aspects of aging in man: is hormone replacement of benefit? *European Journal of Obstetrics & Gynecology and Reproductive Biology*; 92:9-12.
- Jones K.J, Brown T.J, Damaser M (2001): Neuroprotective effects of gonadal steroids on regenerating peripheral motoneurons. *Brain Research Reviews*; 37(1-3):372-82.
- Karim A, Ranney E, Zagarella BA. (1973): Oxandrolone disposition and metabolism in man. *Clinical Pharmacology & Therapeutics*; 14:862-866.
- Katznelson L, Finkelstein JS, Schoenfeld DA, Rosenthal DI, Anderson EJ, Klibanski A. (1996): Increase in bone density and lean body mass during Testosterone administration in men with acquired hypogonadism. *Journal of Clinical Endocrinology and Metabolism*; 81 4358-4365.
- Kinderman NB, Jones KJ. (1993): Testosterone enhancement of the nerve cell body response to injury: evidence using in situ hybridization and ribosomal DNA probes. *Journal of Neuroscience* 13, 1523-1532.
- Kuhn C. (2002): Anabolic steroids. *Recent Progress in Hormone Research*; 57:411-434.
- Kujawa KA, Emeric E, Jones KJ. (1991): Testosterone differentially regulates the regenerative properties of injured hamster facial motoneurons. *Journal of Neuroscience*; 11:3898-3906.
- Leon Y, Sanz C, Giraldez F, Varela-Nieto I. (1998): Induction of cell growth by insulin and insulin like growth factor-I is associated with Jun expression in the otic vesicle. *Journal of Comparative Neurology*; 398 (3): 323-332.
- Lieberman S, Bukar J, Chen S. (1994): Effects of recombinant human insulin-like growth in cachectic patients with the acquired immunodeficiency syndrome. *The Journal of*

- Clinical Endocrinology and Metabolism;78:404–410.
- Lin E, Goncalves JA, Lowry SF. (1998): Efficacy of nutritional pharmacology in surgical patients. *Current Opinion in Clinical Nutrition & Metabolic Care*; 1:41–50.
- Little CM, Coons KD, Sengelaub DR. (2009): Neuroprotective effects of Testosterone on the morphology and function of somatic motoneurons following the death of neighboring motoneurons. *The Journal of Comparative Neurology*; 512 (3):359–372.
- Masaki H, Ide H. (2007): Regeneration potency of mouse limbs. *Development, Growth & Differentiation*; 49: 89–98.
- Matsumoto A. (2002): Andropause: clinical implications of the decline in serum Testosterone levels with aging in man. *Journals of Gerontology Series A: Biological Sciences and Medical Sciences.*; 57:76–99.
- McCruden, AB, Stimson, WH. (1991): Sex hormones and immune function. In: Ader, R., editor. *Psychoneuroimmunology*. Academic Press; New York. p. 475–493.
- Muneoka K, Sasson D. (1992): Molecular aspects of regeneration in developing vertebrate limbs. *Developmental Biology*; 152: 37–49.
- Muneoka K, Holler-Dinsmore G, Bryant S V. (1986): Intrinsic control of regenerative loss in *Xenopus laevis* limbs. *The Journal of Experimental Zoology*; 240 (1): 47–54.
- Palaszynski KM, Loo KK, Ashouri JF, Liu HB, Voskuhl RR. (2004): Androgens are protective in experimental autoimmune encephalomyelitis: implications for multiple sclerosis. *Journal of Neuroimmunology*; 146(1-2):144–52.
- Phillip M, Maor G, Assa S, Silbergeld A, Segev Y. (2001): Testosterone stimulates growth of tibial epiphyseal growth plate and insulin-like growth factor-1 receptor abundance in hypophysectomized and castrated rats. *Endocrine.*; 16(1):1–6.
- Polesskaya A, Seale P, Rudnicki MA. (2003): Wnt signaling induces the myogenic specification of resident CD45C adult stem cells during muscle regeneration. *Cell*; 113: 841–852.
- Prokai-Tatrai K P, Perjesi NM, Rivera-Portalatin JW, Simpkins Prokai L. (2007): Mechanistic investigations on the antioxidant action of a neuroprotective estrogen derivative. *Steroids*; 73:280–288.
- Reginelli, A D, Wang Y Q, Sassoon D, Muneoka K. (1995): Digit tip regeneration correlates with regions of *Msx1 (Hox7)* expression in fetal and newborn mice. *Development*, 121: 1065–1076.
- Reya T, Clevers H. (2005): Wnt signalling in stem cells and cancer. *Nature*, 434: 843–850.
- Robert H, Demling MD (2005) : The role of anabolic hormones for wound healing in catabolic states. *Journal of Burns and Wounds*; 17: 4:e2.
- Sassoon D, Segil N, Kelley D. (1986): Androgen-induced myogenesis and chondrogenesis in the larynx of *Xenopus laevis*. *Developmental Biology*; 113 (1):135–40.
- Sato K, Chernoff E A. (2007): The short toes mutation of the axolotl. *Development, Growth & Differentiation*; 49:469–478.
- Savita Rai U. (1998): Sex steroid hormones modulate the activation of murine peritoneal macrophages: receptor mediated modulation. *Comparative Biochemistry and Physiology Part C: Pharmacology, Toxicology and Endocrinology*; 119:199–204.
- Scadding S R. (1979): Effect of Testosterone and 17-beta estradiol on limb regeneration in the newt, *Notophthalmus viridescens*. *Experientia*; 35 (12): 1665–1666.
- Schneider CP, Schwacha MG, Samy TS, Bland KI, Chaudry IH. (2003): Androgen-mediated modulation of macrophage function after traumahemorrhage: central role of 5 alpha-dihydroTestosterone. *Journal of Applied Physiology*; 95: 104–112.
- Sedra SN. (1950): Decreasing the time required for making an Alizarin skeletal preparation. *Stain Technology*; 25 (4): 223–224.
- Sedra S N, Michael ML. (1961): Normal table of the Egyptian toad, *Bufo regularis* Reuss, with an addendum on the standardization of the stages considered in previous publications. *Ces. Morphologia*, 9: 333–351.
- Singh R, Bhasin S, Braga M, Artaza JN, Pervin S, Taylor WE, Krishnan V, Sinha SK, Rajavashisth TB, Jasuja R. (2009): Regulation of myogenic differentiation by androgens: cross talk between androgen receptor/ beta-catenin and follistatin/transforming growth factor-beta signaling pathways. *Endocrinolog.*; 150(3):1259–68.
- Sinha-Hikim I, Roth SM, Lee MI, Bhasin S. (2003): Testosterone-induced muscle hypertrophy is associated with an increase in satellite cell number in healthy, young men. *American Journal of Physiology - Endocrinology and Metabolism*; 285(1):E197–205.
- Stanford A, Barbieri T, Van Loan M. (1999): Resistance exercise and supraphysiologic androgen therapy in eugonadal men with HIV-related weight loss. A randomized placebo controlled trial. *Journal of the American Medical Association*; 281:1282–1290.
- Suzuki M, Yakushiji N, Nakada Y, Satoh A, Ide H, Tamura K. (2006): Limb Regeneration in *Xenopus laevis* Froglet. *Science World Journal*; 6, 26–37.
- Swerdlloff RS, Wang C. (2003): Three-year follow-up of androgen treatment in hypogonadal men:

- preliminary report with Testosterone gel. Aging Male ;6 :207–211.
- Tarsoly E, Jánosy J, Kosztura L. (1979): Effect of Testosterone on fracture healing in hypophysectomized rats. *Acta Histochemica*; 65(1):25-33.
- Tirassa P, Thiblin I, Agren G, Vigneti E, Aloe L, Stenfors C. (1997): High-dose anabolic steroids modulate concentration of nerve-growth factor and expression of its low affinity receptor (p75-ngFr) in male rat brain. *Journal of Neuroscience Research*;47:198–207.
- Ustünel I, Akkoyunlu G, Demir R. (2003): The effect of Testosterone on gastrocnemius muscle fibres in growing and adult male and female rats: a histochemical, morphometric and ultrastructural study. *Anatomia, Histologia, Embryologia*; 32(2):70-9.
- Vita G, Dattola P, Girlanda Oteri G, Lo Presti F, Messina C. (1983): Effects of steroid hormones on muscle reinnervation after nerve crush in rabbit. *Experimental Neurology*; 80: 79–287.
- White JP, Baltgalvis KA, Sato S, Wilson LB, Carson JA, (2009): Effect of nandrolone decanoate administration on recovery from bupivacaine-induced muscle injury. *Journal of Applied Physiology*; 107(5):1420-30.
- Wichmann MW, Ayala A, Chaudry IH. (1997): Male sex steroids are responsible for depressing macrophage immune function after trauma-hemorrhage. *American Journal of Physiology*; 273: C1335–C1340.
- Wilson RE, Coons KD, Sengelaub DR. (2009): Neuroprotective effects of Testosterone on dendritic morphology following partial motoneuron depletion: efficacy in female rats. *Neuroscience Letters*;13:465(2):123-7.
- Yokoyama H, Ogino H, Stoick-Cooper CL, Grainger RM, Moon RT. (2007): Wnt/beta-catenin signaling has an essential role in the initiation of limb regeneration. *Developmental Biology*; 1:306(1):170-8.
- Zhang J, Pugh TD, Stebler B, Ershler WB, Keller ET. (1998): Orchiectomy increases bone marrow interleukin-6 levels in mice. *Calcified Tissue International*; 62: 219–226.
- Zhao JX, Hu J, Zhu MJ, Du M. (2011): Trenbolone enhances myogenic differentiation by enhancing β -catenin signaling in muscle-derived stem cells of cattle. *Domestic Animal Endocrinology*; 40(4):222-9.

10/25/2011