

# Alternative technique for breast augmentation in patients with a small transthehal incision<sup>☆</sup>

Zhengjun Cui<sup>1</sup>, Shibo Zou<sup>1</sup>, Seung Kyu Han<sup>2,\*</sup>, Kyung Wook Chun<sup>2</sup>, Wook Yung Kim<sup>2</sup>

<sup>1</sup>Plastic Surgery Department, The First Affiliated Hospital of Zhengzhou University, Zhengzhou, Henan 450052, China;

<sup>2</sup>Department of Plastic Surgery, Korea University Guro Hospital, Seoul 152703, Korea

Received November 6, 2008

## Abstract

**Background.** The selection of skin incision location for augmentation mammoplasty is very important. Up till now, there are no established standards for skin incision. Convenient and less invasive operating procedure with minimal post-operative scar formation are the developing directions. **Objective.** To describe a simple procedure for breast augmentation in patients with a small transthehal incision to produce an inconspicuous scar. **Methods.** All patients underwent surgery under either general or local anesthesia. We utilized the transthehal incision, which was 2 mm higher than lower nipple margin. It could be extend using a back cut within the pigmented areolar skin bilaterally. Total incision length was about 2 cm. The dissection was made through the mammary parenchyma or subglandular for implant placement. A saline breast implant with diaphragm valve was inserted and injected 200 – 300 ml saline, which was followed by sealing in layers and wrapping up the incisions after confirming the symmetrical size and shape for both breasts. **Results.** Between January 2000 and December 2007, we used this incision technique in thirty patients, who requested primary or secondary breast augmentation with saline breast implants. All the patients displayed excellent satisfaction postoperatively and at final follow-up with minimal scar formation as well as scar color and quality of healing. There were no deformation of nipples and capsular contracture of implants, and no implant asymmetry bilaterally. Mild post-operative sensory loss was present in 1 up to 3 months postoperatively in 5 patients which was resolved ultimately. Ten patients had rippling and two patients required insertion of new implants because of rupture of implants. **Conclusions.** This simple procedure is an effective technique for augmentation mammoplasty with saline-filled implants, which has less complication rate with minimal scar formation. Wide spread application of this implant is recommended to establish its acceptability. [Life Science Journal. 2009; 6(1): 40 – 46] (ISSN: 1097 – 8135).

**Keywords:** augmentation mammoplasty; transthehal incision; saline-filled implants; scar

## 1 Introduction

Since its introduction in 1895, augmentation mammoplasty has gained widespread acceptance. The choice of breast augmentation procedure is determined almost entirely by three variables: the selection of incision location, the pocket plane for implant placement (either sub-pectoral or completely subglandular), and the appropriate implant<sup>[1]</sup>. Limited incisions are becoming an increasingly important factor in aesthetic surgery satisfaction<sup>[2]</sup>.

As plastic surgeons strive to add perfection, the search continues for the ideal technique that produces a pleasing shape with minimal or imperceptible scarring<sup>[3,4]</sup>. This report aims to describe the use of transthehal incision for the augmentation mammoplasty cases.

## 2 Materials and Methods

### 2.1 Preoperative preparation

The detailed physical parameters of the existing breast tissue should be measured to determine the proper choice of breast implant and place. Placing implants in a subglandular position may be advisable in some cases, depending on the thickness and laxity of the breast tissue,

<sup>☆</sup>Supported by Medical Emphasized and Special Subject Program of Henan Province, (No.5451) and International Cooperation Program of Zhengzhou Science Bureau (No.083SGHH33292).

\*Corresponding author. Email: pshan@kumc.or.kr



and also the ability of the breast tissue to decently cover the implant. The margins of the pocket were determined and marked while the patient was in the erect position. The planned transtheial incision was made on the inferior waist of nipple between the 9 and 3 o'clock, which was 2 mm higher than the nipple's base (Figure 1A).

## 2.2 Operation process

The augmentation mammoplasties were done under local anesthesia, or combined anesthesia: general endotracheal anesthesia uniting local anesthesia, with the patients in the supine position and the entire chest wall prepared. Approximately 200 ml 0.25% Xylocaine with 1 : 60000 epinephrine mixed local solution was injected at the nipple incision site, areola, and into or just above the pectoralis major muscle, particularly with the inferomedial portion, taking care to avoid penetration through the intercostal space.

The incision of crescent moon was made along the swollen inferior waist of the nipple by a previous local injection. If this incision was not long enough for the patients with small nipples, it could be extend using a back cut within the pigmented areolar skin bilaterally according to the thickness of the index finger of the operator, the total length is about 2 cm. Surgeons created the pocket manually or with cautery, by way of either the subglandular or subpectoral plane according to the surgeon's choice.

Twenty five patients had adequate amount of breast tissue and subcutaneous fat to cover the implant, so it was better to create the implant pocket in the subglandular. After splitting the subglandular along the direction of lactiferous ducts, a tunnel is dissected without disturbing pectoralis major muscle till the circumferential glandular pole is reached. The marginal tissue should keep being moderate for decreasing the risk of implant visibility.

Submuscular placement was chosen for five slimmer, petite patients with very small breasts, in one secondary augmentation. After carefully undermining the areolar skin with adequate thickness to prevent skin slough, the dissection continued toward the pectoralis major muscle through the subcutaneous layer, taking care not to damage the breast parenchyma. Hooks were used to elevate the wound edge (Figure 1B), and bipolar scissors were used to cut down the underlying breast tissue in the longitudinal direction. The pectoralis major muscle could be identified and split to facilitate entry into the subpectoral pocket. Blunt finger dissection was then done superiorly, medially, and laterally to create a large pocket. During this procedure, be careful not to avulse the sternal origin of the pectoralis major muscle, and ensure preservation of the anatomic continuity of the muscle. Following ade-

quate homeostasis and irrigation with a cephalothin solution, the incision was pinched and press down, in order to observe the shape of the pocket. If inadequate dissection was remained (Figure 1 C), it should be stripped again till to the good shape.

Once a suction drainage tube was placed through the axillary fold, the inflatable smooth round saline implant with diaphragm valve (Mentor Corporation, USA) was rolled up and inserted into the pocket. The implant is then inflated to the desired 200 – 300 ml saline with a closed fill system. Bilateral symmetry can be achieved by adjusting the injected saline volume in a horizontal position. To check them again in semireclining position, remnants bubble in the implant must be rule out completely by extracting and pushing the syringe a few times to make bubble updraft on the upright position (Figure 1 D).

After having adjusted the form and volume of the saline, the valve could be self-closing as soon as vessel was pulled out. The pectoralis major muscle, glandular tissues, and the subcutaneous tissues were sutured in separate planes with long-lasting absorbable sutures carefully. The skin was closed with a 5 – 0 nylon suture (Figure 1 E). Postoperative tape and a support bra were then applied for 5 days.

## 2.3 Postoperative care

Moderate doses of antibiotics were administered. Tramadol usually was given as an analgesic at the patient's request. There were no complications in the early postoperative period and the patients were discharged on the postoperative following day. The patients should be given detailed instructions about massage of breast, as soon as taking out stitches. Outpatient follow-up visits were planned with a physical examination.

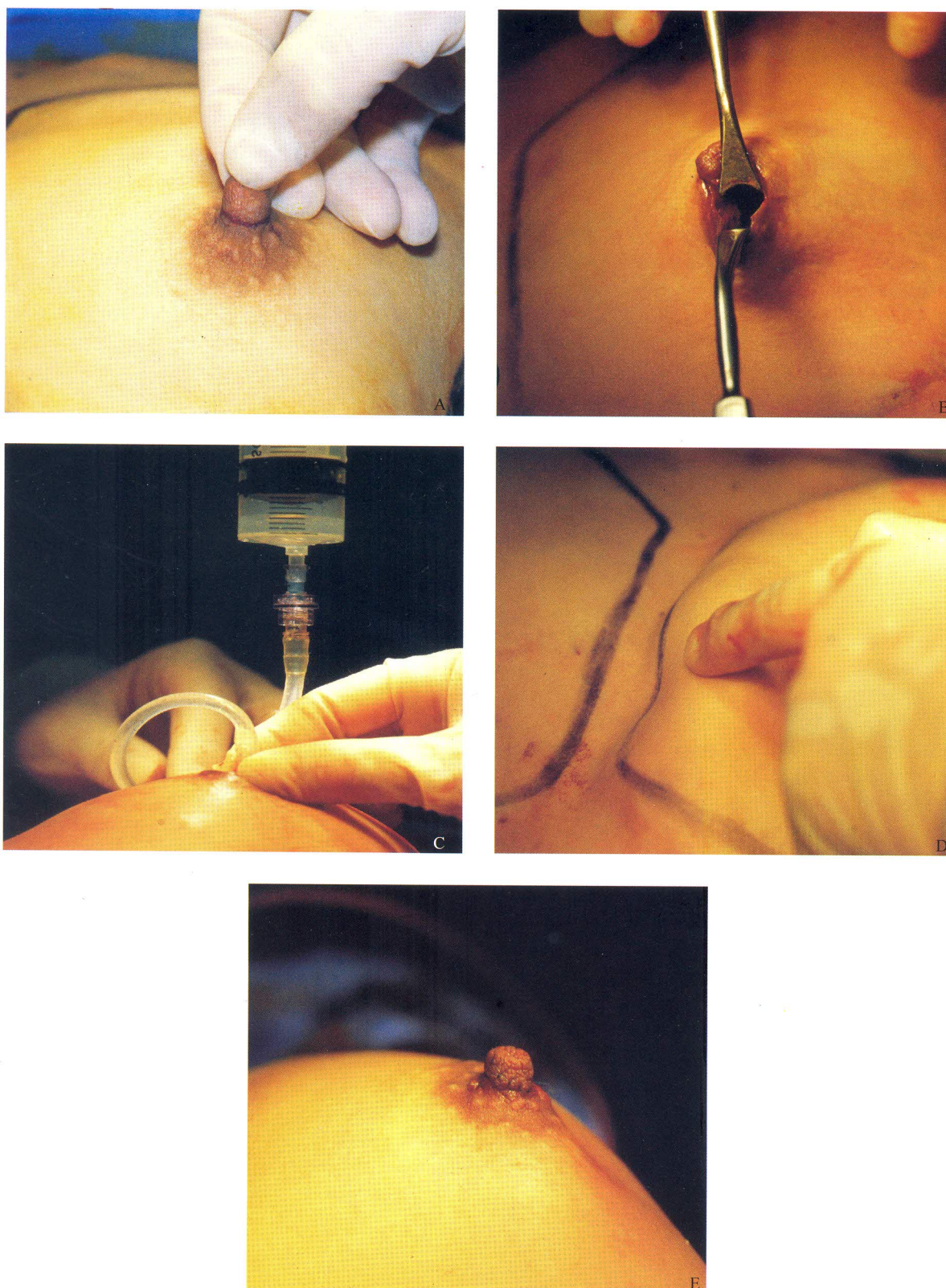
## 3 Results

All the clinic data was collected from the Plastic and Reconstruction Surgery Department, Korea University Guro Hospital.

From January 2000 to December 2007, augmentation mammoplasty using transtheial incision was performed on thirty patients. Patient age ranged from 25 to 46 years old. In all patients, smooth, round saline implants were used. In one patient who had the left rupture of silicone gel implant breast through an axillary approach, the implants were removed and reinserted through transtheial incision after adequate pocket formation. The follow-up visited time were from three months to six years.

Ten patients complained of a rippling or visible fold.





**Figure 1.** The steps of the operation. A: Transthecal incision, and extended to areola. B: The pocket was finished, and implant was ready to be put into. C: To observe and correct the shape of pocket. D: To eliminate the air of implant completely. E: To suture the incision.



There were no patients who required a partial capsulectomy through the incision again. No patients had asymmetric breasts. Five patients complained of paresthesia of the nipple or breast skin, presumably because of exposure or traction of the intercostal nerve branches in the subpectoral pocket. Transient mild decreased sensation of the nipple recovered from one to three months. There were no deformities in nipple shape. Scar color and quality were satisfactory and scar was inconspicuous in all patients (Figure 2 & Figure 3). In two patients, the implants were changed with another one using the same incision as a result of rupture of the implants.

#### 4 Discussion

Because of the ever-present patient concerns with scars, various techniques have been devised to minimize or hide the incision. The most popular surgical approaches for breast augmentation are inframammary, axillary, and periareolar. The optimal technique for breast augmentation has always been debated, and numerous variables fit the needs of the variously shaped patients in our population.

The inframammary incision represents the simplest and most straightforward approach to breast augmentation. Certain circumstances, however, require thought as to where to make the incision. In patients with significant hypoplasia that causes an ill-defined inframammary fold or with a constricted breast and a breast fold too close to the areola, placement of the incision is less obvious. In these cases, once the implant is placed, the incision may lie above the new inframammary crease and be visible on the breast, or it may be too low and be visible beneath the breast. The route became a problem as swimwear became briefer, leaving the scar exposed.

The transaxillary incision's obvious appeal is that it avoids a scar on the breast. The scar is well concealed, and like the inframammary incision, it does not violate the breast parenchyma. Despite such advantages, there are definite trade-offs to such a remote approach. When compared with the other, more direct incision options, the transaxillary incision lacks the same degree of control and accuracy, and theoretically has a higher risk of asymmetry and implant malposition. Because of this, it may have a higher revision rate. Furthermore, subsequent secondary procedures may be difficult or impossible with an axillary incision, and this may require a new incision that is located more directly on the breast. Because it would be difficult to adequately manipulate the breast parenchyma in complex cases such as the tuberous breast deformity, the transaxillary incision is also not recommended when

substantial parenchymal rearrangement is required.

The periareolar incision is one of the shortest ways to reach the subpectoral plane. One of the advantages of the periareolar approach compared with the axillary procedure is the possibility of making the pocket accurately using the index finger of the operator. During finger dissection, any tight lifting motions of the index fingers are important in preventing the later development of implant pocket disproportion. The inferomedial dissection of the pocket should be made with a blunt-tip dissector for firm attachment of the fascia.

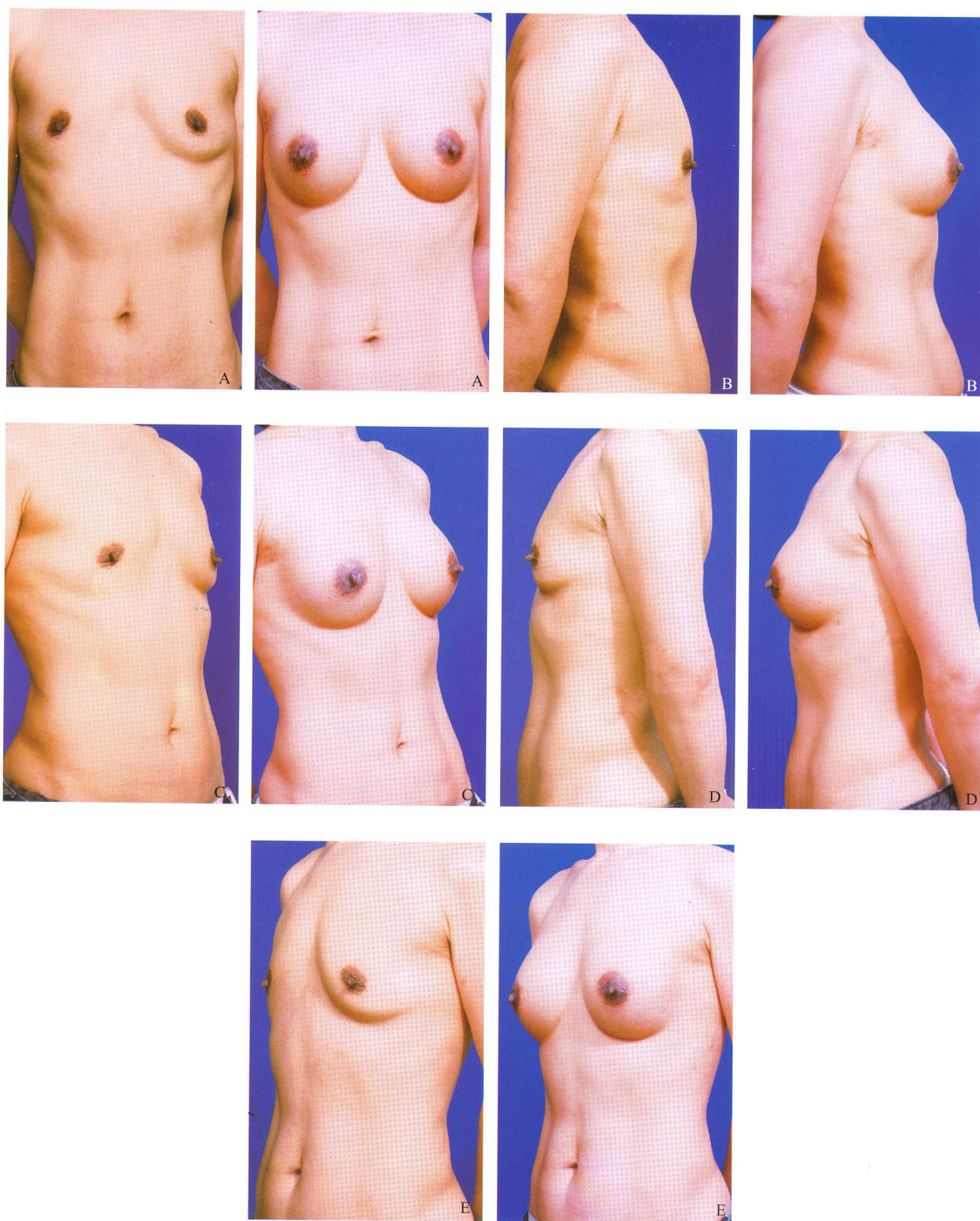
Even though the periareolar scar is rather minimal and less conspicuous to the patients who have a well-demarcated skin-areolar junction, it is more visible than the perinipple incision<sup>[5]</sup>. In many patients, the boundary between the nonpigmented skin and the pigmented areola is usually not sharply demarcated and is rarely a perfect circle. It, therefore, is impossible to make an incision exactly along the junction of the pigmented areola and the nonpigmented skin. In addition, the periareolar scar tends to widen or become hypertrophic with age, which depends on internal expansion by the implant, external massage, skin quality, and gravity. If some patients have stria on the breast or abdominal skin, the periareolar scar could widened and be more visible later. This could be a serious drawback to Asians who have thick and more pigmented skin.

Among other approaches, the transareolar incision has not gained widespread popularity despite the fact that it was published on almost three decades ago<sup>[6]</sup>. Many surgeons fear that this incision may impair lactation, increase the rate of infection and/or capsular contracture, leave a visible scar associated with hypopigmentation, and require additional access in cases of future breast ptosis correction<sup>[7]</sup>. However, a recent study did not conclusively answer the question about the possibility of compromised lactation<sup>[8]</sup>. Breast sensitivity after augmentation is another controversial aspect and a recent study was not conclusive<sup>[9]</sup>. The possibility of impairment of nipple sensation is a reason for not use the transareolar incision, even though some studies have shown that the innervation comes from the anterior branch of the fourth lateral intercostal nerve, passing deeply through the breast tissue, in a subcutaneous plane<sup>[10]</sup>.

The transtheial incision, with a vertical course toward the pectoralis major muscle, would theoretically be of great benefit in sparing many of the tiny nerve branches<sup>[11,12]</sup>. Moreover, the transtheial approach for breast augmentation does not seem to have an increased rate of complications, including capsular contraction<sup>[13]</sup>.

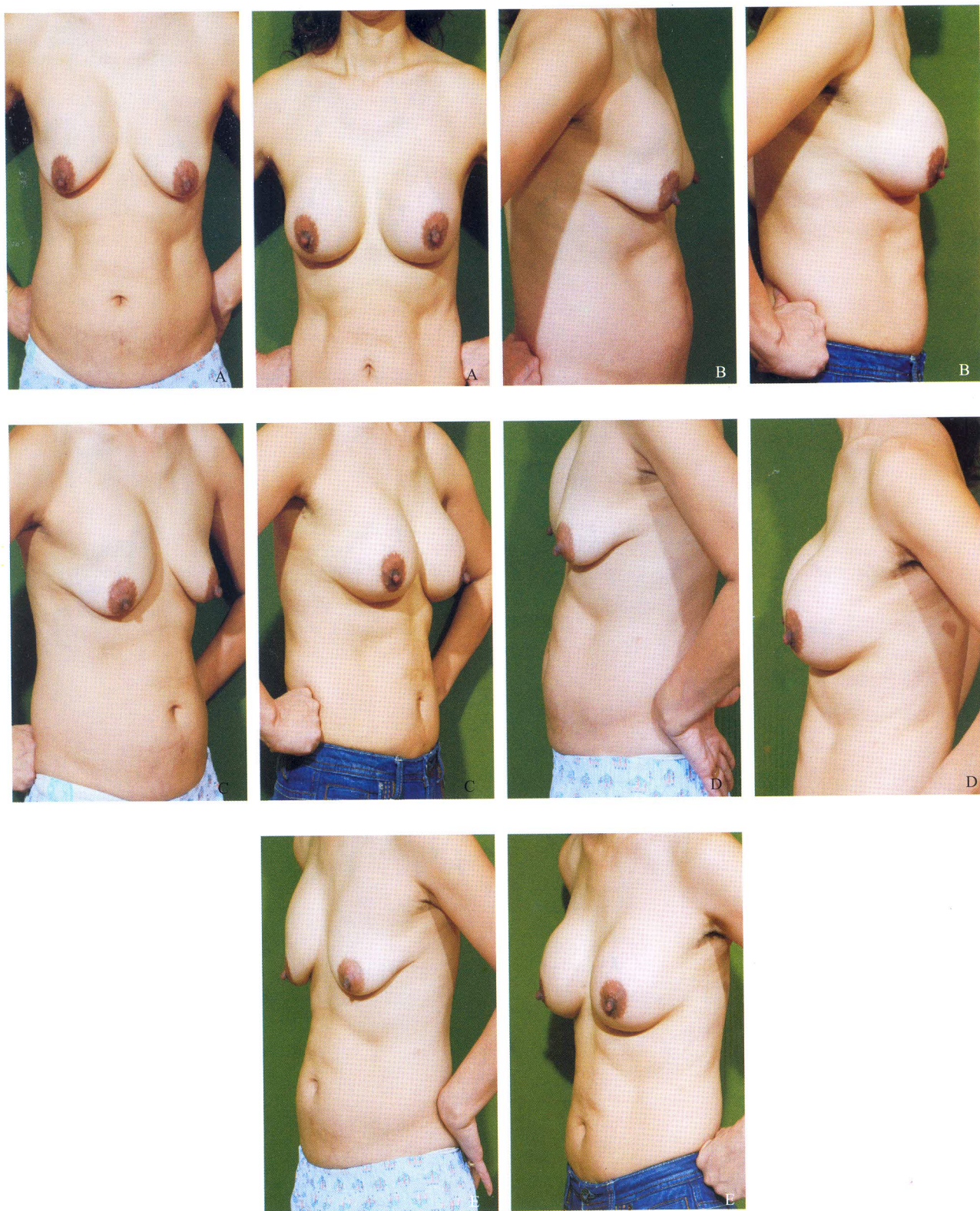
The ideal scar should be flat, narrow, and level with the surrounding skin, have good color match, and be within or





**Figure 2.** Case 1 Pre-and 1-year postoperative views after implantation. A: Frontal view; B: Right lateral view; C: Right three quarter lateral view; D: Left lateral view; E: Left three quarter lateral view.





**Figure 3.** Case 2 with fracture of left silicone gel implant, pre-and 1-year postoperative views after implantation. A: Frontal view; B: Right lateral view; C: Right three quarter lateral view; D: Left lateral view; E: Left three quarter lateral view.



parallel to relaxed skin tension lines. These characteristics make a scar less conspicuous. Therefore, the transtheial incision make the line of the scar greater camouflage.

With this transtheial incision, blunt finger was easy to dissect to all the direction of the pocket, and only produced minimally invasion. Because of small incision, it is very easy to seal up the incision with pinching and observe the shape of the pocket.

Because of the saline implant with diaphragm valve, we can use minimal incision to insert the rolled implant before injecting saline. After putting the syringe on the upright position, remnants bubble in the implant becomes easy to be rule out completely.

Better incision quality helps the patient more easily accept the surgical outcome. To date, this technique can be used unceasingly.

## 5 Conclusion

The transtheial incision, shows less visible scarring in patients with moderate-size nipple and provides a similar operative field and with better soft tissue care, and technically convenient for the surgeon.

## References

1. Spear SL, Bulan EJ, Venturi ML. Breast augmentation. *Plast Reconstr Surg* 2004; 114(5): 73e – 81e.
2. Atiyeh BS, Al-Amm CA, El-Musa KA. The transeintra-areolar infra-nipple incision for augmentation mammoplasty. *Aesthetic Plastic Surgery* 2002; 26(2): 151 – 5.
3. Gryskiewicz JM, Hatfield AS. "Zigzag" wavy-line periaerolar incision. *Plast Reconstr Surg* 2002; 110(7): 1778 – 84.
4. Jenny C, Alberto E. Alternative technique for breast augmentation in patients with a small nipple-areolar complex diameter. *Aesthetic Plast Surg* 2005; 25(2): 117 – 25.
5. AylinBK, Hulya A, Fatih S, *et al.* Augmentation mammoplasty by medial periareolar incision. *Aesth Plast Surg* 2002; 26: 291 – 4.
6. Jones FR, Tauras AP. A periareolar incision for augmentation mammoplasty. *Plast Reconstr Surg* 1973; 51: 641 – 4.
7. Carvajal J, Echeverry A. Alternative technique for breast augmentation in patients with a small nipple-areolar complex diameter. *Aesth Plast Surg* 2005; 25(2): 117 – 25.
8. Tenius FP, da Silva Freitas R, Closs Ono MC. Transareolar incision with geometric broken line for breast augmentation: a novel approach. *Aesth Plast Surg* 2008; 32: 546 – 8.
9. Pitanguy I, Michel V, Radwanski HN, *et al.* Relative implant volume and sensibility alterations after breast augmentation. *Aesth Plast Surg* 2007; 31: 238 – 43.
10. Sarhadi NS, Shaw Dunn J, Lee FD, Soutar DS. An anatomical study of the nerve supply of the breast, including the nipple and areola. *Br J Plast Surg* 1996; 49(3): 156 – 64.
11. Banbury J, Yetmand R, Lucas A, *et al.* Prospective analysis of the outcome of subpectoral breast augmentation: sensory changes, muscle function, and body image. *Plast Reconstr Surg* 2004; 113(2): 701 – 7.
12. Richard AB. Nipple or areolar reduction with simultaneous breast augmentation. *Plast Reconstr Surg* 2003; 112(7): 1918 – 21.
13. Kompatscher P, Schuler C, Beer GM. The transareolar incision for breast augmentation revisited. *Aesthetic Plast Surg* 2004; 28(2): 70 – 4.