

Complementation of magnetic resonance spectroscopy (MRS) and histopathology in diagnosing focal brain lesions.

Mohamed Hasan Mansour¹, Hamdy Behairy¹, Mustafa Alwalilyi¹, Hatem Elkhole¹, Mohamed Shaban¹, Islam Alaghory¹, Mohammad Abdel-Azem² and Ola Ahmad Bahgat³

Neurosurgery¹, Histopathology² and Radiology³ Departments, Faculty of Medicine, Al- Azhar University, Egypt.

E. mail: neuro_m52@yahoo.com

Abstract: Introduction: In spite of recent advances in the used preoperative diagnostic tools, there is no single accurate diagnostic one and none of them had hundred per cent accuracy. So, misdiagnosis still occurs. Many trials were done to evaluate the accuracy of these tools individually or in combination. **Patients and Methods:** This study was conducted over the last three years in Al-Azhar university hospitals (Neurosurgery, radiology and histopathology departments) on 51 patients out of total 100 patients suffering from focal brain lesions as diagnosed by CT and/or MRI brain. All of them were requested for MRS before planning for biopsy and histopathology. Fifty patients of them were operated for biopsy and histopathology either by minimal invasive (stereotaxy) or invasive open craniotomy Mean age was 54 years; female/male ratio was 2/3. The most frequent symptom was headache. The decision to operate was made if still no accurate final diagnosis and/or progressive deficits. **Results:** MRS was supporting to biopsy in 45 cases, while biopsy was mandatory after MRS in 5 cases and MRS was beneficial in avoiding unnecessary biopsy in 2 cases. **Conclusion:** Both MRS and histopathology are complementary in diagnosing focal brain lesions. MRS must be ordered before biopsy and must be included in any tumor grading. [Mohamed Hasan , Hamdy Behairy, Mustafa Alwalilyi, Hatem Elkhole, Mohamed Shaban, Islam Alaghory, Mohammad Abdel-Azem and Ola Ahmad Bahgat. **Complementation of magnetic resonance spectroscopy (MRS) and histopathology in diagnosing focal brain lesions.** *Life Sci J* 2014;11(12):891-899]. (ISSN:1097-8135). <http://www.lifesciencesite.com>. 157

Keyword: Focal brain lesions- MRS- biopsy -histopathology.

1. Introduction

Diagnosis is the key for treatment plan. Some fundamental tasks for accurate diagnosis include: (1) Anatomic localization of the lesion and its relation to surrounding structures which could be determined by CT and /or MRI brain. (2) Evaluation of the activity of this lesion (hyperactive, normal, or silent) by magnetic resonance spectroscopy (MRS)(3) Determining cell of origin of the lesion through tissue sampling which is the gold standard for diagnosing the type of cellular elements of the lesions but taking in consideration that partial excision of tumor tissue may change the behavior of the tumor. Other fundamental tasks like the clinical condition either local or general cannot be neglected. When a patient comes for the evaluation of a focal brain lesion, it is often difficult to differentiate between tumoral and non-tumoral brain lesions and frequently creates a dilemma for physicians and surgeons for further management.

The current gold standard characterization of a brain tumor is by histopathological analysis. (Louis *et al.*, 2007)

Histopathological analysis is the standard procedure routinely used to reveal the amount of necrosis, proliferative regions, collagen and vascularity within the tumor area (Manoranjana and Provias, 2011).

The introduction of MRS has directed the attention of neurosurgeon to use it as a non invasive tool to raise the preoperative diagnostic accuracy, which may obviate the necessity for open surgery especially at eloquent parts. Magnetic Resonance Spectroscopy (MR Spectroscopy) is one of the tools used to determine the molecular structures of compounds or to detect the compound presence. MR Spectroscopy provides metabolic information from living brain. The major brain metabolites detected are choline, creatine, N-acetyl aspartate (NAA), lactate, myo-inositol, glutamine, glutamate, lipids and the amino acids leucine and alanine (Bulakbasi *et al.*, 2003). This is the substrate of MRS, So that Magnetic Resonance spectroscopy brain lesions show abnormal values of these metabolites as compared to normal tissue. (MRS) is non-invasive sensitive, however, relatively nonspecific modality in differentiating neoplastic and non-neoplastic brain lesions (Alam *et al.*, 2011).

There is strong evidence for a reduction in N-acetylaspartate and increase in choline containing compounds in tumor relative to normal brain parenchyma. Also, for some metastatic lesions and for high-grade gliomas, typically, there are resonances corresponding to lactate or lipids (Sarah *et al.*, 2003).

MR Spectroscopy is a potential tool for differentiating neoplastic from non-neoplastic brain lesions (Butzen *et al.*, 2000). So that the goal of this study is to describe the role of Magnetic Resonance spectroscopy (MRS) among other diagnostic tasks for focal brain lesions and its relationship to histopathology.

2. Patients and methods

The study was conducted in departments of Radiology, Neurosurgery and Histopathology Al-Azhar university hospitals, Cairo, Egypt, from May 2011 till march 2014 and included 100 patients with focal brain lesions as shown by CT and /or MRI brain. Clinical evaluation included a detailed history and physical examination.

The following procedures were used routinely for the diagnosis:

1. Clinical evaluation: general and neurological examination after detailed clinical history for all patients. Weakness was the Most common clinical presentation (30%) followed by headache (24%).

2. Anatomic studies (CT and /or MRI brain): for one hundred patients suffering from neurological deficit , CT brain and MRI brain was done to pick up any lesions and to determine its anatomic location with comparison of the sensitivity and specificity of both .

3. Biological studies to evaluate the activity of the lesion by MRS: only for fifty two patients to evaluate the metabolites of brain tissue.

4. Histopathological studies: To evaluate the morphological changes of tissues, with comparison of diagnostic accuracy of MRS and histopathology.

5. Follow up of the patients to evaluate the diagnostic modality: the final diagnosis may be changed by therapeutic diagnosis (only in one case).

All the patients found to have focal brain lesions on conventional MRI sequences were included in the study. MR Spectroscopy (through single voxel technique) was performed in all these patients after informed consent. Initially, post contrast conventional MR imaging was done to localize the lesion and then voxel was placed on volume of interest. After water suppression, a point-resolved spectroscopy (PRESS) technique was used for localization and the studies were obtained with parameters including TE and TR of 135 and 1500 respectively.

Exclusion criteria for biopsy: Eloquent areas, absence of mass effect, absence of surrounding edema, hypometabolic MRS and regressing lesions in follow up radiology.

On the basis of MRS findings, lesions were categorized into neoplastic and non-neoplastic lesions. The spectra were analyzed for the signal

intensity of NAA, choline, and creatine and for the presence of lipid and lactate peak. Ratios were manually calculated for Cho/Cr, and Cho/NAA ratio. NAA is a marker of neuronal integrity and peaks at 2.02 ppm. Choline is an indicator of cell turnover and peaks at 3.22 ppm. Similarly, creatine is involved in cell metabolism and peaks at 3 ppm. Lipid and lactate peak are normally absent in brain tissue and when present peak at 1.33 ppm and may overlap each other. Neoplastic lesions have elevated choline and reduced NAA peaks on MR spectrum with increase choline /creatine and choline/ NAA ratios. Reduced Cho, Cr and NAA peaks on MR spectrum are suggestive of non-neoplastic lesions. Cho/creatine and choline/NAA ratio are usually not altered in non-neoplastic lesions. Lipid and lactate peak can be seen in high grade tumours and also in infectious lesions. Lesion was also evaluated on conventional MR sequences before making the final MRS diagnosis. In this study tissue sampling was read by 2 different histopathologists. Data was entered using Statistical Package of Social Sciences (SPSS) programme version 16.0. Percent agreement between spectroscopy and histopathology for focal brain lesion in differentiating from neoplastic and non-neoplastic lesion was calculated by using kappa statistic. P value less than 0.05 was considered as significant. Sensitivity, Specificity, positive, negative predictive value and accuracy of MR Spectroscopy was calculated. Comparisons of mean value of neoplastic and non-neoplastic lesions were done by using t-test.

3. Results

There were 28 (28/52) male patients while 24 (24/52) were females. The mean age was 40 ± 18 years with a range from 4 to 76 years. For males, age range was 6-76 years with mean age 41 ± 16 years while in females it ranged from 4 to 67 years with a mean age of 34 ± 22 years.

Regarding the all one hundred cases, the CT brain was negative in 2 cases (one case of infarction and another case of glioma as confirmed by MRI), and was false in one case (false regarding the location and nature of the pathology). Regarding the fifty two cases in Whom MRS was done, one case was read by magnetic resonance spectroscopy as infarction at mid brain with improvement of the clinical condition of the patient, so that histopathology was avoided in this case. Another one was read by MRS as benign lesion at the tectum of mid brain with hydrocephalic changes so only ventriculoperitoneal shunt was done with follow up of the patient regularly. So that the comparative study was done among 50 cases only out of the fifty two with exclusion of these two cases. Fourty nine cases out of the 50 cases, were read easily by MRS (45 as neoplastic lesions and 4 as non

neoplastic lesions), while one case(1/50) was reported as difficult diagnosis between infection or high grade glioma where stereotactic aspiration of the lesion and histopathology confirmed to be pyogenic brain abscess and follow up proved clinical improvement of the patient. The histopathology was

not coinciding with the MRS findings in 2 cases. The histopathologically proved neoplastic lesions (n=45) included 'anaplastic astrocytoma (n=33), lymphoma (n =3), anaplastic ependymoma (n = 2), oligodendroglioma (n =3), and neuroectodermal tumours (n = 4).

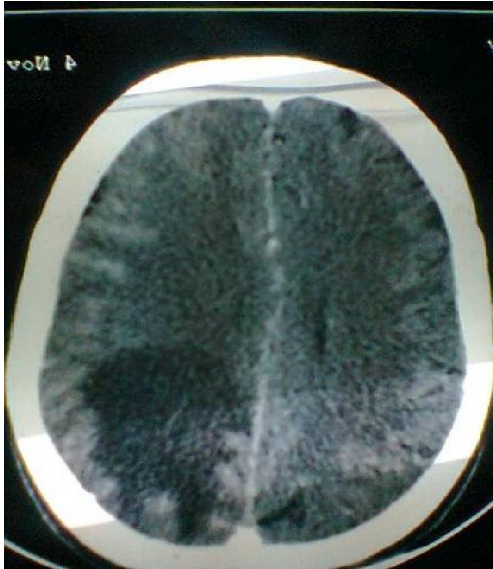

Figure 1 (a):CT with contrast: left parieto occipital deeply seated lesion

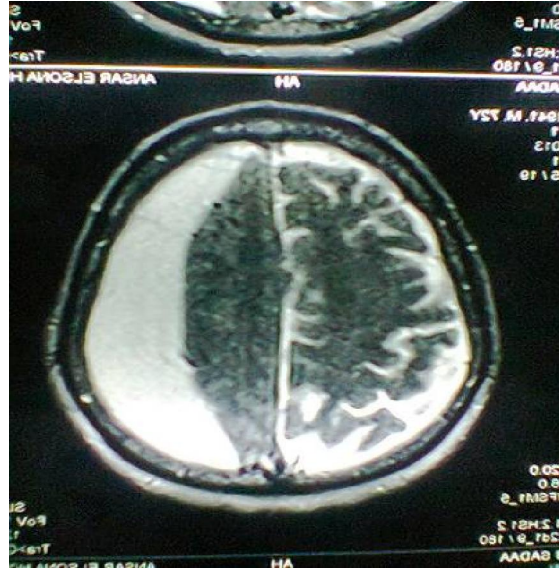


Figure 1(b): MRI OF THE SAME PATIENT :ch. subdural hematoma

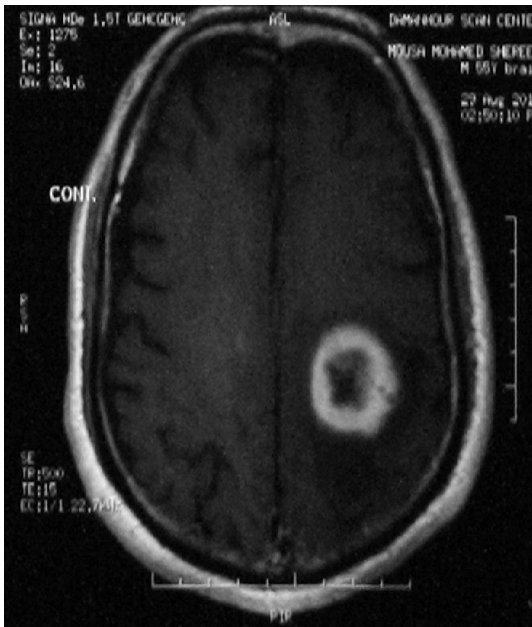


Figure 2 (a):MRS: infection.Histopathology : Astrocytoma grade II

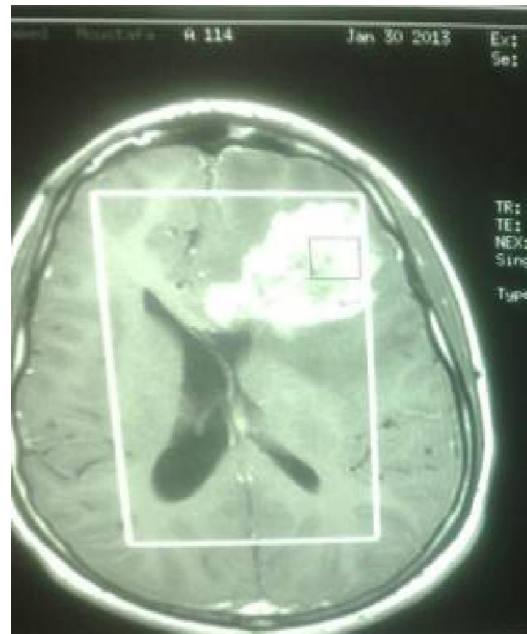

Figure 3 (a) :MRS : tumor Histopathology.: fungal infection

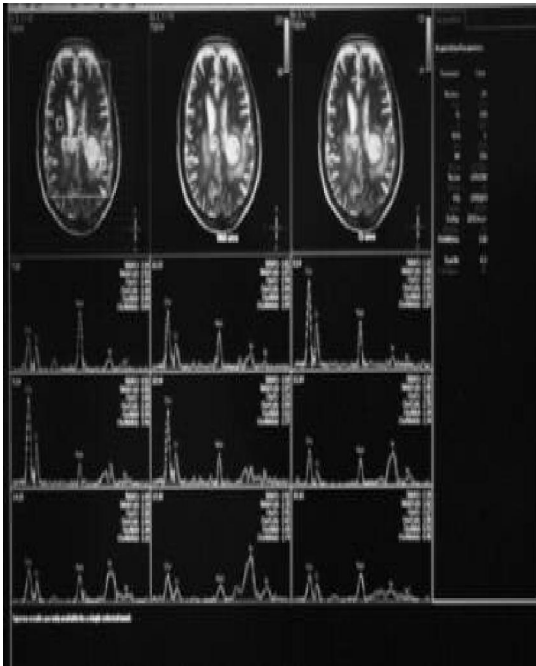


Figure 2 (b) MRS: infection

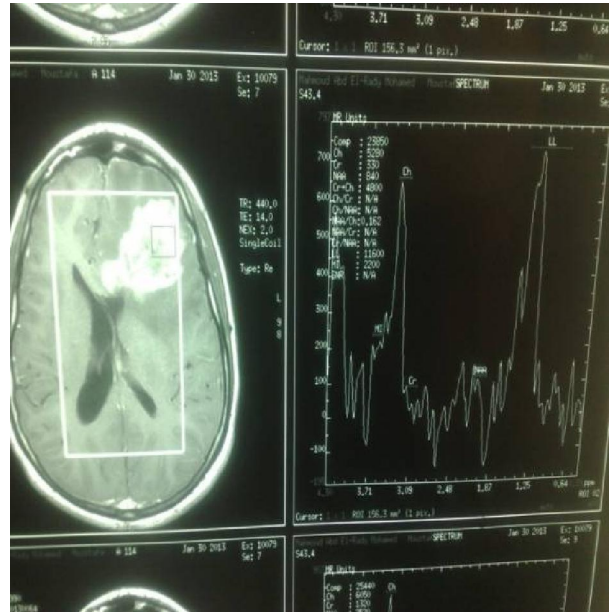


Figure 3 (b) :MRS : tumor

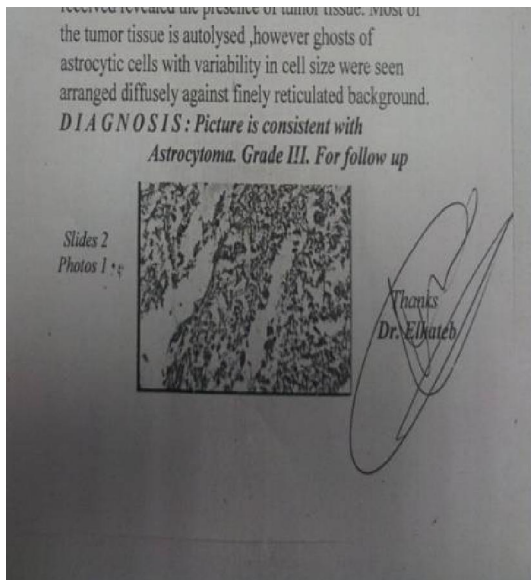


Figure 2 (c) :histopathology showing astrocytoma grade 3.

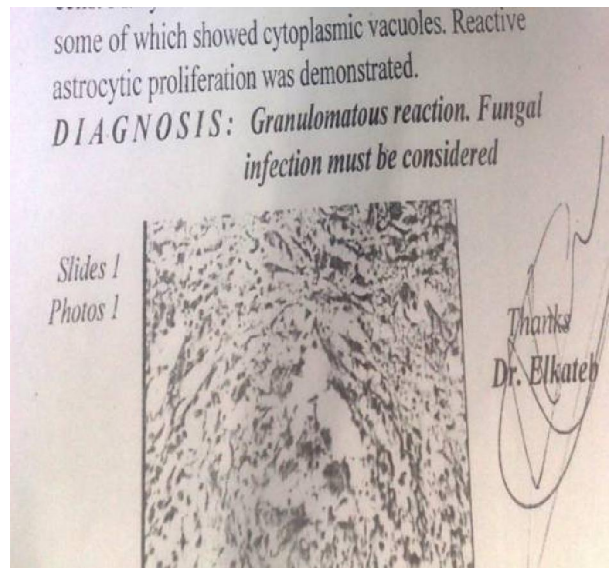


Figure 3 (c) : histopathology showing infection in spite of being hyperactive by MRS.

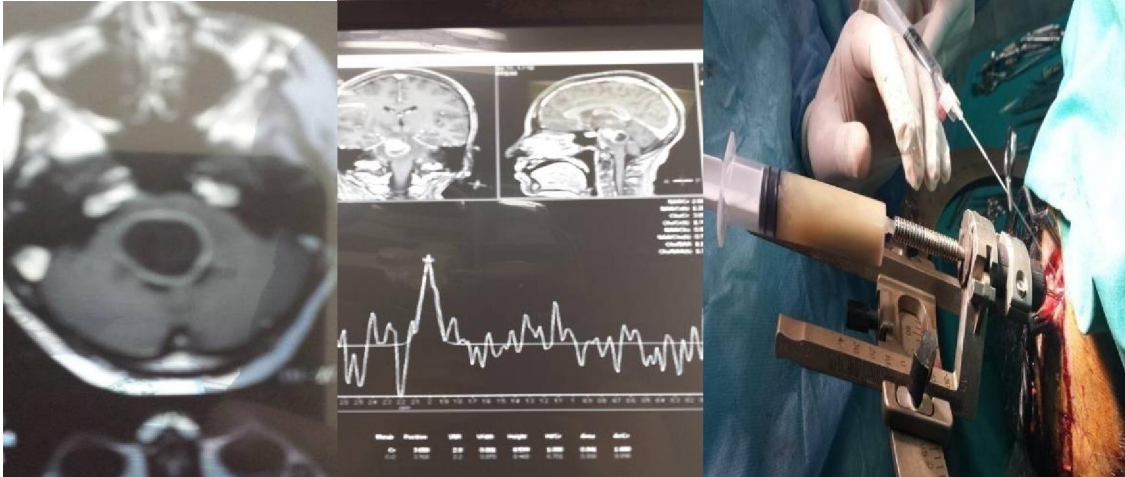


Figure 5 a , b and c : (a)Brain stem cystic lesion of female patient 40 years old with disturbed conscious level . (b) MRS: showing ? glioma or infection without definite diagnosis. (c)Stereotactic biopsy :evacuation of 30 cc of pure pus with improvement of the patient on table.

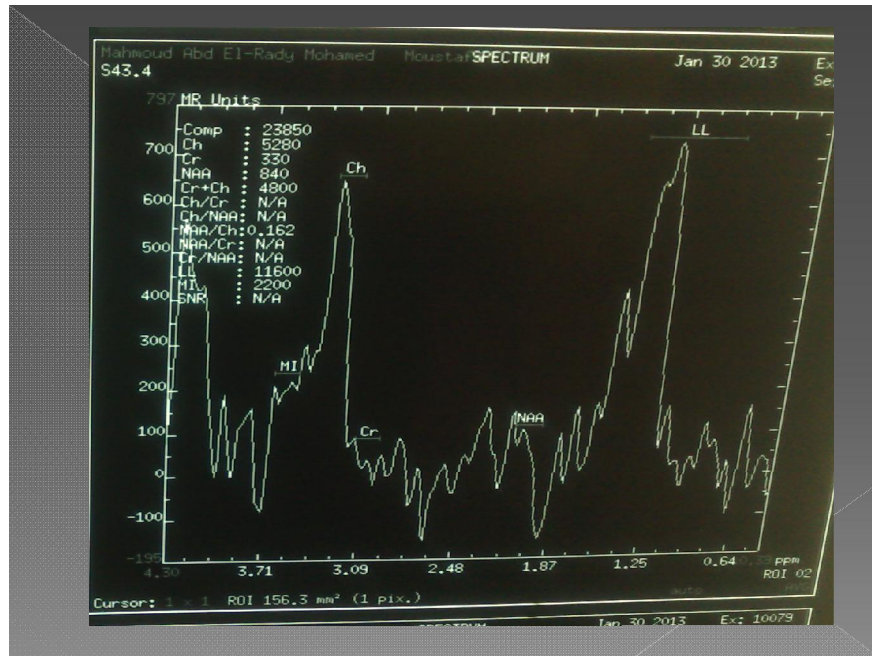


Figure 6: key of reading MRS = PATHOLOGIC SPECTRA OF MRS =NAA / Choline which may be less than 1/2 (hyperactive lesion) ,or more than 1/2 (hypoactive lesion).

The histologically non-neoplastic cases (n=5) included granulomatous infection (n = 2), chronic haematoma (n = 1), bacterial abscess (n=1) and fungal infection (n=1). 2 cases had different histopathologic diagnosis from that obtained by MRS. One case was read by different histopathologic results,(infarction versus glioma?). Increase Cho/Cr (5.38 ± 6.10) and Cho/NAA (11.33 ± 16.3) ratio were observed in neoplastic lesions as compared to non-neoplastic lesions (Cho/Cr = 2.85 ± 2.47) (Cho/NAA = 3.15 ± 2.67) in this study with significant p-value

of 0.005. Similarly, significant increased Choline value (2.51 ± 1.8) mmol/l was noted in neoplastic lesions compared to (1.41 ± 0.73) mmol/l in non-neoplastic lesions with p-value of 0.000. Mean NAA value in neoplastic lesion was (0.45 ± 0.35) mmol/l compared to (0.60 ± 0.29) mmol/l in non-neoplastic lesions with p-value of 0.000. The mean Cr value in neoplastic lesion was (0.73 ± 0.64) mmol/l compared to (0.65 ± 0.44) mmol/l in non-neoplastic lesions with significant p-value of 0.001.

Spectrum was also observed for presence or absence of lactate/lipid peak. Regarding lactate and lipid peak, lipid/lactate peak were observed in 26 spectrums. Of these 18 (41.86%) were noted in 43 neoplastic lesions and 8 (80%) in 10 non-neoplastic lesions. Thus there were 40 true positive, 3 false positive, 7 true negative and 3 false negative results reported on MRS based assessment of likely neoplastic brain lesions. Based on these findings, MR Spectroscopy has a sensitivity of 93.02%, specificity of 70%, positive predictive value of 93.02%, and negative predictive value of 70% and diagnostic accuracy of 88.67%. After calculating the percent agreement by chance alone, kappa statistics was applied which showed a good agreement between MR Spectroscopy and histopathology for differentiating neoplastic and non-neoplastic lesions [$k=0.630$, p -value, <0.001].

4. Discussion

In spite of advances in preoperative diagnostic tools, misdiagnosis still occurs, so that seeking for more preoperative diagnostic tools are needed and we can postulate that: diagnostic tools are complementary, because fundamental tasks for accurate diagnosis are, anatomic localisation of the lesion and relation to surrounding structures, the activity of the lesion (either hyperactive, normal, or silent) and cell of origin of the lesion. The anatomic location of the lesion and relation to surrounding structures may be determined by CT and/or MRI brain, while the activity of the lesion may be determined by MRS of brain, but tissue sampling is still the gold standard for diagnosing the type of cellular elements of the lesions. So we can say that all of these diagnostic tools are complementary.

Regarding the accuracy of CT in diagnosing focal brain lesions: it was accurate in picking up the location of the lesions in 98% of cases, while the lesion was missed in 2% of cases. Among the picked up lesion, one was pseudopositive regarding the location of the lesion and nature of the pathology (see figure 1), which may be explained by the massive venous engorgement by the mass effect exerted by chronic subdural haematoma leading to localised oedema according to the compressed vein, this explanation is nearly similar to that explanation of pseudolesion of the noncirrhotic liver which is due to transient extrinsic compression, typically caused by ribs or the diaphragm, and that due to a "third inflow" of blood from other than the usual hepatic arterial and portal venous sources (Yoshimitsu K1 *et al.*, 2001).

Regarding CT pseudolesions: Intracranial pseudolesions are diagnostic pitfalls that sometimes confuse young radiologists and might deceive experienced radiologists alike. There are two types of

intracranial pseudolesions: (1) CT or MRI artifact mimicking a true lesion. (2) Intracranial disease or condition mimicking a different one (Scozzafava J, 2008) and (Wen PY, *et al.*, 2010).

In this study MRI was accurate in picking up the anatomic location of the lesions in 100% of cases, so that MRI brain is more accurate than CT in diagnosing anatomic location of the lesion. We must keep in mind, Conventional MR imaging is a useful tool in the evaluation of tumoral and non-tumoral brain lesions but not really sufficient for diagnosing all conditions (Hourani R., *et al.*, 2008). MRI was superior in two directions (1) some lesions may be not detected by CT and only can be detected by MRI especially posterior fossa lesions or early infarction. (2) CT may give false localization of some lesions. MRS does not replace conventional MRI but complements it. When augmented with a comprehensive patient evaluation including clinical history and imaging studies MRS is able to detect abnormalities that are invisible to MRI because metabolic abnormalities often precede structural changes. It also provides additional information as a prognostic factor while following the progression of the disease and evaluating the response to treatment (Hourani *et al.*, 2008).

CT and MRI are sensitive tools for categorizing brain lesion, but they cannot always distinguish between neoplastic and non-neoplastic brain lesions while MR Spectroscopy can help in differentiating neoplastic from non-neoplastic lesions. (Majos *et al.*, 2009).

Regarding the pathologic spectra of MRS: Adamson *et al.*, 2009 stated that, Cho/NAA ratio greater than 1 was considered to be positive for neoplasms, while Mcknight *et al.*, 2010 demonstrated that the sensitivity and specificity of Cho/NAA ratio greater than 2.0 (=NAA/Cho ratio less than 1/2) was 965% and 70% respectively and ratios greater than 2.5 the sensitivity to detect tumors dropped to 90% but specificity increased to 86%. Although elevated Cho and reduced NAA are found in tumors, these characteristic must be used cautiously as other lesions may exhibit similar features. Non-neoplastic lesions that may have tumor-like spectra include inflammation, stroke, multiple sclerosis, radiation necrosis and gliosis (Ross and Michaelis, 2009, Cecil and Jones, 2011; Saindane *et al.*, 2012). So that the accuracy of MRS in differentiating neoplastic from nonneoplastic focal lesions is a matter of debate as found also in our study as we demonstrated some cases with misdiagnosis (Figures 2,3

and others without definite diagnosis (see figure 5). but the definite finding or The key of reading MRS is NAA/Choline, which may be less

than ½ (hyperactive lesion) or more than ½ (hypoactive lesion) as reported by **Majos et al., 2009**. Keeping in mind the spectral pattern of low – grade neoplasms may be similar to that of normal Parenchyma as reported by **Lazareff et al., 2009**, and **Hwang et al., 2010**). MRS is relatively nonspecific modality in differentiating neoplastic and non-neoplastic brain lesions (**Alam et al., 2011**).

So that we can postulate that: MRS is good in differentiating lesions into hyperactive ,normal ,or hypoactive lesions according to NAA/Cho ratio. and this theory is important for surgeons especially in dealing with lesion at eloquent areas (see figure 4). MRS cannot decide the origin of tumor , it only gives hints about the nature of some metabolites denoting hyperactivity or hypoactivity of tumor cells so we can classify lesions spectroscopically into hot (hyperactive) or silent (hypoactive) .

While the histopathology is Considered the gold standard for diagnosing any lesion, there are 2 problems; the first is the site of the biopsy which may be differ from the center to the periphery or outside the lesion(sampling errors). The second is different pathologists reading . to overcome sampling errors ,multivoxel MRS has been used successfully to guide stereotactic biopsy ,with sampling of higher choline areas, hence greater tumor activity , which is the ideal site for biopsy . if performed in the site where the Chho/NAAs maximum , the biopsy will show high tumor infiltration yielding a high success rate and increased diagnostic confidence as reported by **Martin et al., 2010**. So supporting the postulation of complementation of diagnostic tools.

Despite worldwide efforts to standardize tumor evaluation criteria, the morphological classification of some human brain tumors is subject to interpretation. This uncertainty comes, among others, from the intra and inter-biopsy morphological heterogeneity of tumor tissue. In addition, the descriptive nature of morphology-based histopathology raises some discrepancies among experts. (**Manoranjan and Provias 2011**)

Due to the previous common problems of histopathologic diagnosis ,we recommend to modify WHO classification of tumors especially gliomas to involve spectroscopic activity of the lesion beside histopathologic grading . Hopping for more advances in diagnostic tools in future ,to be similar to finger print for each pathology .

References

1. Louis et al.,2007: Louis DN, Ohgaki H, Wiestler OD, Cavenee WK, Burger PC, et al., The 2007 WHO classification of tumours of the central nervous system. Acta Neuropathol., 2007;114:97–109.
2. Manoranjan and Provias 2011: Manoranjan B, Provias JP. Congenital brain tumors: diagnostic pitfalls and therapeutic interventions. J Child Neurol. 2011;26:599–614.
3. Bulakbasi et al., 2003: Bulakbasi N, Kocaoglu M, Ors F, Taytun C, Ucoz T. Combination of single- voxel proton MR spectroscopy and apparent diffusion coefficient calculation in the evaluation of common brain tumors. AJNR Am J Neuroradiol., 2003; 24: 225-33.
4. Alam et al., 2011: Alam MS, Sajjad Z, Hafeez S, Akhter W. Magnetic resonance spectroscopy in focal brain lesions, J Pak Med Assoc. 2011 Jun;61(6):540-3.
5. Sarah et al., 2003: Sarah j, nelson and Multivoxel (2003): Magnetic Resonance Spectroscopy of Brain Tumors, Mol Cancer Ther May 2; 497.
6. Butzen J et al., 2000: Butzen J, Prost R, Chetty V, Donahue K, Neppi R, Bowen W, et al. Discrimination between neoplastic and non-neoplastic brain lesions by use of Proton MR spectroscopy: the limits of accuracy with a logistic regression model. AJNR Am J Neuroradiol 2000; 21: 1213-9.
7. Yoshimitsu K1 et al 2001: Yoshimitsu K1, Honda H, Kuroiwa T, Irie H, Aibe H, Shinozaki K, Masuda K. Unusual hemodynamics and pseudolesions of the noncirrhotic liver at CT., Apr 10;28(11):1963-72. Radiographics. 2001 Oct; 21 Spec No: S81-96.
8. Scozzafava J,2008: Scozzafava J, Johnson ES, Blevins G. Neurological picture. Demyelinating butterfly pseudo-glioma.J Neurol Neurosurg Psychiatry. 2008 Jan;79(1):12-3.
9. Wen PY, et al , 2010: Wen PY, Macdonald DR, Reardon DA, Cloughesy TF, Sorensen AG, Galanis E, Degrout J, Wick W, Gilbert MR, Lassman AB, Tsien C, Mikkelsen T, Wong ET, Chamberlain MC, Stupp R, Lamborn KR, Vogelbaum MA, van den Bent MJ, Chang SM. Updated response assessment criteria for high-grade gliomas: response assessment in neuro-oncology working group. J Clin Oncol. 2010 .
10. Hourani R., et al ,2008: Hourani R., Brant L.J., Rizk T.,Weingart J.D., Barker P.B., Horska A., et al.,: Can Proton MR Spectroscopic and Perfusion imaging differentiate between neoplastic and non-neoplastic brain lesions in adults? AJNR 2008, 29: 366-372.
11. Majos et al., 2009: Majos C, Aguilera C, Alonso J, Julia Sape M, Castener S, Sanchez JJ. Proton MR spectroscopy improves discrimination between tumor and pseudotumoral lesion in solid brain masses. AJNR Am J Neuroradiol 2009; 30: 544-51.

12. Adamson et al ., 2009:Adamson AJ, Rand SD, Prost RW, *et al.*, 2009 ; focal brain lesions: effect of single voxel proton MR spectroscopic findings on treatment decisions . *Radiology* 209; 73-78.
13. Mcknight et al., 2010 : Mcknight TR, Von Dem Bussche MH, Vigneron DB, *et al.*, 2010:correlation of 3D ERM imaging tumor index with histology in patients with newly diagnosed gliomas .*AJNR*.22 :959-968.
14. Ross and Michaelis , 2009: Ross and Michaelis T , 2009: clinical applications of magnetic resonance spectroscopy . *Mag. Reson.Q*.10:191-247.
15. Cecil and Jones ,2011: Cecil KM and Jones BV. 2011: Magnetic resonance spectroscopy of the pediatric brain . *Top. Magn. Reson. Imag.* 12 ; 435-452.
16. Saindane et al.,2012: Saindane AM , Cha S, Law M, *et al.*,2012: Proton MR spectroscopy of tumefactive demyelinating lesions . *Am. J. neuroradiol.* 23:1378-1368.
17. Lazareff et al 2009: Lazareff JA, Olmstead C, Bochorst K H *et al.*, 2009: Proton magnetic resonance spectroscopic imaging of pediatric lowgrade astrocytoma . *Childs Nerv Syst.* 12 (3):130-135.
18. Hwang et al ., 2010: Hwang Egnaczyk GF, Ballard E et al ., 2010: proton MR spectroscopic characteristics of pediatric pilocytic astrocytomas. *AJNR*. 19: 335-540.
19. Martin et al .,2010: Martin AJ, Liu H, Hall Wa ,Truwit CL (2010) correlation of 3D ERM imaging tumor index with histopathology in patients with newly diagnosed gliomas. *AJNR*. 22:959-968.

12/13/2014