

**Evaluation of the Outcome of Transobturator Vaginal Tape in Management of Stress Incontinence in Women**

H.S. Mohamed

Obstetrics and Gynecology, Woman's Health University Centre, Assiut University, 5<sup>th</sup> Floor Woman's Health Center, 71526, Assiut, Egypt  
[hazemsaad2012@yahoo.com](mailto:hazemsaad2012@yahoo.com)

**Abstract:** Objective: A new concept is put forward to evaluate the outcome of the tension-free transobturator vaginal tape (TVTO) procedure (Gynecare<sup>®</sup>) in the management of female stress urinary and mixed incontinence in Women Health Hospital-Assiut. Study design: prospective observational, hospital based study. Fifty-one ladies suffering from stress urinary and mixed incontinence were surgically managed by (TVTO) manufactured by (Gynecare<sup>®</sup>) a polypropylene mesh tape with a pore size of 75-150 um, during the period from June,2007 to December, 2009. All participants underwent the following: (1) Through history and clinical examination. (2) Urodynamic tests include filling cystometry voiding cystometry and abdominal leak point pressure (Cm H<sub>2</sub>O). The inclusion criteria were genuine stress and mixed urinary incontinence with predominant stress element and Stable normal and compliant bladder. The exclusion criteria were central and or peripheral neurological disorder, unstable bladder and active urinary tract infections. The TVTO procedure was done according to DeLeval (2003)<sup>(1)</sup> and cases with genital prolapse beyond first degree underwent surgical correction before TVTO procedure. **Results:** Eighteen (35.3%) patient underwent concomitant operative repair of genital prolapse in addition to the TVTO. There were significant postoperative improvement in quality of life as regards the effect and sexual life. Also, no significant difference was found between objective and subjective cure rate along different postoperative months of follow up. **Conclusion:** our data further support the notion that TVT-obturator procedure, a novel mid-urethral sling operation, for the management of SUI in females seems to be effective and safe.

[H.S. Mohamed. **Evaluation of the Outcome of Transobturator Vaginal Tape in Management of Stress Incontinence in Women.** *Life Sci J* 2014;11(2):169-178]. (ISSN:1097-8135). <http://www.lifesciencesite.com>. 24

**Keywords:** Transobturater tape – stress Urinary incontinence.

**1.Introduction**

Urinary leakage will occur voluntarily or involuntarily whenever the intravesical pressure exceeds the intraurethral pressure. This apparently simple situation is in reality extremely complex and remains the subject of much debate<sup>(2)</sup>.

Urinary incontinence is a common health problem among women, the prevalence ranges from 3-55% depending on the definition of incontinence used and the age of the population studied<sup>(3)</sup>.

Genuine Stress urinary incontinence (Urodynamic stress incontinence) is defined by the international continence society (ICS) as involuntary loss of few drops of urine coincident with increased intravesical pressure in the absence of detrusor contraction as showed by urodynamics<sup>(4)</sup>.

Tension-Free vaginal tapes (TVT) have revolutionized the management of female stress urinary incontinence<sup>(5)</sup>. While these tapes have proved to have long-term efficacy, their insertion via retropubic route has been associated with a variety of operative and post-operative complications including bladder, urethral or bowel injuries<sup>(6,7)</sup>.

In 2001, an outside-in transobturator approach was proposed for the surgical placement of suburethral tapes to avoid the retropubic space and to decrease the complication rates<sup>(8)</sup>.

A new TOT procedure (TVT obturator; Gynecar<sup>®</sup>) was described by de leval to minimize urethral and bladder injury using an inside-out approach<sup>(9)</sup>.

Pelvic floor disorders, including pelvic organ prolaps and urinary incontinence, are debilitating conditions that result in surgery in one of nine women<sup>(10)</sup> and so in Women Health Hospital we should gain enough evidence-based experience for dealing with these urogynaecological problems.

Polypropylene monofilament mesh currently is considered the material of choice. The principle behind the mid-urethral approach is that incontinence results from weakening of the existing support structures of the female urethra and anterior vaginal wall. Also the vagina is connected to the arcus tendinus fasciae pelvis producing support to the midurethra<sup>(11)</sup>.

The transobturator approach involves placement of midurethral tape through the obturator membrane. Although there is a lack of long-term data regarding this approach, the current data suggest a comparable continence and complication rate with TVT, with some studies suggesting a reduction in incidence of bladder trauma compared to TVT or colposuspension<sup>(12,13,14)</sup>.

Tension-free vaginal tape-secur (TVT-S) is a smaller device produced by Gynecare<sup>®</sup>. Its purported advantages over the current sling procedures is that it

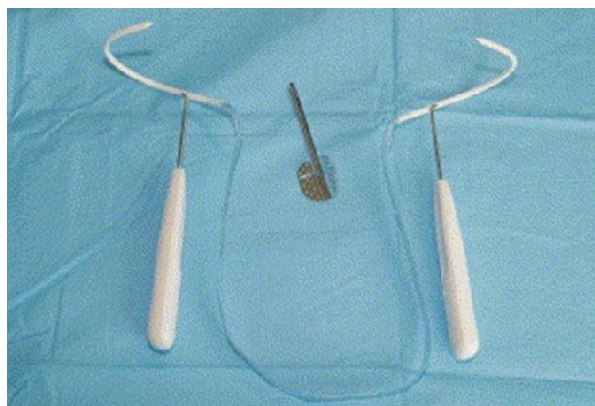
has all the benefits of a minimally invasive procedure but avoids the nerve structures that may result in post-operative pain, as well as avoiding the discomfort associated with the sites where the tape exits in the abdominal or thigh skin. It is also inserted via a simpler method and can employ the retropubic or transobturator pathways<sup>(15)</sup>.

In the (Updated Systematic Review and Meta-Analysis of the Comparative Data on Colposuspension, Pubovaginal slings, and midurethral tapes in the surgical treatment of Female Stress Urinary Incontinence) which was published in EUROPEAN UROLOGY<sup>(16)</sup> and compared classic TVT with inside-out TOT, no differences in subjective and over all continence rates were found. Also, with regard to complications, no, surprisingly, bladder or vaginal perforations as well as postoperative haematoma were significantly more common following retropubic tapes.

This current study was designed to determine and to evaluate the effectiveness, patient's satisfaction and safety of (TVT-O) procedure as a relatively novel management of females with SUI.

#### Patients and Methods

This prospective, observational, hospital-based study was conducted between June 2007 to December 2009 at the Woman's Health Center, Assiut University Hospital, Assiut-Egypt and comprised 51 patients with SUI and mixed UI with predominant stress element based on clinical and urodynamic evaluation who were managed surgically by transobturator vaginal tap (TVTO) manufactured by Gynecare® a knitted polypropylene mesh tape, length 45 cm, width 1.1cm monofilament, with a pore size of 1176µm<sup>2</sup>, thickness 0.7m, fiber diameter 152µm, elasticity less than 60% for a weight of 53gm, tensile strength 70N and elongation at break 87mm. (Fig. 1).



**Fig. 1: Gynecare TVT-O special device.**

All patients gave a clear written consent to participate in this study. Also all patients underwent the following:

1- History and through clinical examination of the patients sufferings from SUI symptoms.

2- Urodynamic evaluation to detect filling cystometry, voiding cystometry and abdominal leak-point pressure (CmH<sub>2</sub>O).

Inclusion criteria included genuine stress and mixed UI with predominant stress element based on clinical and urodynamic evaluation with stable normal and compliant bladder that emptied well with good coverage maximum flow rate (Q. max >15 ml/s), without any significant post-micturition residual and with maximal cystometric capacity more than 300 ml.

Exclusion criteria included central or peripheral neurological pathology, unstable bladder or active urinary tract infection.

#### Operative intervention:

All patients were given 1.5 gm of Unasyn (Pfizer®) (ampicillin (1) gm ± sulbactam (0.5) gm) intravenously one hour prior to surgery and were subjected to a povidine-iodine prophylactic anti-septic vaginal wash prior to commencement of the operation. The mode of anaesthesia, either general or spinal depended on anesthesiologist opinion and surgical fitness. No diagnostic cystoscopy was performed. Pelvic floor relaxation was recorded for evaluation of prolapse in accordance with the international continence society (ICS) pelvic floor prolapse quantification system (POPQ)<sup>(17)</sup>.

Patients presenting with significant genital prolapse had anterior with posterior colporrhaphy (classical repair) with or without vaginal hysterectomy as indicated.

During prolapse repair, we left 3 cm above the external urethral meatus without dissection to perform TVTO procedure.

The TVTO procedure done according to (De Leval, 2003)<sup>(1)</sup> where he patient was in lithotomy position with 120° hyperflexion. The first step was to mark the exit points of the tape in lateral folds of the thigh, using a marker pen. These were 2 cm lateral to the labial fold where a line parallel and 2cm superior to a horizontal line at the level of external urethral meatus. A urethral catheter is inserted into the urinary bladder, which is emptied.

The anterior vaginal wall was incised at a length of 1cm and at a distance of 1cm proximal to the external urethral meatus. This step was followed by introducing fine dissecting scissor through the initial dissection pathway towards the upper part of the ischio-pubic ramus on horizontal plane with a 45° angle to the urethral saggited plane (Fig 2). Once the upper part of the ischiopubic ramus was reached, the obturator member is perforated with the tip of the scissor.

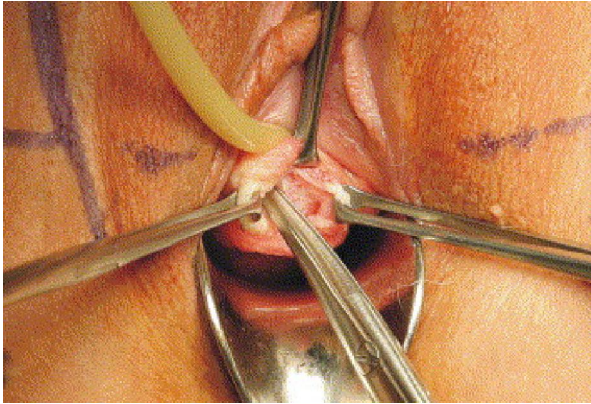


Fig. 2: Median sagittal incision of the vaginal wall. Introduction of fine dissection scissors towards the upper part of the ischio-pubic ramus to perforate the obturator membrane.

An introducer, with open-side of its gutter facing the surgeon (winged guide), is pushed along the performed dissection canal till it reaches and perforates the obturator membrane. The distal end of the tube mounted onto the spiral segment of the needle is gently slipped along the gutter of the introducer in order to pass through the obturator foramen (Fig.3).

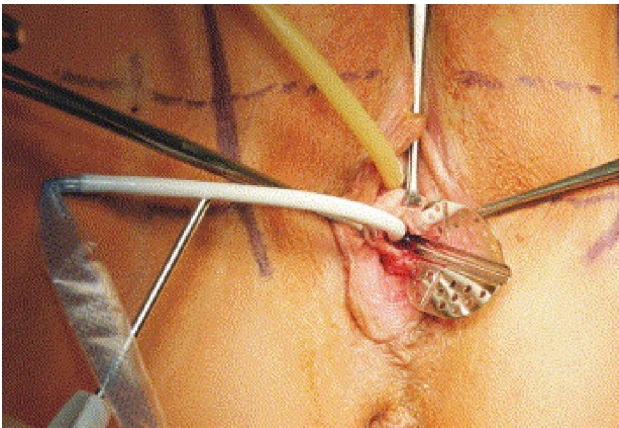


Fig. 3: The introducer is pushed along the performed dissection canal until it perforates the obturator membrane. The tube mounted onto the spiral segment of the needle is slipped along the gutter of the introducer so as to pass through the obturator foramen.

Then, the introducer is removed. After the tube has appeared at the previously determined skin exit point, the tube is pulled off from the supporting needle which is removed (Fig. 4).

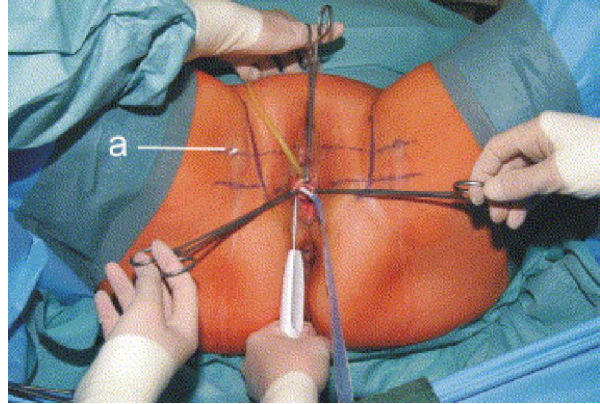


Fig. 4: The tube appears at the previously determined skin exit point a. the skin exit points are identified by tracting a horizontal line at the level of the urethral meatus and a second line parallel and 2 cm above the first line. The exit points are located at the second line 2 cm outside of the genitofemoral folds.

The same technique is applied on other side. Next the ends of the tape or cut, the tape is aligned under the middle of the urethra, creating space and avoiding any tension of the tape by grasping it at its middle with a blunt clamp, thus creating a small loop of 5mm or putting the scissor in between the tape and the urethra. The plastic sheaths are then removed simultaneously. Cough-stress test were then done by filling the bladder with 200 ml normal saline and after removal of the urethral catheter, the patient was asked to cough, then we could adjust the tap to confirm continence. If coughing was difficult or the patient was under general anesthesia, suprapubic repeated pressure was done. The tape ends were cut in the subcutaneous layer and the incisions were closed.

This procedure was not in need for cystoscopy but bladder injury (if occurred) could be diagnosed by urinary leakage via the wound and could be managed by removal and reposition of the trocar and bladder drainage for at least 7 days.

Urethral perforation (if occurred) had to be repaired primarily over a catheter and surgery had to be postponed for a minimum of 6 weeks. Bowel injury (if occurred) could be indicated from abdominal pain to a painless greenish discharge at the trocar site and when suspected, consultation of a general surgeon is mandatory and exploratory laparotomy should strongly be considered.

Bleeding could be controlled by compression and electro cauterization by bipolar diathermy. The catheter was left for 24 hours in all cases and after removal postvoid residual volume (PVR) was assessed and any voiding difficulty was recorded.

Urinary obstruction can be diagnosed by urinary retention and can be managed by re-catheterization or

if no response, readjustment or even incision of the sling.

The patient was discharged if normal voiding pattern was established and was instructed to avoid sexual intercourse for at least one month and to avoid pregnancy for at least one year and caesarean section is recommended for delivery.

Postoperative follow-up visits were routinely scheduled at 1, 6, 12 and 24 months. The therapeutic failure, meaning sustained (SUI) as subjective symptom and confirmed with clinical evaluation with stress test and urodynamics.

Subjective satisfaction was evaluated and effect on sexual life was evaluated by asking about incontinence during intercourse.

#### Statistical evaluation:

Data were collected and analyzed with SPSS version 16 (SPSS, Chicago, IL, USA) and expressed as mean  $\pm$  standard deviation (SD). Statistical methods were applied, including descriptive statistics (frequency, percentage, mean, and SD) and tests of significance. A *P*-value  $<0.05$  was considered statistically significant. Categorical variables were compared using  $\chi^2$  test or Fisher's exact test as appropriate.

All the regulations of the ethical committee of the faculty of medicine were followed. Ethical approval from OB/Gyn department was taken.

### 3. Results

Table (1): Showed the sociodemographic data, medical and postoperative history as well as the incontinence period of the participating women.

**Table (1): The socio-demographic, medical history, previous operative history and incontinence period (no. = 51).**

	No.	%	Mean $\pm$ SD (Range)
Age (years)			40.5 $\pm$ 9.3 (28-65)
Parity (deliveries)			5 $\pm$ 2.2 (1-12)
Previous USI corrective surgery	3	5.7	
Previous surgery for prolapse	4	7.8	
Classical repair	2	3.8	
Vaginal hysterectomy	2	3.8	
Background chronic illness*	14	26.4	
Incontinence period (years)			3.3 $\pm$ 1.5 (1-10)
Weight			75.9 $\pm$ 12.2 (45-110)
Height			164 $\pm$ 6.6 (155-186)
Body mass index (BMI)			27 $\pm$ 6.6 (16-42)
Previous operative vaginal delivery			2 $\pm$ 0.5 (0-3)

USI: urinary stress incontinence.

\*Diabetes mellitus, bronchial asthma, hypertension, and hypothyroidism.

Table (2) showed preoperative (overactive bladder) symptoms as well as urodynamic parameters. The urodynamic objective detrusor overactivity was diagnosed by cystometry in 4 ladies with predominant SUI (7.8%).

**Table (2): Preoperative OAB symptoms and urodynamic parameters (no.=51).**

	No.	%
OAB symptoms:		
Objective symptoms	4	7.8
Subjective symptoms		
Frequency	15	29.4
Urgency	9	17.6
Urge incontinence.	6	11.8
Urodynamic diagnosis:		
Genuine SUI	46	90.2
Mixed incontinence	5	9.8
PVR: Mean $\pm$ SD (Range)		16.2 $\pm$ 7 (10-30)
Abdominal leak point pressure test: Mean $\pm$ SD (Range)		126 $\pm$ 28 (50-199)
Maximal cystometric capacity: Mean $\pm$ SD (Range)		453 $\pm$ 52 (310-610)

OAB: Overactive bladder.

The severity of stress incontinence is illustrated in table (3). The effect on sex was evaluated by asking about incontinence during intercourse.

**Table (3):** Severity of stress incontinence patients (no. = 51)

	No.	%
Incontinence during intercourse.	18	35.3
Effect n sex life:		
No effect	9	17.6
Minimal effect	29	56.7
Great effect	13	25.5
Effect on quality of life:		
No effect	0	0.0
Minimal effect.	0	0.0
Moderate effect	17	33.3
Great effect	34	66.7
Number of leakage per week: Mean $\pm$ SD (Range)	28 $\pm$ 7.3 (14-40)	

The Details of operative patients is illustrated in table (4). According to the POPQ system<sup>(17)</sup>, 18 (35.3%) patients had advanced cystocele, 16 (31.4%) had advanced rectocele and 4 (7.8) had uterine prolapsed. Eighteen (35.3%) patients underwent concomitant operative procedures in addition to the TVT-obturator: 18 (35.5%) had anterior and/or posterior colporrhaphies, 4 (7.8%) had vaginal hysterectomies.

**Table (4):** Details of operative patients (no. = 51)

	No.	%
Anesthesia:		
General	3	5.9
Regional (spinal)	48	94.1
Assessment of prolapse:		
Cystocele	18	35.3
Rectocele	16	31.4
Uterine prolapse	4	7.8
Concomitant corrective operations	18	35.3
Colporrhaphy:		
Anterior	18	35.3
Posterior	16	31.4
Vaginal hysterectomy	4	7.8

POP-Q: pelvic organ prolapse quantification system.

In intraoperative complications, difficulty and duration of surgery are illustrated in table (5), there were no intraoperative complications like bladder penetration bowel and or urethral injury. There were 2 patients with narrow external urethral meatus leading to difficult catheterization, the readjustment of scissor pathway occurred in 3 patients and difficulty in helical passer pathway in 3 patients. The duration of surgery meaning the duration of TVT-O only not including the prolapse correction.

**Table (5):** Intraoperative complications, difficulty and duration of surgery.

	No.	%
Bladder penetration, bowel and/or urethral injury	0	0.0
Intraoperative bleeding > 200 ml	4	7.8
Difficulty during surgery:	8	15.7
Difficult catheterization	2	3.9
Difficult in scissor pathway	3	5.9
Difficult in helical passer pathway	3	5.9
Duration of surgery: Mean $\pm$ SD (Range)	24 $\pm$ 4.8 (15-35)	

The details of postoperative are illustrated in table (6) as regard pain by visual analogue scale, analgesic required, PVR and postoperative hospital stay. The analgesic required was evaluated by number of ibuprofen tablets. The PVR was evaluated at 24 hours and one week postoperative. Most of cases stay at hospital for 24 hours.

**Table (6):** Details of postoperative patients (no. = 51)

	No.	%
Postoperative pain by visual analogue scale at:		
2 hours	9 ± 1.3	4-9
6 hours	5 ± 0.5	2-6
24 hours	3 ± 0.4	2-4
Analgesic required	11 ± 1.9	4-12
Post void residual volume at 24 hours	28.2 ± 9	10-170
Post void residual volume at 1 week	26 ± 7	10-160
Length of post operative hospital stay (hours)	24 ± 8.8	24-96

The early postoperative complications (in the first 15 days) are illustrated in table (7). As regard early postoperative complications no vaginal tape protrusion, urethral erosion, bladder erosion, haematoma, abscess and or postoperative field infection were reported. Early postoperative partial outlet obstruction, defined as post maturation bladder urine content of 150 ml or more, was treated with repeated bladder catheterization for two days in one patient, for 3 days in 2 patient and for 4 days in 2 patients (5 [9.8%] patients). Four (7.8%) patients reported postoperative urgency symptom, 2 (3.9%) as de novo occurrence and the remainder as a long-lasting problem. One (2%) suffered postoperative de novo urge incontinence.

**Table (7):** Early postoperative complications patients (no. = 51)

	No.	%
Vaginal tape protrusion, bladder erosion, urethral erosion, heamatoma and or abscess	0	0.0
Fever	0	0.0
Postoperative voiding difficulties (>24 h)	5	9.8
Urethral catheterization (1-4 d)	5	9.8
Postoperative urgency symptoms	4	7.8
De novo urge incontinence symptoms	1	2.0

The comparison of OAB symptoms preoperative and postoperative are illustrated in table (8), there were significant reduction in the rate of frequency and urgency but in cases of urge incontinence there were insignificant reduction.

**Table(8):** Comparison of OAB symptoms pre and post operative (no.=51).

	Frequency		Urgency		Urge incontinence	
	No.	%	No.	%	No.	%
Preoperative	15	29.4	9	17.6	6	11.8
1 month postoperative	4	7.8	5	9.8	1	2
6 month postoperative	3	5.9	3	5.9	1	2
12 month postoperative	2	3.9	3	5.9	3	5.9
24 month postoperative	2	3.9	1	2	3	5.9
P-value	0.000*		0.004*		0.315	

The comparison of Quality of life effect and effect on sex pre and post operative is illustrated in table (9), there were significant improvement postoperatively.

**Table (9):** Comparison of Quality of life effect and effect on sex pre and post operative (no. = 51).

	Preoperative		1 month Postoperative		6 months Postoperative		12 months Postoperative		24 months postoperative	
	No.	%	No.	%	No.	%	No.	%	No.	%
Quality of life effect:										
No.	0	0.0	40	78.4	38	74.5	38	74.5	36	70.6
Minimal	0	0.0	6	11.8	9	17.6	9	17.6	11	21.6
Moderate	17	33.3	5	9.8	4	7.8	4	7.8	4	7.8
Great effect	34	66.7	0	0.0	0	0.0	0	0.0	0	0.0
P-value	0.000*									
Effect on sex:										
No.	9	17.6	48	94.1	49	96	48	94.1	49	96.1
Minimal	29	56.7	1	2.0	1	2.0	1	2.0	2	0.0
Great	13	25.5	2	3.9	1	2.0	2	3.9	2	3.9
P-value	0.000*									

The comparison between objective and subjective cure rate is illustrated in table (10) there were insignificant different between postoperative months of follow up.

**Table (10):** comparison of objective and subjective cure rate (no. = 51)

	1 month postoperative		6 months Postoperative		12 months Postoperative		24 months postoperative	
	No.	%	No.	%	No.	%	No.	%
Objective evaluation:								
Cured	43	84.3	43	81.3	42	82.4	41	80.4
Improved	2	3.9	4	7.8	5	9.8	6	11.8
Failed	6	11.8	4	7.8	4	7.8	4	7.8
P-value								
Subjective satisfaction:								
Very satisfied	39	73.5	37	72.5	38	74.5	39	76.5
Satisfied	5	9.8	8	15.7	8	15.7	8	15.7
Unsatisfied	7	13.7	6	11.8	5	9.8	4	7.8
P-value								

#### 4. Discussion

Stress urinary incontinence (SUI) is a continuous dilemma that requires more studies and is the most common cause of involuntary loss of urine in women. Indeed upon close interviews with normal women, several investigators have shown that about 50% of nulliparous women occasionally experience SUI (EL-Hemaly *et al.*, 1996)<sup>(2)</sup>. It is clear that in idea of evaluating TVT-OP is not a new event.

In our current study, TVTO procedure was performed in (51) patients. There were (3) patients with previous SUI corrective surgery, 2 with anterior colporrhaphy and 1 with Burch colposuspension. The incontinence period (Mean  $\pm$  SD (Range)) was (3.3  $\pm$  1.5 – (1-10)), body mass index (BMI) was 27 $\pm$ 6.6 (16-42). Previous surgery for prolapse were 4 (7.8%). There were 5 patients with mixed incontinence and 3 patients with intrinsic sphincter deficiency were enrolled in this study. The urodynamic objective detrusor overactivity was diagnosed by cystometry in 4 ladies with clinically predominant SUI (7.8%).

Our sample size was nearly similar to the study of Deng *et al.* (2007)<sup>(18)</sup> but relatively smaller than that of Waltregny (2006)<sup>(24)</sup> 102 TVTOP (148 TVTO procedure) Abdel-Fattah *et al.* (2006)<sup>(19)</sup>; Neuman *et al.* (2006)<sup>(20)</sup> (300 TVTO procedure); Tamussino *et al.* (2007)<sup>(21)</sup> (1389 TVTO procedure); Collinent *et al.* (2008)<sup>(22)</sup> (984 TVTO procedure); Wenyan *et al.*, (2009)<sup>(23)</sup> (145 TVTO procedure), Liapis *et al.*, (2010)<sup>(27)</sup> (115TVTO procedure). As regard duration TVTO surgery, in our current study, it was (Mean  $\pm$  SD (Range)) (24 $\pm$ 4.8 (15-35)).

Wenyan (2009)<sup>(23)</sup> reported a relatively shorter duration of surgery (18.4 $\pm$ 4). We consumed a longer time in the first 10 cases and this could be attributed to early mastering the technique and the intra-operative stress test (absorbed about 5 minutes).

In our study, there were no intra-operative complications like bladder penetration, bowel and or urethral injury. The readjustment of scissor pathway occurred in 3 patients and difficulty in helical passer pathway in 3 patient. The intra-operative bleeding

more than 200 ml occurred in 4 patients (7.8%). The postoperative pain evaluation by visual analogue scale (Mean  $\pm$  SD) at 6 and 24 hours were  $5 \pm 0.5$  and  $3 \pm 0.4$  respectively, duration of hospital stay (Mean  $\pm$  SD (Range) was ( $24 \pm 8.8$ ) (24-96)), the catheter was removed after 24 hours in all cases, the post void residual volume (PVR) at 24 hours postoperatively (Mean  $\pm$  SD (Range) was ( $28 \pm 9$ ) (10-170)).

These results were coincided with that of Wenyan *et al.* (2009)<sup>(23)</sup> and Abdel-Fathah *et al.*, (2006) who reported no intra-operative complications and or difficulty. In the Wenyan *et al.*, study intra-operative bleeding in ml Mean  $\pm$  SD  $60.8 \pm 41.8$ , duration of hospital stay in days (Mean  $\pm$  SD was ( $3.9 \pm 2.8$ ), the catheter was removed after 12 hours in all cases, the post void residual volume at 24 hours postoperative less than 100 ml in 81.5% of all patients.

Collinet *et al.* (2008)<sup>(22)</sup> reported one urethral injury in their French study. This could be due to the extremely larger simple size when compared to our study. Also, Jakimiuk *et al.* (2007)<sup>(25)</sup> were in need to perform one cystoscopy for immediate total haematuria after needle insertion on the left side. The needle was withdrawn and reinserted the urinary catheter was left for 1 day longer than usual. The further postoperative course was uncomplicated.

Also, Tamussino *et al.* (2007)<sup>(21)</sup> reported that the TVTO procedures were associated with a lower risk of urinary bladder perforation than retropubic techniques. Waltregny *et al.* (2006)<sup>(24)</sup> reported that, no TVTO related bowel or urethral injury had ever been reported and this was in accordance with our results in this aspect.

In our study as regard early postoperative complications no vaginal tape protrusion, urethral erosion, bladder erosion, haematoma, abscess and or postoperative field infection were reported. Early postoperative partial outlet obstruction, defined as post micturation bladder urine content of 150 ml or more, was treated with repeated bladder catheterization every 24 hours for two days in one patient, for 3 days in 2 patient and for 4 days in 2 patients (5 [9.8%] patients). Four (7.8%) patients reported postoperative urgency symptom, 2 (3.9%) as de novo occurrence and the remainder as a long-lasting problem. One (2%) suffered postoperative de novo urge incontinence.

Wenyan *et al.*, 2009<sup>(23)</sup>, reported after a median of 1.4 (range 0.5-20) days, placement, all the urinary catheters were permanently removed when the residual volume dropped to less than 100 mL. Many patients experienced frequent urination, dysuria, and voiding dysfunction following catheter removal, but no objective measurements could be recorded for these symptoms, which disappeared within 2 weeks, 2

patients presented with hematomas behind the bladder 2 days after the operation. None of these patients needed blood transfusion or surgical intervention. All hematomas disappeared within 3 months. Three patients had vaginal tape erosions at 3, 4, and 12 months follow-up. There were no cases of urethral or bladder erosion in this series. Twelve patients (8.2%) complained of groin/thigh pain.

Waltregny *et al.* (2006)<sup>(24)</sup>, reported, Voiding difficulties were less than 5% of the patients. Joanna and J. (2009), reported no considerable intra-operative bleeding, bladder or intestinal penetration, or postoperative field infection was reported. Early postoperative partial outlet obstruction, defined as post micturation bladder urine content of 150 ml or more, was treated with repeated bladder catheterization for up to 4 days (nine [3.0%] patients), whereas complete obstruction needed tape resection (nine [3.0%] patients). Four (1.3%) patients suffered postoperative dyspareunia attributable to posterior migration of the tape, which was palpated close to the anterior vaginal fornix, away from the original placement. Two (0.7%) patients had vaginal tape protrusion, forty-three (14.3%) patients reported postoperative symptoms of bladder overactivity, 10 (3.3%) as de novo occurrence and the remainder as a long-lasting problem.

In our current study the cure rate at 6, 12, 24 months respectively were 84.3%, 82.4%, 80.4% and the improvement rate at 6, 12, 24 months respectively were 7.8%, 9.8%, 11.8% and the failure rate at 6, 12, 24 were 4 cases 7.8% in all months of follow up.

This was nearly similar to the result of Liapis *et al.* (2010)<sup>(27)</sup> who reported that cure rate, improvement rate and failure rate at (4) years follow-up were 80.5%, 7.4% and 12.6% respectively. However the relatively higher failure rate over our results could be explained by the longer period of postoperative follow-up (4 years).

Indeed, it must be kept in mind that the methodology used to evaluate subjective and/or objective cure, patient's selection criteria, and length of follow up were uneven among studies. Nevertheless, results appeared rather similar, with an overall estimated SUI cure rate of about 90%. All cure rates ranged between 85% and 100%, with the exception of one study of O'connor *et al.* (2006)<sup>(28)</sup> in which the cure rate appeared lower (65%) and the explanation could be that they included a substantial number of patients with intrinsic sphincter deficiency (ISD).

The slightly lower cure rate in our study may be due to, three cases of ISD two of them became improved and one show therapeutic failure and also there were (5) cases diagnosed as mixed incontinence



two of them became improved and one show therapeutic failure.

In our study there were 15 patients reported one or more symptoms of bladder overactivity (29.4%). The urodynamic objective detrusor over activity was diagnosed by cystometry in 4 patients with predominant SUI clinically 7.8%, whereas only 4 (7.8%) of them suffered from the same problem post surgery with only one case of urodynamic proved detrusor over activity. There were 3 cases complaining of urge incontinence postoperative one at one month, 2 at 6 month and 3 at 24 month 2 of them from the improved cases and one from the failed cases, one as denovo occurrence and 2 preoperatively diagnosed as mixed incontinence and so the cure rate in mixed incontinence was 60% and the improvement rate was also 20% and the failure rate was 20%. The de novo occurrence of symptoms of bladder over activity in 2 cases (3.9) could neither be predicted preoperatively nor explained by any particular event that occurred during surgery.

Houwert *et al.* (2007)<sup>(29)</sup> as well as Neuman *et al.* (2006)<sup>(20)</sup> reported more postoperative improvement rates of the symptoms of bladder overactivity and this might be explained by the through pelvic floor damage repair in this managemental scheme.

In our study as regard the subjective satisfaction at one year of follow up 74.5% were every satisfied, 15.7% were satisfied and 9.8% were unsatisfied. The comparison of Quality of life effect and effect on sex pre and post operative, there were significant improvement postoperative. The comparison between objective and subjective cure rate, there were insignificant different between postoperative months of follow up.

Houwert *et al.* (2007)<sup>(28)</sup>, also reported a significant improvement in QOL. One- and 3-year data were analyzed in the same cohort of patients, which allowed for a longitudinal and paired evaluation of outcome.

These results largely supported the notion that the positive impact of the TVT-O procedure maintains for at least 3 years postoperatively. Another important finding of this trial was that no late complication was observed.

### Conclusion:

Our data further support the notion that the TVT obturator procedure, a novel midurethral sling operation for the treatment of female stress urinary incontinence, seems to be effective and safe. Intraoperative diagnostic cystoscopy and bladder catheterization might not be mandatory with this newly introduced surgical approach. The TVT obturator procedure was associated with fewer complications, both intraoperatively and

postoperatively, than previously reported for the TVT procedure. These complications included a lower incidence of operative bleedings, postoperative field infections, and voiding difficulties.

### References

1. De Leval J.: (2003). Novel surgical technique for the treatment of female stress urinary incontinence: transobturator vaginal tape inside-out. *Eur. Urol*, 44: 724-730.
2. El. Hemaly AK and Mousa LA: (1996). Stress urinary incontinence, a new concept. *European J. of obstetrics and Gynecology and Reproductive Biology*. 68: 129-135.
3. Thompson PK, Duff DS, Thayer PS. Stress incontinence in women under 50: does urodynamics improve surgical outcome? *Int. Urogynecol. J. Pelvic Floor Dysfunct*. 2000;11: 285-289.
4. Abrams P, Cardozo I, Fall M. *et al.* (2002): The standardization of terminology in lower urinary tract function: report from the standardization sub-committee of the international continence society. *Urology*; 61: 37-49.
5. Ulmsten U, Henriksson L, Johnson P, Varhos G. (1996): An ambulatory surgical procedure under local anesthesia for treatment of female urinary incontinence. *Int Urogynecol. J. Pelvic Floor Dysfunct* 7: 81-85.
6. Hermiou JF. Complications of the TVT technique. *Prog. Urol.* (2003); 13: 459.
7. Nilsson CG, Falconer C, Rezapour M: Seven-year follow-up of the tension-free vaginal tape procedure for treatment of urinary incontinence. *Obstet. Gynecol.* 2004; 104: 1259-1262.
8. Delorme E. (2001): Transobturator urethral suspension: miniinvasive procedure in the treatment of stress urinary incontinence in women. *Prog. Urol.* 11: 1306-1313.
9. Deffieux X, Daher N, Mansoor A, *et al.* (2007): Tension-free vaginal tape (TVT) and transobturator suburethral tape from inside to outside (TVT-O) for surgical treatment of female stress urinary incontinence: a multicenter randomized controlled trial (abstract). In *Urogynecol J.*; 18 (Suppl 1), S 19: 33.
10. Olsen AL, Smith VJ, Bergstrom JO, Colling JC, Clark AL. (1997): Epidemiology of surgically managed pelvic organ prolapse and urinary incontinence. *Obstet Gynecol.* 98: 501-506.
11. DeLancey JO. (1988): Structural aspects of the extrinsic continence mechanism. *Obstet Gynecol*; 72 (3 Pt 1): 296-301.
12. Botros SM, Miller JJ, Goldberg RP, *et al.* (2007): Detrusor over activity and urge urinary incontinence following trans obturator versus

- midurethral slings. *Neurourol Urodyn*; 26 (1): 42-45.
13. Latthe PM, Foon R, Toozs-Hobson P. Transobturator and retropubic tape procedures in stress urinary incontinence: A systematic review and meta-analysis of effectiveness and complications. *BJOG* 2007; 114 (5): 522-531.
  14. Zullo MA, Plotti F, Calcagno M. *et al.* One-year follow-up of tension-free vaginal tape (TVT) and transobturator suburethral tape from inside to outside (TVT-O) for surgical treatment of female stress urinary incontinence: A prospective randomized rial. *Eur. Urol.* 2007; 51 (5): 1376-1384.
  15. Panayi DC and Khullar VS urgery for Stress Urinary Incontinence: Midurethral Slings, *Int. Urogynecol J. Pelvic Floor Dysfunct* 2007; 17 (2): 125-130.
  16. Giacomo Novara A, Walter Artibani B, Matthew D. Barber C, Christopher R. Chapple D, Elisabetta Costantini E, Vincenzo Ficarra A, Paul Hilton F, Carl G. Nilsson G. and David Waltergny (2010): Updated systematic Review and Meta-Analysis of the comparative data on colposuspension, pubovaginal slings, and midurethral tapes in the surgical treatment of Female stress urinary Incontinence. *European Urology* 58, 218 – 238.
  17. Bump RC, Mattiasson A, Bo K, *et al.* (1996): The standardization of terminology of female pelvic organ prolapse and pelvic floor dysfunction. *Am. J. Obstet Gynecol*; 175: 10-17.
  18. Deng DY, Rutman M, Raz S, *et al.* (2007): Presentation and management of major complications of midurethral slings: are complications under-reported? *Neurourol Urodyn*; 26: 46-52.
  19. Abdel-Fattah M, Ramsay I, Pringle S. (2006): Lower urinary tract injuries after transobturator tape insertion by different routes: a large retrospective study. *BJOG* 113 (12): 1377-1381.
  20. Neuman G, Lobodasch K, Bettin S, Meyer P, Koelbl H. Tension free vaginal tape (TVT) vs less nvasive free tape (LIFT)-a randomized multicentric study of suburethral sling surgery. *Int. Urogynecol. J.* 2006; 17 (Suppl 2): S94-5, Abstract 062.
  21. Tamussino K, Hanzal E, Kolle D (2007): Transobturator tapes for stress urinary incontinence: results of the Austrian registry. *Am. J. Obstet Gynecol.* 197 (6): 634 e1-634 e5.
  22. Collinet P, Ciofu C, Costa P. (2008): The safety of the inside-out transobturator approach for transvaginal tape (TVT-O) treatment in stress urinary incontinence: French registry data on 984 women. *Int Urogynecol J. Pelvic Floor Dysfunct* 19 (5): 711 – 715.
  23. Wenyan Wang, Lan Zhu, Jinghe Lang Transobturator tape procedure versus tension-free vaginal tape for treatment of stress urinary incontinence *International Journal of Gynecology and Obstetrics* 104 (2009) 113-116.
  24. Waltregny D, Reul O, Mathantu B, *et al.* (2006): Inside out transobturator vaginal tape for the treatment of female stress urinary incontinence: interim results of a prospective study after a 1-year minimum follow up. *J. Urol.*; 175: 2191-2195.
  25. Jakimiuk AJ, Maciejewski T, Fritz A. (2007): Surgical treatment of stress urinary incontinence using the tension-free vaginal tapeobturator system (TVT-O) technique. *Eur. J. Obstet. Gynecol. Reprod Biol.* 135 (1): 127-131.
  26. Joanna M. Togami and J. (2009): *Christian Winters Suburethral Sling Failures and Complications* R.P. Billingham *et al.* (eds.), *Reoperative Pelvic Surgery*, DOI 10.1007/b14187-13, Springer Science Business Media, LLC.
  27. Liapis, P. and Bakas, G. (2010): Efficacy of inside-out transobturator vaginal tape (TVTO) at 4 years follow up *European Journal of Obstetrics and Gynecology and Reproductive Biology* 148 199-201.
  28. O'Connor RC, Nanigian DK, Lyon MB. (2006): Early outcomes of mid-urethral slings for female stress urinary incontinence stratified by valsalva leak point pressure. *Neurourol Urodyn* 25 (7): 685-688.
  29. Houwert M, Vos MC, Vervest HAM. (2007): Transobturator tape (TOT), inside-out versus outside-in approaches: outcome after 1 year. *Int. Urogynecol J*; 18 (Suppl 1): S 33, Abstract 056.