

Hepatic Stellate Cell Expression of Alpha-smooth Muscle Actin: Role in Recurrent Hepatitis C Virus in Living Donor Liver Transplantation

El-Monayeri M^{1,2}, Farid R², Refaie R^{1,2}, Safwat W^{1,3}, Abdelal M¹, Salem R², Saad Eldin S², Mahdy M², Mostafa I^{1,3} and El-Meteini M^{1,2}

Liver transplant unit, Wady el Neel Hospital¹, Ain Shams university, Faculty of Medicine², Cairo, Egypt and Theodor Bilharz Research Institute³

Refaie_rasha@yahoo.com

Abstract: Background: The alpha isotope of actin expressed by Hepatic stellate cells (HSCs) reflects their activation to myofibroblast-like cell and is directly related to liver fibrogenesis in chronic liver disease. **Aim:** To study the correlation between the activation of HSCs and the degree of fibrosis in patients with recurrent HCV chronic hepatitis after Living Donor Liver Transplantation (LDLT). **Methods:** A total of 69 biopsies from 17 patients with post transplant recurrent HCV hepatitis, 17 cirrhotic liver and 17 normal control liver were retrospectively studied. Paraffin sections of all 69 biopsies were stained with anti-alpha-smooth muscle actin antibody by immunoperoxidase method and semi-quantitatively evaluated. Liver fibrosis was assessed by Masson's trichrome stain. HCV-PTR patients received standard antiviral therapy. **Results:** The grade of alpha-smooth muscle actin-positive HSCs were significantly higher in the HCV-C group (35.3% G3, 35.3% G4) and HCV-PTR group (58.8% G1) compared to DL group (70.6% G0). HSCs activation preceded the detection of fibrous tissue deposition in some patients with HCV-PTR. There was a statistically significant correlation between the grade of HSCs and the stage of fibrosis in HCV-PTR group. After antiviral therapy HSC grade significantly decreased, in both clinically responders and non-responders; the decrease in HSC grade also correlated with the improvement in activity grade. HSCs increased after episodes of acute cellular rejection. **Conclusion:** Our study confirmed the value of alpha-smooth muscle actin expression as a reliable marker of HSCs activation that could be useful to identify early stages of hepatic fibrosis and monitor the efficacy of therapy. In the presence of advanced cirrhosis other factors, rather than alpha-smooth muscle actin-positive HSC, may sustain fibrosis deposition.

[El-Monayeri M, Farid R, Refaie R, Safwat W, Abdelal M, Salem R, Saad Eldin S, Mahdy M, Mostafa I and El-Meteini M. **Hepatic Stellate Cell Expression of Alpha-smooth Muscle Actin: Role in Recurrent Hepatitis C Virus in Living Donor Liver Transplantation.** *Life Sci J* 2013;10(4):2778-2784]. (ISSN:1097-8135). <http://www.lifesciencesite.com>. 371

Keywords: living donor liver transplantation ; hepatic stellate cells; post transplant recurrent HCV; alpha smooth muscle actin; hepatic fibrosis

1.Introduction:

The clinical presentation of acute HCV hepatitis is mild and produces symptoms in only 20% of patients⁽¹⁾. However, 80% of patients do not clear the virus and become chronically infected with HCV. Of the chronically infected individuals, 20% will develop cirrhosis within 20 years and, once the disease is established, will go on to develop hepatocellular carcinoma at a rate of 1% to 4% per year⁽²⁾. Chronic HCV-related cirrhosis is the most common indication for liver transplantation (LT). Although recurrent hepatitis C virus (HCV) after liver transplantation (LT) is universal⁽³⁾, the cumulative probability of developing graft cirrhosis estimated to reach 30% at 5 years⁽⁴⁾. The accumulation of extracellular matrix observed in fibrosis and cirrhosis is due to the activation of fibroblasts, which acquire a myofibroblastic phenotype. Myofibroblasts are absent from normal liver; they are produced by the activation of precursor cells, such as hepatic stellate cells⁽⁵⁾. Hepatic stellate cells (HSC), which account for about

5–8% of cells in the normal liver, are characterised by a perisinusoidal distribution in the Disse space. On activation, the HSC acquire a myofibroblastic phenotype, contributing to the excessive extracellular matrix deposition observed in the pathological conditions of fibrosis and cirrhosis. Capillarization of the sinusoids also occurs, with a continuous endothelium formed, and the presence of a true basal lamina⁽⁶⁾. Alpha-smooth muscle actin expression is a reliable marker of hepatic stellate cells activation which precedes fibrous tissue deposition even in the setting of recurrent HCV chronic hepatitis after LT. The alpha isotype of actin expressed by HSC reflects their activation to myofibroblast-like cell and has been directly related to experimental liver fibrogenesis, and indirectly to human fibrosis in chronic liver disease⁽⁷⁾. The hope to avoid HCV devastating effect on the Egyptian society and its enormous negative impact on our economy fueled our study.

2.Material and methods:

Tissue samples

Eighty- three patients underwent living donor liver transplantation for end-stage liver disease from chronic hepatitis C at Wady El Neel hospital, Cairo, Egypt from 2001 to 2005. All recipients were hepatitis C RNA-positive by quantitative polymerase chain reaction. The studied group included 17 patients who had recurrent HCV in the graft. This retrospective study involved 69 hepatic tissue samples divided into 3 groups: Group I: HCV cirrhosis (HCV-C) (n=17) from explanted cirrhotic liver. Group II: post-transplant HCV recurrent hepatitis (HCV-PTR) (n= 35), 3 of these patients had episodes of acute cellular rejection. Liver biopsy was done when clinically indicated at an average interval of 11.2 ± 6.4 months post-transplant (HCV-PTR 1), 19.4 ± 8.6 months post-transplant (HCV-PTR 2), and 26 ± 8.8 months post-transplant (HCV-PTR 3). Group III: normal donor livers (DL) (n=17). Liver tissue samples were routinely stained with haematoxylin-eosin and Masson's trichrome stains to identify collagen fibres. Immunohistochemical staining was done using Monoclonal anti-alpha smooth muscle actin 1A4 (ready to use)

Immunosuppression:

Standard immunosuppression consisted of calcineurin inhibitors, prednisone, that was tapered and discontinued within 3 months following transplantation, and mycophenolate mofetil. Patients initially receiving cyclosporine (Neoral, Novartis Pharmaceutical) were treated with a dose of 2.0-4.0 mg/kg/day orally in 2 divided doses with a target trough whole blood concentration 200-250 ng/ml for the first month after transplantation followed by 100-150 ng/ml thereafter. Patients initially receiving tacrolimus (Prograf, Fujisawa Healthcare) were treated with a dose of 0.08-0.12/kg/day orally in 2 divided doses with a target trough whole-blood concentration of 8-10 ng/ml for the first month after transplantation followed by 3-5 ng/ml thereafter. Patients with HCC were maintained by low dose CNI and mTOR inhibitor (everolimus) to decrease the chance of tumour recurrence

Interpretation of Results

Histopathological Evaluation

In the *HCV-C group*, Activity is graded as follows⁽⁸⁾:

- 0=No inflammation and intact limiting plates around septa which are fibrotic.
- 1=Mild inflammation; segmental erosion of limiting plates.
- 2=Moderate inflammation and damage of limiting plates.
- 3=Marked inflammation, extensive damage of limiting plates, piecemeal necrosis and parenchymal damage.

In the *HCV-PTR group*, histopathological lesions

of recurrent chronic HCV hepatitis were evaluated according to the METAVIR group's algorithm, which is an example of a simple carefully evaluated method easily applicable to routine use and intra- and inter-observer variation had proved to be least⁽⁹⁾. The METAVIR algorithm for histological activity and fibrosis scores were given separately, to distinguish ongoing hepatitis from parenchymal remodelling with fibrosis.

Immunohistochemical Evaluation

Alpha-SMA positive HSCs were assessed in perisinusoidal spaces but not in portal tracts. The staining results were graded semi quantitatively as described by Schmitt-Graff *et al.*, 1991. Score 0 = no staining or occasional cells stained; Score 1 = minimal staining (stained HSC occupying approximately 1% to 10% of the sinusoidal liver cell surface); Score 2 = more cells stained (stained HSC occupying approximately 10% to 30% of the sinusoidal liver cell surface); Score 3 = extensive staining (stained HSC occupying approximately 30% to 70% of the sinusoidal liver cell surface); and score 4 = highly extensive staining (stained HSC occupying more than 70% of the sinusoidal liver cell surface).

Statistical Analysis

The collected Data was revised, verified, edited on P.C. Data, then analyzed statistically using SPSS statistical package version 15, then the following tests were done: mean, standard deviation, anova, chi square and probability.

3.Results

The age of the studied recipients ranged from 12-60 years (mean 44.7) and of the donors 23-40 years (28.4 years). The study group included 14 (82.4%) male recipients and 3 (17.6%) females; 11 (64.7%) male donors and 6 (35.3%)female donors. There was a significant higher male: female ratio among both recipients and donors groups ($p < 0.05$).

Hepatic histology

All the DL biopsies showed no abnormalities. While the HCV-C explanted liver specimens showed active cirrhosis, 29.4% (n= 5/17) being mild, 5.9 % (n=1/17) moderate, and 64.7% (n=11/17) severe. As for the HCV-PTR group, all specimens showed recurrent HCV hepatitis with low fibrosis stage (F0-F2 METAVIR score) and low activity grade (A0-A2 METAVIR score). All specimens from HCV-C showed METAVIR F4 (100%). In HCV-PTR biopsies, 47.1% were METAVIR F0, 35.3% F1, and 17.6% F2. The stage of fibrosis was significantly highest in HCV-C than HCV-PTR and DL, respectively ($P < 0.001$). In HCV-PTR group, activity grade was METAVIR A1 in 52.9%, A2 in 41.2%, and A3 in 5.9%. This showed highly significant difference in activity grade among the 3 groups ($p < 0.001$). Stage of fibrosis in subsequent biopsies in HCV-PTR was different; in

HCV-PTR 1 biopsies, 47.1% were METAVIR F0, 35.3% F1, and 17.6% F2. In HCV-PTR 2 biopsies, 18.2% were METAVIR F0, 72.7% F1, and 9.1% F2. In HCV-PTR 3; 14.3% were METAVIR F0, 57.1% F1, and 28.6% F2. The stage of fibrosis significantly progressed in successive biopsies ($p = 0.001$).

Immunohistochemical analysis of the HSC

expression of alpha-SMA

HSC grade in HCV-C was highly significant towards the more advanced grades; In HCV-PTR biopsies, HSC were highly significant towards the lower grades. Absence of HSC activation was significantly high in most of DL biopsies as outlined in table 1.

Table 1.HSC Grade in HCV-C, HCV-PTR Compared to normal DL

HSC grade	HCV-C	HCV-PTR	Donor
G0	1 (5.9%)	0 (0%)	12 (70.6%)
G1	2 (11.8%)	10(58.8%)	5 (29.4%)
G2	2 (11.8%)	3 (17.6%)	0 (0%)
G3	6 (35.3%)	3 (17.6%)	0 (0%)
G4	6 (35.3%)	1 (5.9%)	0 (0%)

X= 43.78; P= 0.0001 (highly significant)



Relationship among Immunohistochemical and histological parameters

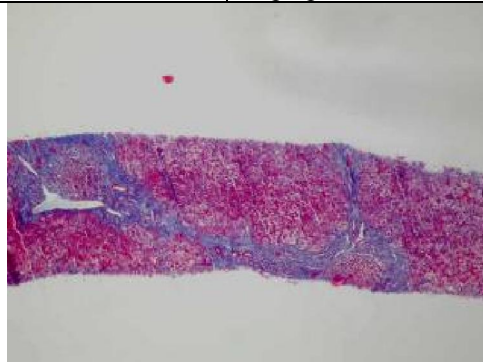
HSC grade and fibrosis stage

Within the HCV-C group (METAVIR F4), HSC grade were more towards the highest grades (i.e G3 and G4). In HCV-PTR group HSC activation preceded fibrosis. In the same specimen, HSC grade

was equivalent or greater than the stage of fibrosis. This relation was statistically highly significant ($p < 0.005$). During the follow up period, progression of the fibrosis stage was observed in those recipients who showed a HSC grade higher than the stage of fibrosis on the initial follow up biopsy (Figure 1).

HSC Grade and Activity Grade

	
The reticulin stain showing mild periportal fibrosis in only one of the portal tracts (MTx100)	Immunohistochemistry for alpha-SMA of the same biopsy demonstrating HSC activation disproportionate to fibrosis. (IHCx400).



The reticular stain of the above case showing bridging fibrosis in later biopsy. HSC activation precedes fibrotic accumulation (MTx100)

Figure 1: Showing that HSC activation preceded fibrosis.

In HCV-C, HSC grade was directly proportional to grade of activity (figure 2). Biopsies with METAVIR A3 (n=11) had significantly advanced HSC grades, G4 (n=6), and G3 (n=5). While biopsies with METAVIR A1 (n=5) had HSC G0 (n=1), G1 (n=3), and G2 (n=1). This relation was statistically significant ($p < 0.05$). In HCV-PTR group, the first biopsy in the follow up period, no significant relation was observed between grades of activity and HSC ($p > 0.05$). METAVIR A1 (n=10) had HSC G1 (n=8) and G3 (n=2). METAVIR A2 (n=7) had HSC G1 (n=2), G2 (n=3), G3 (n=1), and G4 (n=1). In DL, although their biopsies had no activity, five biopsies (5/17) had HSC G1.

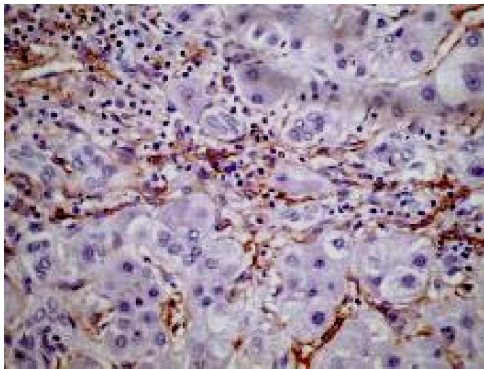


Figure 2: Activated stellate cells are located mostly in areas of inflammatory activity (IHCx400)

HSC expression with antiviral Therapy

Response to antiviral therapy was investigated in the HCV-PTR group (n=17). Two recipients did not tolerate therapy and were excluded (n=15). Nine recipients showed clinical and biochemical response (responder group=R). Six recipients did not have any

clinical or biochemical response (non-responder group=NR). Biopsies performed before and after suspending the antiviral treatment were compared in R and NR groups.

Regardless of the clinical distinction between responders and non-responders, biopsy specimens showed a significantly less severe histological activity grade after therapy than before therapy ($p < 0.05$). After therapy activity decreased from A2 (n=4) to A0 in 2 R, and A1 in 2 NR. In A1 grade (n=11), activity decreased from A1 to A0 in 5 R, did not change in 1 R and 4 NR and increased to A2 in 1 NR (Table 2).

Table 2. The stage of fibrosis detected before and after antiviral therapy.

Fibrosis before therapy	Fibrosis after therapy		
	F0	F1	F2
F0 (n=4)	2 (1NR)	0	2 (NR)
F1 (n=9)	1	7	1(NR)
F2 (n=2)	0	0	2(NR)
X= 3.792			
P= 0.150 (non-significant)			

Though histological activity was more often found improved in responders, no significant correlation was found between pathological and clinical outcome. After IFN therapy in R group a significantly lower HSC grade was detected in the second biopsy ($p < 0.001$), which correlated with the improvement in activity grade found in the same biopsy ($p < 0.05$) (Figure 3). No significant modification was observed in the histological assessment of fibrosis after therapy regardless of the clinical distinction between responders (R) and non-responders (NR).

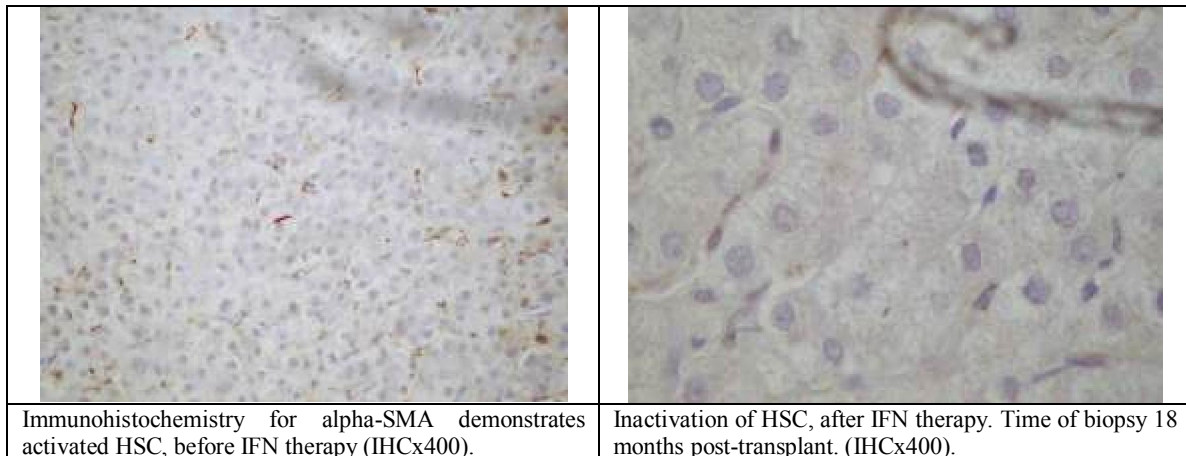


Figure 3: Showing HSC before and after antiviral therapy: HSC expression in post transplant recurrent HCV during episodes of Acute Rejection (AR)

Three (17.6%) male patients had 1-3 AR at a range of 16 days to 7 months post-transplant (4.04 ± 2 months post-transplant). Comparison between recipients with AR (Group 1 AR) and recipients without AR (Group 2 non-AR) showed similar results for all the general transplantation related parameters: type of surgery, postoperative monitoring, and immunosuppressant regimens. Histological, rejection activity index (RAI) values ranged from 3-5. Immunohistochemically, the HSC grade in group 2 was greater than group 1. After AR in allograft with HCV-PTR, HSC grade increases in follow up biopsies. No relationship between rejection and the stage of fibrosis. No statistical differences were noted in the number of episodes of rejection, increased HSC activation and time of post-transplantation biopsy.

4. Discussion

Fibrosis is a key histological feature in chronic hepatitis useful for evaluation of severity of the disease, for treatment decisions, and for assessing drug efficacy. Our series adds to the understanding of recurrent hepatitis C after liver transplantation. Although the number of patient is small, we have a relatively pure population of patient with recurrent HCV in whom the natural history of infection can be carefully studied. Post-transplantation HCV re-infection represents a human model of the earlier stage of fibrosis,^(10,7) which is very useful because we exactly know the moment of the infection. HSC are the principal cells involved in fibrogenesis in chronic liver disease⁽⁷⁾. The presence of few alpha-SMA-positive HSCs is consistent with a normal-appearing liver histology. This was in accordance to previous studies^(7,11-18). The present study showed that expansion of alpha-SMA positive HSCs was an early event in human viral hepatitis, occurring during the early phase and related to cirrhotic evolution. This is evident by the grade of alpha-SMA HSCs that was higher in the HCV-C group and HCV-PTR group, when compared to the DL group. Previous study⁽¹³⁾ concluded from this same findings that it provides an indirect '*in vivo*' evidences that HSC activation is a key factor in the natural history of human HCV chronic liver disease and that it precedes fibrotic hepatic accumulation. In our study, in HCV-PTR group, HSC grade was equivalent or greater than the stage of fibrosis, suggesting that HSC activation preceded fibrotic tissue accumulation. The present study also demonstrated that patients with minimal or no fibrosis had lower HSC activity, HSC activity was increased in recipients who subsequently developed bridging fibrosis or cirrhosis (Figure1). The number of alpha-SMA-positive HSC in HCV recurrence after transplantation is related to a subsequent cirrhotic

evolution. This agrees with the findings of several other studies^(13,19-22). Hepatic inflammation is usually associated with the progression of liver fibrosis⁽²³⁾. A study⁽¹⁰⁾ showed that the change of histology activity index score (HAI) score after interferon (IFN) therapy, which has an anti-inflammatory action, had correlated with alpha-SMA index. This supports the possibility that proliferation and differentiation of stellate cells is stimulated by necro-inflammation. In the current study, HSC immunoreactivity was topographically observed in close association with necro-inflammatory areas (Figure 2). However, the absence of statistical differences between severe inflammation and increased expression of HSCs observed in the first biopsy post-transplant in our series might be related to autocrine effects. Inhibiting the activation of HSC is a key point to regulate fibrotic progression. Antioxidant therapy, cytokines and signal-transduction based therapies are effective therapeutic approach for inhibiting the activation of HSC. Anti-inflammatory agents, beside the above mentioned therapeutic approaches are effective in regulating fibrotic progression. However testing a potential inhibitor of hepatic fibrosis in clinical trials represents unique challenges⁽²³⁾, since a clinical benefit may only be apparent after a prolonged period of treatment⁽²⁴⁾. In our study the drop in alpha-SMA-expressing HSCs was significant after therapy (Figure 3). This effect seems comparable with that of IFN, which has proved capable of strongly inhibiting HSC proliferation and alpha-SMA expression in experimental models²⁵.

Previous reports^(26,27) have suggested that INF therapy may have an anti-fibrogenic effect, though in other studies^(28,29) it has failed to modify the histological score for fibrosis. The previous results were in accordance to our study in which IFN therapy did not decrease the stage of fibrosis during the follow up period. Fibrosis decreased in only one biopsy. However, this was explained by the fact that fibrosis is patchy. Our finding of increased expression of HSC in acute rejection speculated that HSCs may play a role, shared with sinusoidal endothelial cells (SECs) and Kupffer cells, in the clearance of foreign antigens that occurs during allograft rejection. Further, a study⁽³⁰⁾ concluded that they might express antigen-presenting cells which probably contribute to hepatic immune surveillance in the post-transplantation period. This was in agreement with previous studies by^(13,17). If further research proves that HSCs are a protective factor in episodes of acute rejection (AR), activation of HSCs may be a valuable method to treat AR in hepatic allograft patients⁽¹⁷⁾. HSC grade increases following AR. These patients may be of higher risk for fibrosis

progression. Clearly, the association between rejection and recurrent hepatitis C after transplantation needs further study. In conclusion, HSC activation and proliferation precede fibrosis, and it may be that patients with increased HSC relative to fibrosis are at risk for disease progression. As a consequence, alpha-SMA expression could have a prognostic role also in the follow-up after liver transplantation. However longitudinal studies would be needed to investigate this possibility. The presence of activated HSCs and the lack of histologically discernible fibrosis necessitate the start of treatment. Inactivation of HSC monitors the success of therapy⁽¹⁷⁾.

References:

1. Hoofnagle JH. (1997): Hepatitis C: The clinical spectrum of disease. *Hepatology*; 26(Suppl 1):S15-20.
2. Alter HJ, Seeff LB. (2001): Recovery, persistence, and sequelae in HCV infection. A perspective on long-term outcome. In: Stramer SL, editor. *Blood safety in the new millennium*. Bethesda MD: American Association of Blood Banks; p. 123–66.
3. Pungpapong S, Nunes DP, Krishna M, Nakhleh R, Chambers K, Ghabril M, Dickson RC, Hughes CB, Steers J, Nguyen JH, Keaveny AP. (2008). Serum fibrosis markers can predict rapid fibrosis progression after liver transplantation for hepatitis C. *Liver Transpl*. 2008 Sep;14(9):1294-302.
4. Rodriguez-Luna H, Vargas HE, (2004): Natural history of hepatitis C and outcomes following liver transplantation. *Minerva Gastroenterol Dietol*. 50(1):51-9.
5. Lotersztajn S, Julien B, Teixeira-Clerc F, Grenard P, Mallat A.(2005): Hepatic fibrosis: molecular mechanisms and drug targets. *Annu Rev Pharmacol Toxicol*. 2005;45:605-28. Review
6. Ghavami S, Hashemi M, Kadkhoda K, Alavian SM, Bay GH, (2005): Apoptosis in liver diseases - detection and therapeutic applications. *Los M.Int J Biochem Cell Biol*. Sep 23.
7. Carpino G, Morini S, Ginanni Corradini S, Franchitto A, Merli M, Siciliano M, Gentili F, Onetti Muda A, Berloco P, Rossi M, Attili AF, Gaudio E. (2005): Alpha-SMA expression in hepatic stellate cells and quantitative analysis of hepatic fibrosis in cirrhosis and in recurrent chronic hepatitis after liver transplantation. *Dig Liver Dis*.;37(5):349-356
8. Crawford J.M. (2002): *Liver cirrhosis. Pathology of liver*, 4th edn. London: Churchill Livingstone, pp 575-619.
9. Bedossa P, Poynard T. (1996): The METAVIR cooperative study group for grading of activity in chronic hepatitis C. *Hepatology*; 24:289-293.
10. Schmitt-Graff A, Kruger S, Bochar F (1991): Modulation of alpha smooth muscle actin and desmin expression in perisinusoidal cells of normal and diseased human livers. *Am J Pathol* 138:1233- 1242.
11. Sakaida I., Nagatomi A., Hironaka K., Uchida K. and Okita K. (1999): Quantitative analysis of liver fibrosis and stellate cell changes in patients with chronic hepatitis C after interferon therapy, *Am J Gastroenterol* 94, 489–496.
12. Yamaoka K., Nouchi T., Marumo F. and Sato C. (1993): Alpha-smooth-muscle actin expression in normal and fibrotic human livers, *Dig Dis Sci* 38, pp. 1473–1479.
13. Enzan H., Himeno H., Iwamura S., Saibara T., Onishi S. and Yamamoto Y. (1994): immunohistochemical identification of Ito cells and their myofibroblastic transformation in adult human liver, *Virchows Arch* 424, 249–256.
14. Guido M, Rugge M, Chemello L, Fattovich G, Giustina G, Cassaro M, Alberti A. (1996): Liver stellate cells in chronic viral hepatitis: The effect of interferon therapy. *J Hepatol*; 24: 301–7.
15. Isao Sakaida, Atsuko Nagatomi, Koji Hironaka, Koichi Uchida, and Kiwamu Okita (1999): Quantitative Analysis of Liver Fibrosis and Stellate Cell Changes in Patients With Chronic Hepatitis C After Interferon Therapy. *Am J Gastroenterol*. Feb;94(2):489-96
16. Washington K, Wright K, Shyr Y, Hunter EB, Olson S, Raiford DS. (2000): Hepatic Stellate Cell Activation in Nonalcoholic Steatohepatitis and Fatty Liver. *Hum Pathol*. Jul;31(7):822-8.
17. Douglas D. (2005): Stellate Cells Predict Transplanted Liver Cirrhosis Risk, *Liver Transpl*;11:1235-1241.
18. Bilezikçi B, Demirhan B, Sar A, Arat Z, Karakayalı H, Haberal M (2006): Hepatic Stellate Cells in Biopsies From Liver Allografts With Acute Rejection Transplantation *Proceedings*, 38, 589–593.
19. Guyot C, Lepreux S, Combe C, Doudnikoff E, *et al.* (2006): Hepatic fibrosis and cirrhosis: The (myo)fibroblastic cell subpopulations involved. *The International Journal of Biochemistry & Cell Biology* 38:135–151.
20. Demetris A J, Murase N, Nakamura K. (1992): Immunopathology of antibodies as effectors of orthotopic liver allograft rejection. *Sem Liver Dis*; 12: 51-59.
21. Verslype C, Nevens F, Sinelli N, Clarysse C, Pirenne J, Depla E, Maertens G, van Pelt J, Desmet V, Fevery J, Roskams T. (2003):

- Hepatic immunohistochemical staining with a monoclonal antibody against HCV-E2 to evaluate antiviral therapy and reinfection of liver grafts in hepatitis C viral infection. *J Hepatol*; 38(2):208-14.
22. Gawrieh S, Papouchado BG, Burgart LJ, Kobayashi S, Charlton MR, Gores GJ.(2005): Early hepatic stellate cell activation predicts severe hepatitis C recurrence after liver transplantation. *Liver Transpl.*; 11(10):1207-13.
 23. Cisneros L, Londoño MC, Blasco C, Bataller R, Miquel R, Bruguera M, Ginès P, Rimola A. : Hepatic stellate cell activation in liver transplant patients with hepatitis C recurrence and in non-transplanted patients with chronic hepatitis C. *Liver Transpl.* 2007 Jul;13(7):1017-27.
 24. Russo et al (2005). Russo MW, Firpi RJ, Nelson DR, Schoonhoven R, Shrestha R, Fried MW. Early hepatic stellate cell activation is associated with advanced fibrosis after liver transplantation in recipients with hepatitis C. *Liver Transpl.* 2005 Oct;11(10):1235-41.
 25. Tsukada S, Parsons C, Rippe R (2006): Mechanisms of liver fibrosis. *B. Clinica Chimica Acta*; 364, 33 – 60.
 26. Pinzani M, Rombouts K (2004): Liver fibrosis: from the bench to clinical targets. *Dig Liver Dis*; 36:231–242
 27. Baroni G.S., D'Ambrosio L. and Curto P. (1996): Interferon- γ decreases hepatic stellate cell activation and extracellular matrix deposition in rat liver fibrosis, *Hepatology* 23, 1189–1199.
 28. Queneau PE, Osaer F, Bronowicki JP, Monnot B, Thieffin G, Bettinger D, Carbillet JP, Raabe JJ, Fratte S, Minello-Franza A, Bresson-Hadni S, Miguet JP. (2001): Treatment of mild chronic hepatitis C with interferon alpha-2b: results of a multi-centre randomized study in 80 patients. *Eur J Gastroenterol Hepatol.* Feb;13(2):143-7.
 29. Verslype C, Nevens F, Sinelli N, Clarysse C, Pirenne J, Depla E, Maertens G, van Pelt J, Desmet V, Fevery J, Roskams T. (2003): Hepatic immunohistochemical staining with a monoclonal antibody against HCV-E2 to evaluate antiviral therapy and reinfection of liver grafts in hepatitis C viral infection. *J Hepatol*; 38(2):208-14.
 30. Gento Pena EG, Lopez Morante A, Cordero Guevara J, Echevarria Iturbe C, Martin Lorente JL, Olcoz Goni JL, Gonzalez San Martin F, Caro-Paton Gomez A, Jorquera Plaza F, Velicia Llamas R, Saez-Royuela F. (2001): Sociedad Castellano-Leonesa para El Estudio de las Enfermedades Hepaticas. [The histological lesions of chronic hepatitis C as predicting factors of sustained response to the treatment with interferon] *An Med Interna.* Jul; 18(7):351-6.
 31. Oton E, Barcena R, Moreno-Planas JM, Cuervas-Mons V, Moreno-Zamora A, Barrios C, Garcia-Garzon S, Moreno A, Boullosa-Grana E, Rubio-Gonzalez EE, Garcia-Gonzalez M, Blesa C, Mateos ML. (2006): Hepatitis C recurrence after liver transplantation: Viral and histologic response to full-dose PEG-interferon and ribavirin. *Am J Transplant.* 2006 Oct;6(10):2348-55. Epub Jul 26.
 32. Nedredal G.I., Elvevold K.H. and Ytrebo L.M. (2003): Liver sinusoidal endothelial cells represent an important blood clearance system in pigs, *Comp Hepatol* 2, 1.

11/12/2013