

**Effect of Allium Sativum Extract on Serum Lipid and Antioxidant Status in hypercholesterolemic Rabbits**

Amal, A. Fyiad and Sanaa, T. El- Sayed

Department of Biochemistry, Division of Genetic Engineering and Biotechnology, National Research Centre, Cairo, Egypt

[amalfiyad@yahoo.com](mailto:amalfiyad@yahoo.com)

**Abstract:** The present study was conducted to investigate the lipid-lowering and antioxidative activities of aqueous garlic extract (AGE, 1 ml/Kg, orally, corresponding to 500 mg/Kg/ day) in heart and liver tissues of rabbits fed with high-cholesterol diet. Twenty-eight male white New Zealand rabbits were divided into four groups, 7 rabbits each. The first one, group 1, served as a control, group 2 (hypercholesterolemic group), rabbits fed (2% cholesterol enriched diet) for 4 weeks, group 3, (aqueous garlic extract AGE), rabbits were given orally aqueous garlic extract (500mg/Kg b.w/ day) for 4 weeks, group 4, rabbits fed 2% cholesterol- enriched diet in conjunction with AGE (500 mg/Kg b.w / day) orally for the same period. At the end of the feeding period, rabbits were fasted over night and slaughtered and blood and tissue samples were taken for biochemical and histopathological studies. Obtained results showed that AGE suppressed the high levels of serum lipid profile including total cholesterol, low density lipoprotein cholesterol, and triglycerides, while it increased the concentration of high density lipoprotein cholesterol. The high serum activities of aspartate aminotransferase, alanine aminotransferase, alkaline phosphatase as well as creatin kinase and lactate dehydrogenase significantly decreased in high-cholesterol rabbits treated with AGE. AGE lowered the high level of cardiac and hepatic lipid peroxidation and raised the low activities of catalase, superoxide dismutase and glutathione peroxidase in both the cardiac and hepatic tissues. Histopathological examinations revealed that AGE preserved myocardial and hepatic tissues. It can be concluded that bioactive compounds containing in aqueous garlic extracts might be responsible for both lipid- lowering and antioxidative actions to protect the heart and liver from hypercholesterolemia.

[Amal, A. Fyiad and Sanaa, T. El- Sayed **Effect of Allium Sativum Extract on Serum Lipid and Antioxidant Status in hypercholesterolemic Rabbits**. Life Sci J 2012;9(3):187-196]. (ISSN: 1097-8135). <http://www.lifesciencesite.com>. 28

**Key words:** Garlic; enzymes; hypercholesterolemia; antioxidant activity; rabbits; histopathology.

**1. Introduction**

Cardiovascular diseases, particularly coronary heart disease have become a growing problem, especially in developing countries. Hypercholesterolemia is widely known as a dominant risk factor for the development of cardiovascular diseases [1,2]. It has been reported that oxidative stress induced by reactive oxygen species, plays an important role in the etiology of several diseases including atherosclerosis and coronary heart disease [3]. Hyperlipidemia has also been found to induce oxidative stress in various organs such as the liver, heart, and kidney [4,5]. To lower high blood cholesterol, a number of lifestyle changes are recommended including smoking cessation, limiting alcohol consumption, increased physical activity and diet control [6]. However, most people could not successfully control their blood cholesterol because of the modern life style. Therefore, medication is considered their last choice which have been reported to have serious adverse effects, particularly liver damage [7]. Moreover, they lack several desirable properties such as efficacy and safety on long-term use, cost, and simplicity of administration. These factors do not fulfill conditions for patients' compliance. So, attention is being directed to the medicines of natural origin with hypolipidemic activity. There are several

kinds of medicinal plants that contain antioxidant and lipid-lowering effect since they are enriched of bioactive compounds that might be effective therapy, safe, and cheap. Among them garlic (*Allium sativum*, family: *Liliaceae*).

Garlic is well known for its medicinal benefits, especially in helping to prevent cancer and cardiovascular diseases [8]. Alliins (S-alk(en)yl-L-cysteine sulfoxides) are sources of major active compounds in allium plants. Allicin (diallylthiosulfinate) is the main biologically active component of aqueous garlic extract [9]. Garlic and its compounds which have been reported to have diverse biological activities such as regulating plasma lipid levels, anticarcinogenic, lead and mercury detoxification, antithrombotic, antibacterial, antioxidant, antihypertensive, antidiabetic, and various other biological actions [10-12].

Its variety of preparations are widely used as therapeutically effective medicament for cardiovascular diseases. Consumption of garlic and cardiovascular disease progressions is inversely correlated [13]. Furthermore, garlic has significant antiarrhythmic effect in both ventricular and supraventricular arrhythmias [14]. It is reported that chronic use of garlic in moderate doses augments the

endogenous antioxidants activities and depletes the oxidative damaging effects by either increasing the synthesis of endogenous antioxidants or decreasing the generation of oxidants like oxygen free radicals [15]. Therefore, the present study aimed to investigate lipid-lowering and antioxidative activities of aqueous garlic extract in heart and liver tissues of rabbits fed a diet rich in cholesterol.

## 2. Materials and Methods:

### 1 -Chemicals

Cholesterol (extra pure, powdered; merck,Darmstadt, Germany). Garlic (*A. Sativum*, family: *Lilliaceae*) bulbs were purchased from the local vegetable market (Cairo, Egypt). The cloves were peeled .Peeled garlic (30g) was crushed with distilled water in a mortar. The crushed material was carefully decanted by pressing and 60 ml of aqueous extract was extracted. One milliliter of aqueous extract contained 500 mg of garlic materials [16].

All other chemicals that required for the biochemical assays were of highest purity and analytical grade and purchased from Sigma –Aldrich Chemic (Deisenhofen , Germany).

### 2- Experimental animals

Twenty-eight male white New Zealand rabbits of about 1000 -1200 g body weight, bred in the Animal House Colony of The National Research Centre, Dokki, Cairo, Egypt. Animals were allowed 7 days for acclimatization at 24°C with 12 hr light – dark cycle and fed standard laboratory diet and water *ad libitum* before the experiment. Animal procedures were performed in accordance with Guidelines for Ethical Conduct in the Care and Use of Animals.

### 3-Experimental design

After one week of acclimation, animals were then divided into four groups of rabbits each of seven **Group 1** (control group): rabbits fed a plain chow diet. **Group 2**(hypercholesterolemic group): rabbits fed (2 % cholesterol enriched diet) for 4 weeks. **Group 3** :( Aqueous garlic extract AGE) : rabbits were given orally aqueous garlic extract (500 mg /Kg b.w ) daily by stomach tube for 4 weeks, [16]. **Group 4**: rabbits were fed 2% cholesterol – enriched diet in conjunction with AGE (500 mg /Kg b.w / day) orally for 4 weeks.

### 4- Blood collection and tissue homogenate

At the end of experimental feeding, food was withheld for 16- 18 hr. Blood samples were then withdrawn from marginal ear viens and serum was separated by centrifugation at 3000 rpm. The serum was used for estimation of total cholesterol (TC), high density lipoprotein cholesterol (HDL-C), low density lipoprotein cholesterol (LDL-C) and triglycerides (TG). Also, serum was used for determination of aspartate aminotransferase (AST), alanine aminotransferase (ALT), alkaline phosphatase (ALP), lactate dehydrogenase (LDH) and creatin kinase (CK).

After that, the animals were slaughtered and their livers and hearts were dissected out immediately and weighted, portions of them were preserved in 10% formalin (pH 7.2) and subjected to histopathological examination. The remaining parts of livers and hearts immediately homogenized in 50 mM ice-cold phosphate buffer (pH 7.4) to give 20% homogenate (w/v) (Lin et al., 1998). The homogenates were centrifuged at 1700 rpm and 4°C and the supernatants (20%) were used for the determination of cardiac and hepatic lipid peroxidation. Further diluted with phosphate buffer solution were done for the determination of cardiac and hepatic catalase (0.5%), superoxide dismutase (0.5%) and glutathione peroxidase (2%) activities.

### Biochemical analysis:

Serum TC, HDL-C, LDL-C and TG were estimated spectrophotometrically by the methods of [17-20], respectively using commercially available kits obtained from Stanbio Laboratory(USA). Serum ALT and AST activities were measured by the dinitrophenylhydrazene (DNPH) method according to [21] using commercial kits from Stanbio Laboratory (USA). Alkaline phosphatase, CK and LDH activities in serum were estimated by the method of [22-24], respectively using commercial kits from Stanbio Laboratory (USA). Cardiac and hepatic lipid peroxidation were assayed by the measurement of malondialdehyde (MDA) by spectrophotometric method [25] using commercial kits from Roche Diagnostics Kits (Germany). The level of lipid peroxidation was expressed as nmol/g.tissue. Cardiac and hepatic catalase (CAT) activities were carried out spectrophotometrically by the modified method of [26] using 50 ul diluted cardiac and hepatic homogenates. Cardiac and hepatic superoxide dismutase (SOD) activities were determined spectrophotometrically as the ability of the enzyme to inhibit the phenazine methosulphate- mediated reduction of nitroblue tetrazolium dye by the method of [27] using 50 µl diluted cardiac and hepatic homogenates. Cardiac and hepatic glutathione peroxidase (GPx) activities were assayed by spectrophotometric method using reduced glutathione and cumene hydroperoxide as substrate using 20µl diluted cardiac and hepatic homogenates by the modified method of [28]. Reagent kits for determination of cardiac and hepatic CAT,SOD and GPx activities were purchased from Roche Diagnostics kits (Germany). The specific activities of cardiac and hepatic catalase, superoxide dismutase and glutathione peroxidase were expressed as units/g heart or liver tissue.

### Assessment o f heart and liver damage:

Samples of the heart and liver from all animals were fixed in 10% neutral formalin and embedded in

paraffin blocks. Sections (4  $\mu$ m thickness) were stained with hematoxylin and eosin (H&E) and examined microscopically for detection of histopathological alteration [29].

#### Statistical analysis:

Data were expressed as mean  $\pm$ S.E. The data were analyzed by an analysis of variance (ANOVA) and the level of significance was determined by Duncan's multiple range tests [30], to clarify the significant between the individual groups. *P* values less than 0.05 were considered significant. Results were processed by the computer programs.

#### 3. Results:

As shown in table (1); two percent cholesterol diet supplementation for four weeks resulted in a significant elevation ( $P < 0.001$ ) of serum TC, HDL-C, LDL-C and TG by (1479, 192, 4031.5 and 329.9 % respectively) compared to the control group. Meanwhile, the combined treatment with (AGE+cholesterol) resulted in lowering the concentration ( $P < 0.05$  and  $P < 0.01$ ) of serum TC, LDL-C and TG by (52.3, 52.8 and 38.02%) and elevating the concentration ( $P < 0.05$ ) of HDL-C by 15.8% compared to the hypercholesterolemic rabbits group. Moreover, our results showed that groups treated with AGE only revealed non-significant changes ( $P > 0.05$ ) in these parameters compared to control group.

As shown in table (2); there was a significant increase ( $P < 0.001$ ) in serum CK and LDH activities by (246.1 and 230%) compared to the control group indicating the severity of cardiac injury caused by cholesterol enriched diet. Treatment with (AGE+cholesterol) significantly attenuated elevation ( $P < 0.05$  and  $P < 0.01$ ) of these enzymes compared to the hypercholesterolemic group. However, there were no changes in the activity of heart enzymes in rabbits treated with AGE alone compared to the control group ( $P > 0.05$ ).

As shown in table (3); the activity of AST, ALT and ALP were significantly ( $P < 0.01$ ) increased by (23.45,

50 and 22% respectively) in cholesterol group compared to the control group indicating the severity of hepatic injury caused by cholesterol enriched diet. Treatment with AGE alone resulted in no change in the activities of liver enzymes compared to the control group. The activity of the above enzymes were significantly ( $P < 0.01$ ) reversed in groups treated with (AGE+cholesterol) compared to the cholesterol group.

#### Heart and liver stress and antioxidant enzymes activity:

Malondialdehyde (MDA) level is widely used as a marker of free radical mediated lipid peroxidation injury. As shown in table (4) and (5); cardiac and hepatic MDA levels in cholesterol groups were significantly ( $P < 0.001$ ) higher by 99.2 and 118.5 respectively, than those in the control group. Treatment with AGE alone resulted in no changes in the levels of cardiac and hepatic MDA compared to the control group. The levels of MDA in different tissues in the groups treated by (AGE + cholesterol) were significantly lower by 42.5 and 57.5 ( $P < 0.01$ ) than those in the cholesterol groups.

Cardiac and hepatic CAT, SOD and GPx activities were measured as an index of antioxidant status of cardiac and hepatic tissues. Tables (4 and 5) illustrated that in comparison with the control group, there was significant decrease ( $P < 0.01$ ) in all antioxidant enzyme activities in both heart and liver in cholesterol groups. The activity of CAT decreased by 52.3 and 42.9 %; SOD activity decreased by 37.7 and 43.6 %; GPx decreased by 53.2 and 32.3 % in both heart and liver tissues respectively. While there were significant increase ( $P < 0.05$ ,  $P < 0.01$ ) in cardiac and hepatic CAT, SOD and GPx activities in the groups treated by (AGE+cholesterol) compared to the hypercholesterolemic groups. Treatment with AGE alone resulted in insignificant increase in cardiac and hepatic CAT, SOD and GPx activities compared to the control group.

Table (1): Effect of aqueous garlic extract (AGE) and cholesterol on serum lipid in male rabbits

Groups	Parameters	Total cholesterol (mg/dl)	High density lipoprotein cholesterol (mg/dl)	Low density lipoprotein cholesterol (mg/dl)	Triglycerides (mg/dl)
Control		60.48 $\pm$ 26.20 <sup>a</sup>	16.3 $\pm$ 3.40 <sup>a</sup>	5.4 $\pm$ 3.10 <sup>a</sup>	77.6 $\pm$ 21.01 <sup>a</sup>
AGE		64.12 $\pm$ 18.10 <sup>a</sup>	17.5 $\pm$ 5.10 <sup>a</sup>	6.7 $\pm$ 1.20 <sup>a</sup>	73.9 $\pm$ 18.90 <sup>a</sup>
Cholesterol		955.30 $\pm$ 85.60 <sup>b***</sup>	47.6 $\pm$ 12.60 <sup>b***</sup>	223.1 $\pm$ 15.4 <sup>b**</sup>	333.6 $\pm$ 55.61 <sup>b**</sup>
AGE + cholesterol		455.30 $\pm$ 63.10 <sup>c**</sup>	55.1 $\pm$ 23.50 <sup>c*</sup>	105.2 $\pm$ 4.10 <sup>c**</sup>	206.81 $\pm$ 62.07 <sup>c*</sup>

Each value represent the mean  $\pm$  S.E (n = 7).

Within each column, means superscript with the same letter are not significantly different. \* $P < 0.05$ , \*\* $P < 0.01$  and \*\*\* $P < 0.001$

(b) Significantly different from control group, (c) Significantly different from cholesterol group.

Table (2): Effect of aqueous garlic extract (AGE) and cholesterol on serum enzymes activities of heart in male rabbits

Groups	Parameters	Creatin kinase (U/L)	Lactate dehydrogenase (U/L)
Control		115.41 $\pm$ 11.02 <sup>a</sup>	165.75 $\pm$ 25.45 <sup>a</sup>
AGE		122.13 $\pm$ 12.33 <sup>a</sup>	171.45 $\pm$ 10.24 <sup>a</sup>
Cholesterol		399.51 $\pm$ 120.16 <sup>b***</sup>	548.08 $\pm$ 150.73 <sup>b***</sup>
AGE + cholesterol		175.42 $\pm$ 20.55 <sup>c*</sup>	230.27 $\pm$ 23.78 <sup>c**</sup>

Each value represent the mean  $\pm$  S.E (n = 7).

Within each column, means superscript with the same letter are not significantly different. \*P < 0.05, \*\*P < 0.01 and \*\*\*P < 0.001 (b) Significantly different from control group, (c) Significantly different from cholesterol group.

**Table (3): Effect of aqueous garlic extract (AGE) and cholesterol on serum enzymes activities of liver in male rabbits**

Parameters Groups	Aspartate aminotransferase (U/ml)	Alanine aminotransferase (U/ml)	Alkaline phosphatase (U/ml)
Control	30.75 $\pm$ 4.95 <sup>d</sup>	29.61 $\pm$ 6.15 <sup>d</sup>	121.3 $\pm$ 4.72 <sup>d</sup>
AGE	34.12 $\pm$ 5.22 <sup>a</sup>	33.11 $\pm$ 7.20 <sup>a</sup>	123.4 $\pm$ 2.63 <sup>a</sup>
Cholesterol	92.51 $\pm$ 12.24 <sup>b***</sup>	81.46 $\pm$ 6.15 <sup>b***</sup>	311.1 $\pm$ 12.4 <sup>b***</sup>
AGE + cholesterol	46.44 $\pm$ 7.58 <sup>c**</sup>	53.62 $\pm$ 2.39 <sup>c**</sup>	269.3 $\pm$ 8.21 <sup>c**</sup>

Each value represent the mean  $\pm$  S.E (n = 7).

Within each column, means superscript with the same letter are not significantly different. \*\*P < 0.01 and \*\*\*P < 0.001

(b) Significantly different from control group, (c) Significantly different from cholesterol group.

**Table (4): Effect of aqueous garlic extract (AGE) and cholesterol on some antioxidant / oxidative markers in cardiac tissue of male rabbits .**

Parameters Groups	Malondialdehyde ( nmol/g tissue)	Catalase (U/g tissue)	Superoxide dismutase (U/g tissue)	Glutathione peroxidase (U/g tissue)
Control	63.11 $\pm$ 1.40 <sup>a</sup>	1052 $\pm$ 50.2 <sup>a</sup>	204.12 $\pm$ 21.30 <sup>a</sup>	66.4 $\pm$ 3.02 <sup>a</sup>
AGE	61.33 $\pm$ 2.34 <sup>a</sup>	1080 $\pm$ 30.11 <sup>a</sup>	213.14 $\pm$ 18.20 <sup>a</sup>	79.1 $\pm$ 6.35 <sup>a</sup>
Cholesterol	125.72 $\pm$ 1.81 <sup>b***</sup>	501.70 $\pm$ 15.30 <sup>b**</sup>	127. $\pm$ 10.50 <sup>b**</sup>	31.15 $\pm$ 1.61 <sup>b**</sup>
AGE + cholesterol	72.22 $\pm$ 1.23 <sup>c**</sup>	520.15 $\pm$ 9.04 <sup>c*</sup>	164.55 $\pm$ 8.30 <sup>c*</sup>	45.11 $\pm$ 3.18 <sup>c*</sup>

Each value represent the mean  $\pm$  S.E (n = 7).

Within each column, means superscript with the same letter are not significantly different. \*P < 0.05, \*\*P < 0.01 and \*\*\*P < 0.001

(b) Significantly different from control group, (c) Significantly different from cholesterol group.

**Table (5): Effect of aqueous garlic extract (AGE) and cholesterol on some antioxidant / oxidative markers in hepatic tissue of male rabbits**

Parameters Groups	Malondialdehyde (nmol/g tissue)	Catalase (U/g tissue)	Superoxide dismutase (U/g tissue)	Glutathione peroxidase (U/g tissue)
Control	21.01 $\pm$ 2.03 <sup>d</sup>	2014 $\pm$ 81.3 <sup>a</sup>	380 $\pm$ 25.1 <sup>a</sup>	82.04 $\pm$ 5.20 <sup>a</sup>
AGE	23.9 $\pm$ 1.52 <sup>a</sup>	2094 $\pm$ 97.1 <sup>a</sup>	400 $\pm$ 16.7 <sup>a</sup>	95.59 $\pm$ 8.83 <sup>a</sup>
Cholesterol	45.9 $\pm$ 7.18 <sup>b***</sup>	1150 $\pm$ 70.40 <sup>b**</sup>	214 $\pm$ 11.6 <sup>b**</sup>	55.52 $\pm$ 4.51 <sup>b**</sup>
AGE+cholesterol	19.51 $\pm$ 1.02 <sup>c**</sup>	1431 $\pm$ 60.8 <sup>c*</sup>	341 $\pm$ 13.4 <sup>c**</sup>	63.48 $\pm$ 7.97 <sup>c*</sup>

Each value represent the mean  $\pm$  S.E (n = 7).

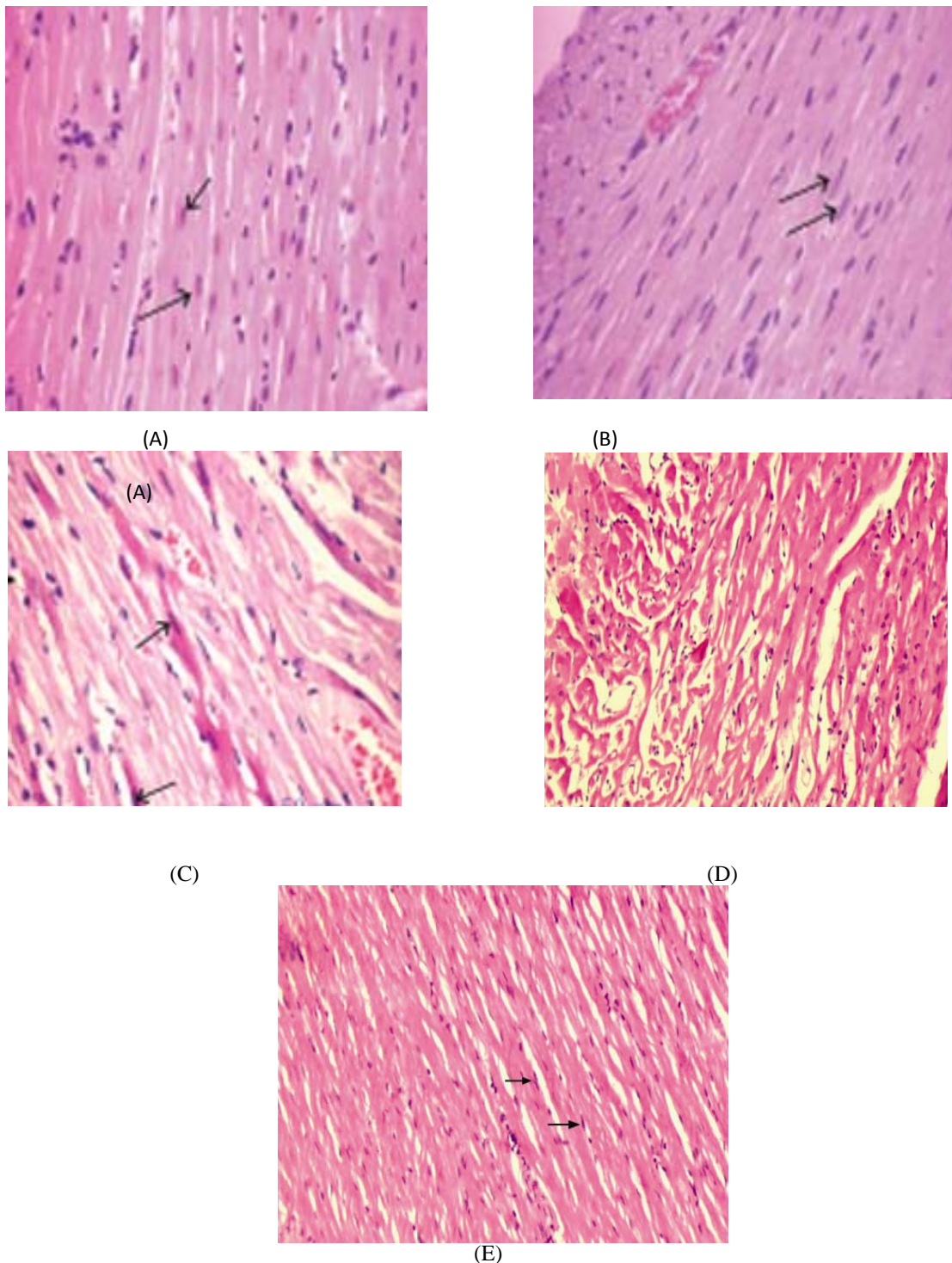
Within each column, means superscript with the same letter are not significantly different. \*P < 0.05, \*\*P < 0.01 and \*\*\*P < 0.001

(b) Significantly different from control group, (c) Significantly different from cholesterol group.

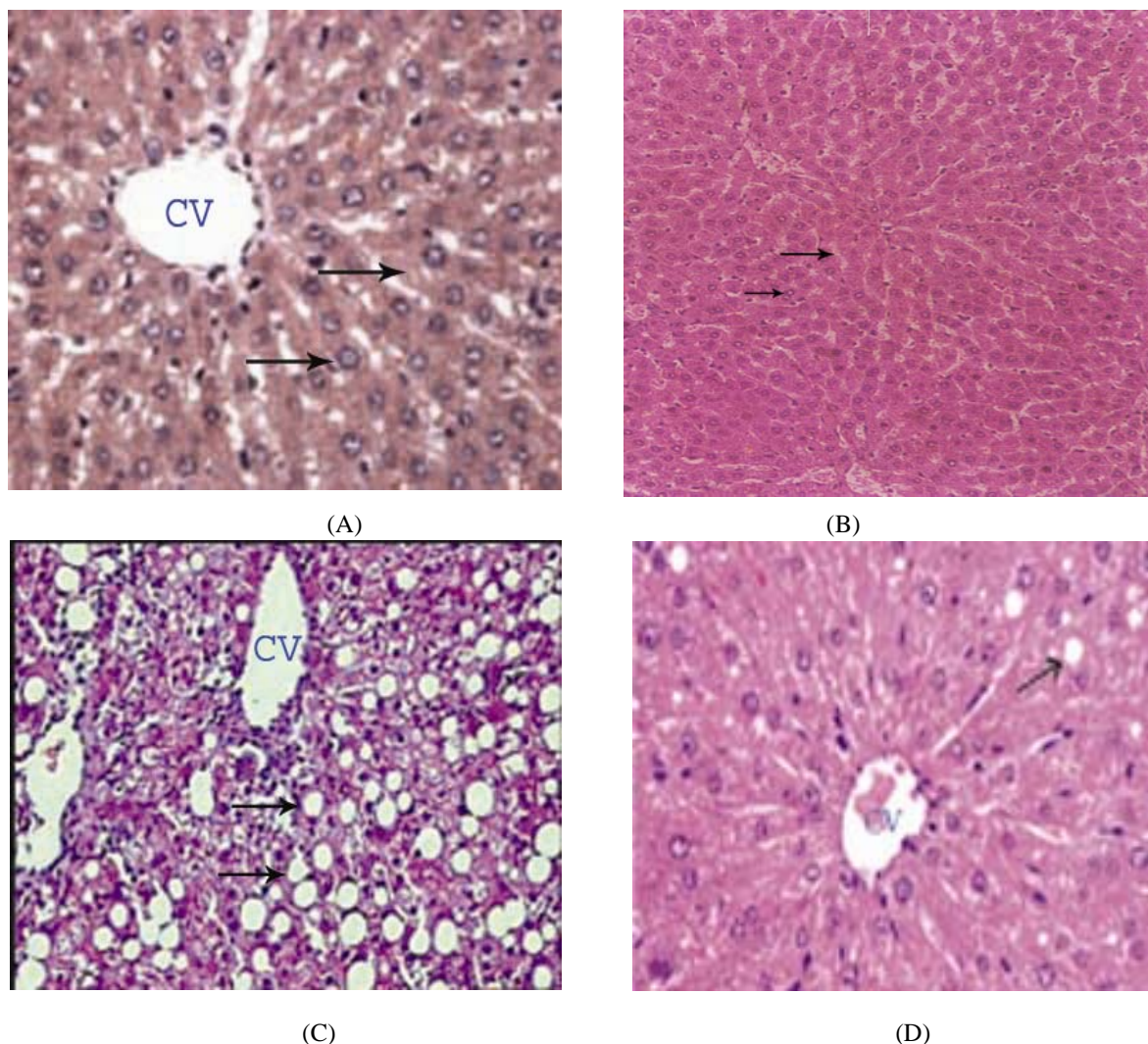
### Histopathological examination:

The histological examination of rabbit heart sections as shown in **Fig.1.(A)**: Heart of a control rabbit showing normal striated muscles. Oval elongate nucleus centrally (arrows) and homogeneous cytoplasm in normal myocardial cells. (B): Heart sections of rabbit treated with AGE (500 mg/Kg b.wt) orally once daily for four weeks showing structure as seen in control. (C,D): Heart sections of a rabbit fed with high – cholesterol diet (2% cholesterol) demonstrating multi-focal vacuolar degeneration (arrows) and necrosis of myocardial cells as well as separation of cardiac muscle bundles. (E): Heart of a rabbit treated with AGE plus cholesterol showing better- preserved appearance of myocardial cell morphology with oval – elongate nucleus centrally (arrows) and homogeneous cytoplasm. Also, the histological examination of rabbit

liver sections as shown in **Fig.2. (A)**: Liver of a control rabbit showing normal hepatocytes architecture. Hepatocyte had the round nucleus centrally (arrows) the flat endothelial cells are around the central vein (CV). (B): Liver of rabbit treated with AGE (500 mg /Kg b. wt) orally once daily for four weeks, showing normal hepatocytes architecture. (C): Liver section of rabbit fed with high-cholesterol diet (2% cholesterol) demonstrating diffuse vacuolar degeneration fat vacuoles (arrows), necrosis of hepatocytes and markedly focal fibrosis, leading to disintegration of hepatic cords. (D): Liver of a rabbit treated with AGE plus cholesterol showing less injury of central vein and less fat vacuole (arrows) comparing to high cholesterol rabbit.



**Fig. 1:** Photomicrograph of the heart section of (A): control rabbit heart showing normal striated muscles. Oval elongate nucleus centrally and homogeneous cytoplasm in normal myocardial cells. (B): heart sections of rabbit treated with AGE showing structure as seen in control. (C,D): heart sections of a rabbit fed with high -cholesterol diet demonstrating multi- focal vacuolar degeneration and necrosis of myocardial cells as well as separation of cardiac muscle bundles. (E): heart of a rabbit treated with AGE plus cholesterol showing better- preserved appearance of myocardial cell morphology with oval -elongate nucleus centrally and homogeneous cytoplasm. (H & E X 400).



**Fig.2:** Photomicrograph of the liver section of (A): control rabbit showing normal hepatocytes architecture. hepatocyte had the round nucleus centrally, the flat endothelial cells are around the central vein (CV). (B): liver of rabbit treated with AGE showing normal hepatocytes architecture. (C): liver section of rabbit fed with high-cholesterol diet demonstrating diffuse vacuolar degeneration fat vacuoles, necrosis of hepatocytes and markedly focal fibrosis, leading to disintegration of hepatic cords. (D): liver of a rabbit treated with AGE plus cholesterol showing less injury of central vein and less fat vacuole comparing to high cholesterol rabbit. (H&E X 400).

#### 4. Discussion:

It has been widely known that elevation of serum cholesterol can lead to atherosclerosis; blood supply to the organs gradually diminishes until organ function becomes impaired. Several lines of evidence show that the improvement and incidence of atherosclerosis and coronary heart disease are associated with a lowering of serum cholesterol level [1,6]. The consumption of excessive calories and diet containing fatty acids and cholesterol leads to hypercholesterolemia for human or animals [6]. Hypercholesterolemia induces oxidative stress, which is known to have adverse effects on the integrity of cells [31,32].

Our results show that, significant increase in serum TC, TG, LDL-C and HDL-C levels which used as indicators of hypercholesterolemia resulted from feeding rabbits cholesterol supplemented diet. These findings were in the same line as with those results reported by [33-35]. The significant increase in LDL levels in the hypercholesterolemic rabbits represents the effect of hypercholesterolemia on the oxidative modification of LDL, probably via increased susceptibility to oxidation [36]. Oxidation of LDL is a lipid peroxidation process resulting in formation of a wide range of biologically active products, including peroxides and malondialdehyde. The oxidatively

modified lipids and their degradation products are believed to have proinflammatory, immunogenic, and cytotoxic properties which contribute to both the initiation and progression of atherosclerotic lesions [37].

In animals treated orally with AGE there was significant decrease in serum TC, TG and LDL-C levels while, there was an elevation in the concentration of HDL-C as compared to hypercholesterolemic group indicating that AGE have hypolipidemic activity [38,39] and also, it could be effective to alleviate atherosclerosis which then eventually prevents the occurrence of cardiovascular diseases [8].

Our findings were in line with [40] who found that treatment rabbits with garlic extract (1.5 ml/kg/ day) orally for 4 months caused significant decrease in the serum total- cholesterol and triglyceride. Also, [38] revealed that (1% garlic powder supplement) for 12 weeks resulted in lowering the concentration of TC, TG ,LDL-C and elevation of the concentration of HDL-C, which has a protective function in the prevention of oxidation reactions and consumption of antioxidant potency. [41] found that allicin (diallyl disulfide) which an active constituent of garlic can lower the serum lipid profile in hyperlipidemic rabbits.

Also, it was found that aqueous garlic extracts showed higher antioxidant activity than those extracted with different polarity solvents. Aqueous extracts were used as a supplementation to diet-treated animals. This verifies other studies showing that the water- soluble S-allylcysteine reduces the extent of lipid peroxidation and significantly enhances antioxidant activities in vitro and in vivo [42,43]. [44] reported that, garlic consumption decreased serum total cholesterol and TG but increased HDL cholesterol in hyperlipidemic individuals and animals. Also, some studies [33,45,46] suggest that the use of garlic can prevent the formation of atherosclerotic lesions in animals fed a high -fat diet. The active ingredients of garlic, allicin, and other sulfur compounds may act as 3-hydroxy-3-methylglutaryl coenzyme A reductase inhibitors reducing the production of cholesterol in the liver [40] and reduce platelet aggregation and clotting [47].

Antioxidants and hypolipidemic agents suppress the development of hypercholesterolemic atherosclerosis and induce regression of atherosclerosis [48]. Suppresses the development of atherosclerosis is associated with decreases in oxidative stress and serum lipids [49]. Also, the increase in HDL-C levels represents a protective factor and are associated to decreased risk for atherosclerosis [35].

It is widely known that the heart and liver are primary organs at risk from hypercholesterolemia. The present results showed that cholesterol fed rabbits produced heart injury as indicated by marked elevation of serum CK, LHD activities as well as markedly pathological changes of myocardiocytes including

multi-focal vacuolar degeneration and early necrosis of myocardial cells as well as separation of cardiac muscle bundles. These changes were associated with a decrease in the antioxidant defense as manifested by the significant increase in lipid peroxidation of cardiac tissue and a significant decrease in the activities of antioxidant enzymes activity of SOD, CAT, GPx compared with control. This increase in serum CK and LDH might indicate the leakage of these enzymes through the membranes which are widely used as parameters for the diagnosis of cardiac dysfunction and the increase of CK level in serum and myocytes culture media as a result of possible cell damage is occurring in concert with the decrease of CK activity in cardiac tissue [50]. Our results also revealed that cholesterol-fed rabbits produced liver injury as indicated by marked elevation in serum hepatic enzyme levels AST, ALT and ALP associated with markedly histological changes consisted of diffuse vacuolar degeneration; fat vacuoles and necrosis of hepatocytes and markedly focal fibrosis as well as a marked decrease in the antioxidant defense system as manifested by the significant increase in lipid peroxidation and a significant decrease in the activity of antioxidant enzyme activity of SOD, CAT, GPx. These results are in agreement with [40,51] who reported that cholesterol-fed rabbits increased serum hepatic enzyme levels AST, ALT and ALP due to increased production of free radicals, which initiate lipid peroxidation leading to cellular damage as a result of induction of cytochrom P-450 in the liver producing highly reactive trichloromethyl free radical which in turn, in the presence of oxygen generated by metabolic leakage from mitochondria causing lipid peroxidation of membrane lipid leading to loss of integrity of cell membranes and damage of hepatic tissue

Animals treated with AGE along with cholesterol showed significant decrease in serum CK and LDH as well as significant decrease in serum hepatic enzymes as compared to cholesterol-enriched diet group indicating that AGE had a free radical scavenging activity which probably provides organs protection from hypercholesterolemia [44]. So, the current results suggest that garlic exerts hypocholesterolemic or antiatherogenic.

[38] observed that, garlic supplemented lowered the aortic and hepatic cholesterol and triglycerides of rabbits. Moreover, the study of [47] revealed that garlic has antioxidant activity and inhibits platelet aggregation and lowering of arterial blood pressure, which are the important events in myocardial infarction. Also, [40] reported that rabbits treatment with AGE may contribute to significant amelioration in hepatic steatosis and peroxidation process. Also, [52] demonstrated that aqueous GE with its potent free radical scavenging and antioxidant properties seems to

be a highly promising agent in protecting hepatic tissue against oxidative damage.

Rabbits fed cholesterol-enriched diet showed significant decrease in the activities of cardiac and hepatic SOD, CAT and GPx accompanied by significant increase in both cardiac and hepatic lipid oxidation (as measured by malondialdehyde (MDA) content) in heart and liver of rabbits. These results are in accordance with [53] who reported that oxidation of cholesterol fractions (in particular, LDL) has been accepted as playing an important role in the atherosclerotic process, and because lipid peroxidation is a radical process implicated in this formation. Also with [40] who observed that cholesterol-induced steatosis leads to a weakened antioxidant defence system and caused peroxidation in the hepatic tissue. In addition, oxidative stress disrupts the equilibrium between prooxidants and antioxidants in biological systems and leads to lipid peroxidation and free radical generation [32]. The level of malondialdehyde (MDA) is considered as a biomarker of lipid peroxidation [54]. [47] observed that, during myocardial infarction, superoxide radicals generated at the site of damage, modulates SOD and CAT, resulting in the loss of activity and accumulation of superoxide radical, which damages myocardium. Obtained results revealed that treatment of rabbits with AGE leads to significant increase in cardiac and hepatic CAT, SOD and GPx activities accompanied with significant decrease in cardiac and hepatic MDA level. The water soluble S-allylcysteine sulfoxide (alliin), a bioactive compound of garlic, reduces the extent of lipid peroxidation and significantly enhanced antioxidant activities in vitro and in vivo [42, 33, 55]. It is known that SOD catalyses superoxide anions to hydrogen peroxide, which is broken down by CAT and GPx, and then prevents further generation of free radicals. Garlic pretreatment increased the activity of SOD and CAT and it scavenges superoxide radicals and reduced myocardial damage caused by free radicals. [53, 33].

Also, garlic extracts increased superoxide dismutase (SOD) and catalase (CAT) activities in vascular cultured cells. S-allylcysteine sulfoxide (alliin), a bioactive compound of garlic, prevented the reduction of hepatic SOD and CAT activities in diabetic rats [33]. Also, it has been reported that garlic significantly lowered plasma and erythrocyte MDA levels while increasing antioxidant enzyme activity in elderly subjects [55].

The present study revealed that, AGE was not only able to lower the serum lipid profile but also suppress the high serum levels of CK, LDH, AST, ALT, and ALP. Moreover, lipid peroxidation was markedly suppressed, whereas the activities of antioxidant enzymes increased in both the cardiac and hepatic tissues of rabbits. In addition, AGE had a free radical scavenging activity which probably provides organs

protection from hypercholesterolemia which were supported by histological examination of myocardiocytes and hepatocytes. There for it could be concluded that AGE may be of therapeutic importance, not only as a lipid-lowering agent in serum but also as a cytoprotective agent to protect the heart and liver from hypercholesterolemia.

#### Acknowledgments:

The authors are grateful to the members of histology unit at Research Institute of Ophthalmology, Giza, Egypt for their help to perform the histological part of the paper.

#### References:

1. Freedman, J.E. (2003). High-fat diets and cardiovascular disease. *Journal of the American College of Cardiology*, 41(10): 1750-1752.
2. Badimon, L. ; Vilahur, G. and Padro, T. (2010). Nutraceuticals and atherosclerosis: human trials. *Cardiovascular Therapeutics*, 28 (4): 202-215.
3. Kwiterovich, P.O. and Jr, P.O. (1997). The effect of dietary fat, antioxidants, and pro-oxidants on blood lipids, lipoproteins, and atherosclerosis. *Journal of the American Dietetic Association* ., 97 (7): S31-S41.
4. Vijayakumar, R.S. ; Surya, D. and Nalini, N. (2004) . Antioxidant efficacy of black pepper (*Piper nigrum L.*) and piperine in rats with high fat diet induced oxidative stress. *Redox Report* ., 9 (2) : 105-110.
5. Du, H. ; Zhao, X. ; You, J.S. ; Park, J.Y. ; Kim, S.H. ; and Chang, K.J. (2010). Antioxidant and hepatic protective effects of lotus root hot water extract with taurine supplementation in rats fed a high fat diet. *Journal of Biomedical Science*, 17, supplement 1, p: S39.
6. Kabiri, N. ; Asgary, S. and Setork, M. (2011). Lipid lowering by hydroalcoholic extracts of *Amaranthus Caudatus L.* induces regression of rabbits atherosclerotic lesions. *Lipids in Health and Disease* ., 10:89.
7. Bhatnagar, D. (1998). Lipid-lowering drugs in the management of hyperlipidaemia. *Pharmacology and Therapeutics*, 79 (3):205-230.
8. Ou, C.C. ; Tsao, S.M. ; Lin, M.C. and Yin, M.C. (2003). Protective action on human LDL against oxidation and glycation by four organosulfur compounds derived from garlic. *Lipids* ., 38 (3): 219-224.
9. Vimal, V. ; Devaki, T. (2004). Hepatoprotective effect of allicin on tissue defence system in galactose amine/endotoxine challenged rats. *Journal of Ethnopharmacology* ., 90 (1) : 151-154.
10. Abdalla, F. H.; Bellé, L. P.; De Bona. K. S. ; Bitencourt, P.E. ; Pigatto, A. S. and Moretto, M. B. (2009). *Allium sativum L.* extract prevents methyl mercury-induced cytotoxicity in peripheral blood leukocytes (LS). *Food Chem. Toxicol.* ., 48: 417-421.
11. Sharma, V. ; Sharma, A. and Kansal, L. (2010). The effect of oral administration of *Allium sativum* extracts on lead nitrate induced toxicity in male mice. *Food Chem. Toxicol.*, 48: 928-936.
12. Asdaq, S.M.B. and Inamdar, M.N. (2010). Pharmacodynamic and Pharmacokinetic Interactions of Propranolol with Garlic (*Allium Sativum*) in rats. Evidence –



Based Complementary and Alternative Medicine ., 2011 : 1-11.

13. **Rahman, K. and Lowe, G.M. (2006).** Garlic and cardiovascular disease: a critical review. Journal of Nutrition; 136(3) ., 736S-740S.

14. **Rietz, B. ; Isens, H. ; Strobach, H. ; Makdessi, S. and Jacob, R. (1993).** Cardioprotective actions of wild garlic (*Allium ursinum*) in ischemia and reperfusion. Molecular and Cellular Biochemistry., 119 (1-2) :143-

15. **Banerjee, S.K. ; Maulik, M. ; Mancahanda, S.C. ; Dina, A.K. ; Gupta, S.K. and Maulik, S.K. (2002).** Dose – dependent induction of endogenous antioxidants in rat heart by chronic administration of garlic. Life Sciences., 70(13): 1509-1518.

16. **Sener, G. ; Satiroglu, H. ; Sehirli, A.O. and Kacmaz, A. (2003).** Protective effect of aqueous garlic extract against oxidative organ damage in a rat model of thermal injury . Life Sci., 73 : 81-91.

17. **Allain, C.C. ; Poon, L.S. ; Chen, S.G.; Richmond, W. and Fu, P.C. (1974).** Enzymatic determination of total serum cholesterol. Clin Chem ., 20(4): 470-5.

18. **Burstein, M. ; Scholnick, H.R. and Morfin, R. (1970).** Rapid method for the isolation of lipoproteins from human serum by precipitation with polyanions. J Lipid Res ., 11(6): 583-95.

19. **Friedewald, W.T. ; Levy, R.I. and Fredrickson, D. s. (1972).** Estimation of the concentration of low-density lipoprotein cholesterol in plasma, without use of the preparative ultracentrifuge. Clin. Chem ., 18: 499-502.

20. **Fossati, P. and Prencipe, L. (1982).** Serum triglycerides determined colorimetrically with an enzyme that produces hydrogen peroxide. Cli Chem ., 28 :2077-88.

21. **Reitman, A. and Frankel, S.A. (1957).** Colorimetric method for determination of serum glutaminoxaloacetic and glutamic pyruvic transaminases . Am. J. Clin. Path ., 28:56-63.

22. **King, J. (1965).** The dehydrogenases or oxidoreductases – lactate dehydrogenase, In: Van , D (ED.) , Practical Clinical Enzymology., Van Nostrand, London ; PP: 93 -193.

23. **Tietz, N.W. (1986).** Textbook of Clinical Chemistry, W.B. Saunders Co., Philadelphia., p: 678-686.

24. **Buhl, S.N. and Jackson, K.Y. (1978).** Optimal conditions and comparison of lactate dehydrogenase catalysis of the lactate to pyruvate and pyruvate to lactate reactions in serum at 25, 30, and 37degrees C. Clin Chem ., 24: 828-831.

25. **Satoh, k. (1978).** Serum lipidperoxide in cerebrovascular disorders determined by a new colorimetric method. Clinica Chimica Acta ., 90 : 37.

26. **Aebi, H. (1984).** Catalase in vitro. Methods Enzymol ., 105: 121-126.

27. **Nishikimi, M. ; Roa, N.A. and Yogi, K. (1972)** The occurrence of superoxide anion in the reaction of reduced phenazine methosulfate and molecular oxygen. Bioph. Res. Common; 46; 849-854.

28. **Paglia, D.E. and Valentine, W.N. (1967).** Studies on the quantitative and qualitative characterization of erythrocyte glutathione peroxidase. J. Lab. Clin. Med ., 70: 158-169.

29. **Ross, M.H. ; Reith, E.J. and Romrell, L.J. (1989).** Histology: A Text and Atlas (2nd ed). Baltimore. Williams & Wilkins., p: 51-84.

30. **Duncan, D.B. (1955).** Multiple Ranges and Multiple F – test. Biometrics., 11: 1-42.

31. **Prasad, K.. (2008).** Regression of hypercholesterolemic atherosclerosis in rabbits by secoisolaricresinol diglucoside isolated from flaxseed. Atherosclerosis ., 197:34-42.

32. **Stapleton, P.A. ; Good Will, A.G. ; James, M.E. ; Brock, R.W. and Frisbee, J.C. (2010)** . Hypercholesterolemia and microvascular dysfunction : interventional strategies . Journal of inflammation ., 7 : 54.

33. **Gorinstein, S. ; Leontowicz, H. ; Leontowicz, M. ; Drzewiecki, J. ; Najman, K. ; Katrich, E. ; Barasch, D. ; Yamamoto, K. and Trakhtenberg, S. ( 2006).** Raw and boiled garlic enhances plasma antioxidant activity and improves plasma lipid metabolism in cholesterol-fed rats. Life Sci ., 78: 655-663.

34. **Marinou, K.A. ; Georgopoulou, K. ; Agrogiannis, G. ; Karatzas, T. ; Dimitrios, I. D. ; Papalois, A. ; Chatziioannou, A. ; Magiatis, P. ; Halabalaki, M. ; Santila, N. ; Skaltsounis, L.A. ; Patsouris, E. and Dontas, L.A. (2010).** Differential effect of *Pistacia vera* extracts on experimental atherosclerosis in the rabbit animal model: an experimental study. Lipids in Health and Disease., 9:73.

35. **Frantz, E. ; Menezes, H.S. ; Lange, K.C. ; Abegg, M.P. ; Correa, C.A. ; Zangalli, L. ; Vieita, J.L. and Zetter, C.G. (2012).** The effect of maternal hypercholesterolemia on the placenta and fetal arteries in rabbits. Acta Cirurgica Brasileira., 27(1): 7-12.

36. **Witztum, J.L.; Steinberg, D. (2001).** The oxidative modification hypothesis of atherosclerosis: Does it hold for humans. Trends Cardiovasc Med., 11: 93-102.

37. **Sezer, E.D . ; Sozmen, E.Y. ; Nart, D. and Onat, T. ( 2011).** Effect of atorvastatin therapy on oxidant- antioxidant status and atherosclerotic plaque formation. Vascular Health and Risk Mangment ., 7: 333-343.

38. **Kwon, M.J. ; Song, Y.S. ; Choi, M.S. ; Park, S.J. ; Jeong, K.S. and Song, Y.O.. (2003).** Cholesteryl ester transfer protein activity and atherogenic parameters in rabbits supplemented with cholesterol and garlic powder. Life Sciences ., 72: 2953-2964.

39. **Kojic, Z. ; Gopcevic, K. ; Marinkovic, D. and Tasic, G. (2011)** . Effect of captopril on serum lipid levels and cardiac mitochondrial oxygen consumption in experimentally- induced hypercholesterolemia in rabbits. Physiol. Res ., 60 (Suppl. 1): S177-S184.

40. **Arhan, M. ; Öztürk, H.S. ; Turhan, N. ; Aytac, B. ; Güven, M.C. ; Olcay, E. and Durak, I. ( 2009)** . Hepatic oxidant/antioxidant status in cholesterol- fed rabbits: effects of garlic extract. Hepatology Research., 39: 70-77.

41. **Eilat, S. ; Oestraicher, Y. ; Rabinkov, A. ; Ohad, D. ; Mirelman, D. ; Battler, A. ; Eldar, M. and Vered, Z. (1995).** Alteration of lipid profile in hyperlipidemic rabbits by allicin, an active constituent of garlic. Coron. Artery Dis ., 6 : 985-990.

42. **Velmurugan, B. ; Bhuvanewari, V. and Nagini, S. (2003)** . Effect of S- allylcysteine on oxidant- antioxidant status during N<sup>1</sup> –nitro-N –nitrosoguanidine and saturated sodium chloride- induced gastric carcinogenesis in Wistar rats. Asia Pacific journal of Clinical Nutrition., 12 (4): 488-494.

43. **Almaca, G. (2004).** Antioxidant effects of sulfur-containing amino acids. Yonsei Medical Journal ., 45 (5) : 776-788.

- 44. Heidarian, E. ; Dehkordi, E.J. and Nahal, A.N. (2011).** Effect of garlic on liver phosphatidate phosphohydrolase and plasma lipid levels in hyperlipidemic rats. *Food and Chemical Toxicology* ., 49:1110 –1114.
- 45. Mahmoodi, M. ; Islami, M.R. ; Asadi, K. ; Khaksari, M ; Sahebghadam, L. ; Hajizadeh, M. and Mirzaee, M. (2006) .** Study of the effects of raw garlic consumption on the level of lipids and other blood biochemical factors in hyperlipidemic individuals. *Pak. J. Pharm. Sci.* ., 19: 295–298.
- 46. Thomson, M. ; Al-Qattan, K.K. ; Bordia, T. and Ali, M. (2006) .** Including garlic in the diet may help lower blood glucose, cholesterol, and triglycerides. *J. Nutr.* ., 136: 800S–802S.
- 47. Saravanan, G. and Prakash, J. (2004) .** Effect of garlic (*Allium sativum*) on lipid peroxidation in experimental myocardial infarction in rats. *J. Ethnopharmacol.*, 94: 155-158.
- 48. Prasad, K. (2007).** A study on regression of hypercholesterolemic atherosclerosis in rabbits by Flax Lignan complex. *J Cardiovasc Pharmacol Ther.* ., 12:304.
- 49. Sengupta, A. and Ghosh M. (2010) .** Modulation of platelet aggregation, haematological and histological parameters by structured lipids on hypercholesterolemic rats. *Lipids* ., 45: 393-400.
- 50. Miura, T. ; Muraoka, S. and Fujimoto, Y. (2000).** Inactivation of creatin kinase by adriamycin during interaction with horseradish peroxidase. *Biochem. Pharmacol.* ., 60 :95–99.
- 51. Weltman, M.D. ; Farrell, G.C. ; Hall, P. ; Ingelman-Sundberg, M. and Liddle, C. (1998).** Hepatic cytochrome P450 2E1 is increased in patients with nonalcoholic steatohepatitis. *Hepatology.*, 27: 128-330
- 52. Gedik, N. ; Kabasakal, L. ; Sehirlio, Ö. ; Ercan, F. ; Sirvanci, S. Uysal, M.K. and Sener, G. (2005).** Long – term administration of aqueous garlic extract (AGE) alleviates liver fibrosis and oxidative damage induced by biliary obstruction in rats. *Life Sciences* ., 76: 2593-2606.
- 53. Durak, I. ; Kavutcu, M. ; Aytaç, B. ; Avci, A. ; Devrim, E. ; Özbek, H. and Öztürk, H.S. (2004) .** Effects of garlic extract consumption on blood lipid and oxidant/antioxidant parameters in humans with high blood cholesterol. *J. Nutr. Biochem.*, 15: 373–377.
- 54. Lykkesfeldt, J. (2007).** Malondialdehyde as biomarker of oxidative damage to lipids caused by smoking. *Clin. Chim. Acta.*, 380: 50–58.
- 55. Avci, A. ; Atli, T. ; Erguder, I. B. ; Varli, M. ; Devrim, E. ; Aras, S. and Durak, I. (2008).** Effects of garlic consumption on plasma and erythrocyte antioxidant parameters in elderly subjects. *Gerontology.*, 54: 173–176.

5/2/2012