

## Studies on Hematological Parameters and DNA Structure in Newborn Rats Exposed to Extremely Low Frequency Magnetic Fields

Nihal S. El-Bialy, Reem H. El-Gebaly\* and Monira M. Rageh

Department of Biophysics, Faculty of Science, Cairo University, Egypt. [r\\_elgebaly@msn.com](mailto:r_elgebaly@msn.com)

**Abstract:** The aim of this study was to evaluate the possible effects of *in vivo* exposure to extremely low frequency magnetic fields (ELF-MF) on some hematological parameters, pathological variations and DNA structure in newborn rats. Six female pregnant Wistar rats were obtained from the National Research centre in Egypt and gave birth to 30 rats at the animal house of Cairo University. The newborn rats were divided into two separate groups: one exposed group (50 Hz, 0.5 mT, 30 days, 24 h/day) and one control (sham). Red blood cells (RBCs), hemoglobin and hematocrit levels decreased significantly ( $P < 0.02$ ) while white blood cells (WBCs) and platelets levels significantly increased ( $P < 0.04$ ) in newborn rats that were exposed to ELF-MF. There was no significant difference in mean corpuscular hemoglobin (MCH), mean corpuscular hemoglobin concentration (MCHC), mean corpuscular volume (MCV) levels and DNA structure between the exposed and sham-exposed groups. ELF-MF induced a marked necro-degenerative change in kidney tissue and peri-portal fibrosis in liver tissues. Our results indicate that the applied ELF-MF exposure may induce statistically significant alterations in some hematological parameters, kidney and liver tissues of newborn rats.

[Nihal S. El-Bialy, Reem H. El-Gebaly and Monira M. Rageh. **Studies on Hematological Parameters and DNA Structure in Newborn Rats Exposed to Extremely Low Frequency Magnetic Fields.** Life Science Journal 2012; 9(1):489-495]. (ISSN: 1097-8135). <http://www.lifesciencesite.com>. 74

**Key Words:** Electromagnetic field, hematological parameters, DNA, pathological tissues.

### 1. Introduction

Results of experimental *in vitro* and *in vivo* studies carried out in recent years have given more attention to the biological effects of electromagnetic fields. Previous data suggest the association between electromagnetic field exposure and the increased incidence of certain types of tumor, particularly childhood and adult leukemia, childhood and adult brain tumors and increased risk of the neurodegenerative diseases [1, 2].

It is now known that ELF-MF can change cell behaviors and activations by affecting the biochemical and /or biophysical processes. Chemical and physical processes at the atomic levels are the bases of reactions between biomolecules in an electromagnetic field (EMF), since the field can magnetically affect chemical bonds between adjacent atoms with consequent production of free radicals [3-5].

The blood is one of the major homeostatic systems of the body in humans and animals, supporting normal viability, integrity and adaptive responses. The functional state of the blood systems changes dynamically according to the nature strength and duration of exposure to external factors. **Rogers et al.**, [6] reported that exposure to EMF changes the level of melatonin in blood.

Several studies have been reported concerning the effect of ELF-MF on cellular DNA damage. **Lai and Singh** [7] reported that acute (2hrs) exposure of rats to a 60 Hz magnetic field (flux densities 0.1, 0.25 and 0.5 mT ) caused a dose- dependent increase in

DNA strand breaks in brain cells. On the other hand, there are several reports which demonstrate that ELF-MF does not cause DNA damage, especially DNA strand breaks [8-10]. The results of **Ivancsits et al.**, [11-13] indicate that the interaction of MF with DNA is quite complicated and apparently depends on many factors.

### 2. Materials and Methods

#### Animals

Animals were housed and maintained according to guidelines for the Care and Use of Laboratory Animals' [14] and approved by the animal Ethics Committee at Cairo University. Briefly, timed pregnant Wistar rats were purchased from the National Center of Researches in Egypt and gave birth at the animal house of Cairo University. They were maintained for one week in the laboratory for adaptation. Adult female rats with their newborns were housed in plastic cages with free access to drinking water and standard chow diet. They were also maintained in a controlled environment with 12h light cycle. All animal groups were housed in clean first hand cages under standard condition in a separate laboratory which belongs to animal care unit.

#### Magnetic Field Exposure

The exposure was performed by a magnet with a fixed magnetic field value of  $0.5 \text{ mT} \pm 0.025$ . The magnetic field (MF) was generated by a solenoid carrying current of 18 A (ampere) at 50 Hz from the

main supply (220-230 Volt) via a variac (made in Yugoslavia). The magnet consisted of a coil with 320 turns made of electrically insulated 0.8 mm copper wire. The coil was wound around a copper cylinder of 2mm thickness, 40cm diameter and 40cm length. The cylinder wall was earthed to eliminate the electric field. The magnetic field was measured at different locations to find out the most homogenous zone inside the solenoid core. This was done using Gauss/ Tesla meter model 4048 with probe T-4048 manufactured by Bell Technologies Inc. (Orlando-Florida USA). Plastic cages containing six adult female rats (Wistar) and their newborns were placed in the middle of the exposure chamber prior to MF exposure. When the newborns reached 10- days of age, they were randomly divided into two groups of 15 each: one control (sham) and one exposed. The latter group has been exposed to 50 Hz, 0.5 mT $\pm$  0.025 MF for 30 days 24 hrs per day. The control (sham) group was treated like the exposed group with the sole difference that it was not exposed to magnetic field. The two groups were treated equally considering light and food. The temperature and humidity were monitored continuously throughout the experimental period. This ensures that the control and the exposed animals were maintained in the same condition. During the experimental period, cleaning and changing water and food were done to all animals two times daily. The field was switched off during cleaning the cage. After 30 days of exposure, the two groups of newborn rats were sacrificed by decapitation. Five newborn rats from each group were used for DNA analysis. Another 5 newborn rats were used for hematological parameters and lastly 5 newborn rats were maintained for histopathological examination.

#### Analysis of DNA Fragmentation

Analysis of DNA fragmentation was measured using agarose gel electrophoresis, according to the protocol developed by **Kasibhatla et al.** [15]. 0.5 gm homogenized liver and spleen were transferred to 1.5 ml sterile micro centrifuge tubes. Centrifugation occurred at 200xg in an Eppendorf tube, centrifugation for 5min at 4°C and then the supernatant was removed. 20  $\mu$ l of TES (20mM EDTA (ethylenediaminetetraacetic acid), 100 mM Tris(hydroxymethylaminomethane), pH8.0, 0.8% (w/v) Sodium dodecyl sulfate) lysis buffer were added and mixed with cell pellet. 10  $\mu$ l of RNase Cocktail were added, mixed well and incubated for 30-120min at 37 °C. 10  $\mu$ l of proteinase K, were added and incubated at 50 °C for at least 90min. 5 $\mu$ l of 6x DNA loading buffer were added and DNA samples were loaded into dry wells of a 1-1.5% agarose gel in TAE (242g Tris base, 57.1 ml Acetic acid, 100 ml of 0.5 M EDTA, pH 8.0) buffer containing 0.5  $\mu$ g/ml

ethidium bromide. The gel was run at low voltage (i.e., 35V for 4 hours or until loading dye has run two-thirds of the way down the gel). DNA ladders are finally visualized by a ultra-violet (UV) light source and documented by photography. The gels were analyzed using the software: Gel-Pro Analyzer 3.1. The used chemicals were purchased from Sigma chemical co. (St. Louis MO, USA).

#### Histopathological Examination

The liver and kidney of newborn rats from control and exposed groups were dissected, removed and fixed in 10% neutral formalin. Then, they were embedded in paraffin blocks, sectioned and stained with hematoxylin and eosine (H&E).

Liver and kidney tissue sections were examined using light microscope (CX31 Olympus microscope) connected with digital camera (Canon) at a power x400.

#### Hematological Parameters

The blood is drawn from the control and exposed groups in test tubes containing anticoagulant (EDTA). White blood cells (WBC), red blood cells (RBC) indexes (hemoglobin, hematocrit, mean corpuscular volume (MCV), mean corpuscular hemoglobin (MCH), mean corpuscular hemoglobin concentration (MCHC)) and platelets were counted and determined as methods described by (Dacie and Lewis)[16].

#### Statistical Analysis

All data are expressed as mean  $\pm$  standard error. The significance of difference in the results was evaluated with one-way ANOVA test.

### 3. Results

The results from DNA fragmentation using agarose gel electrophoresis technique are shown in figures (1, 2). Figure (1) shows that, lane (1) represents marker of standard molecular weight, lane(2) represents DNA isolated from the spleen of the control group, lanes (3,4,5) represent DNA isolated from the spleen of the exposed group, lane (6) represents DNA isolated from the liver of the control group, lanes (7,8,9) represent DNA isolated from the liver of the exposed group. Figure (2) shows the densitometry scan of figure (1). The results show that the DNA from viable cells stayed on the top of the gel as a high molecular weight band. The DNA from apoptotic cells formed as a distinct DNA ladder. The results do not show any difference between the DNA isolated from the spleen and liver of the control and exposed groups.




Figure (1): Gel electrophoresis of DNA. Lane(1) marker of standard molecular weight, lane(2) DNA isolated from spleen of control group, lanes(3) DNA isolated from spleen of exposed group, lane(4) DNA isolated from liver of control group, lanes(5) DNA isolated from liver of exposed.

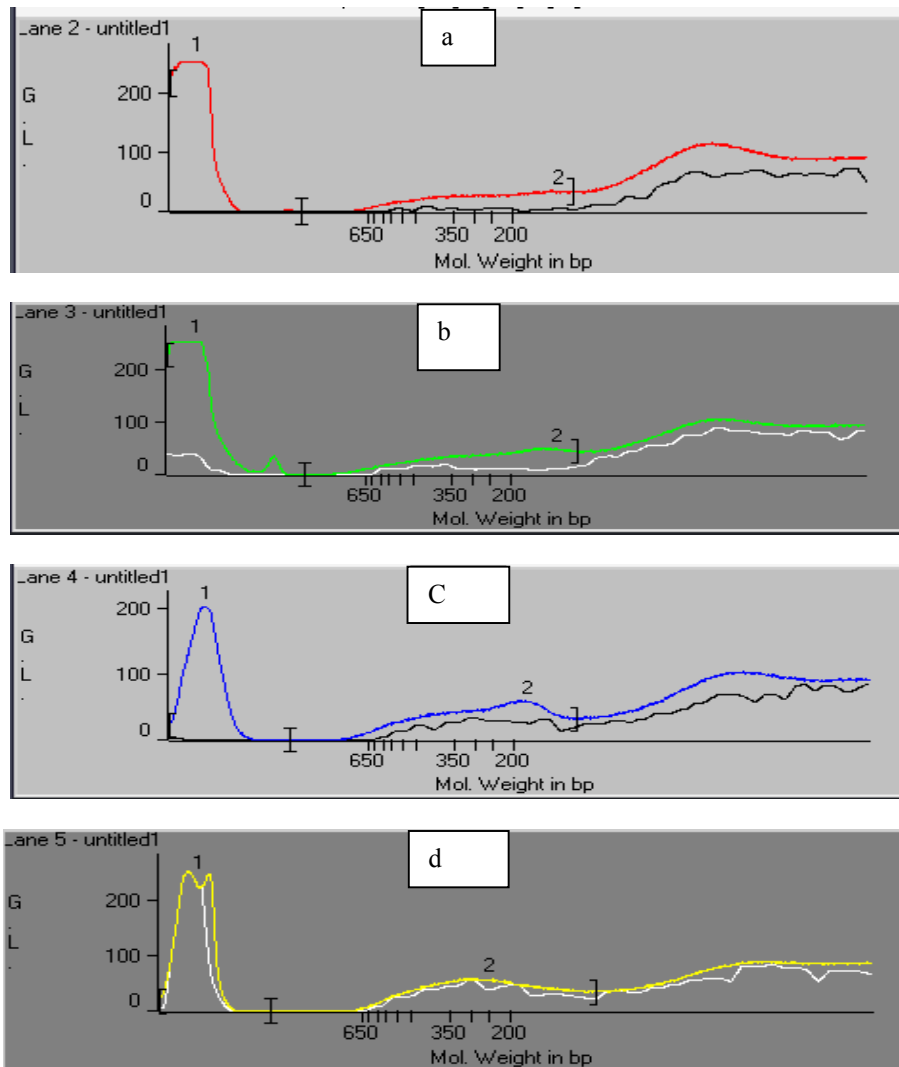


Figure (2 a-d): Densitometry scan of fragmented DNA samples.(a ) DNA isolated from spleen of control group, (b) DNA isolated from spleen of exposed group, (c) DNA isolated from liver of control group, (d) DNA isolated from liver of exposed.

Figure (3a,b) represents liver sections from control and exposed groups respectively. Liver section of control group showed the portal tract intact triad of bile duct, hepatic artery and portal vein. On the one hand, no necro-inflammatory or degenerative changes, fibrosis, cirrhosis, or abnormal deposits

occurred. On the other hand liver section of the exposed group showed that portal tract is enlarged with peri-portal fibrosis. The hepatic artery showed mild congestion, the hepatocytes diffuse macro and micro vesicular steatosis and no established cirrhosis.

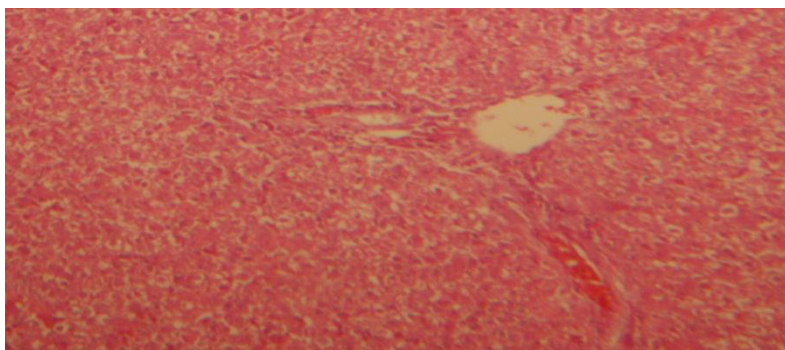


Figure (3a) : Liver, the control group: The portal tract shows intact triad of bile duct, hepatic artery & portal vein. No necro-inflammatory or degenerative changes, fibrosis, cirrhosis, or abnormal deposits. H&E, x200.

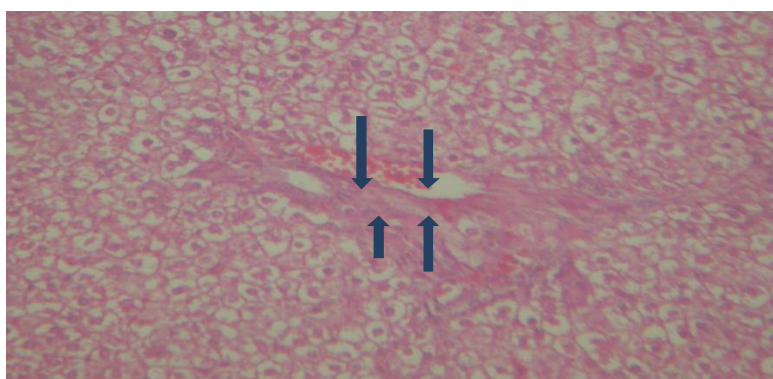
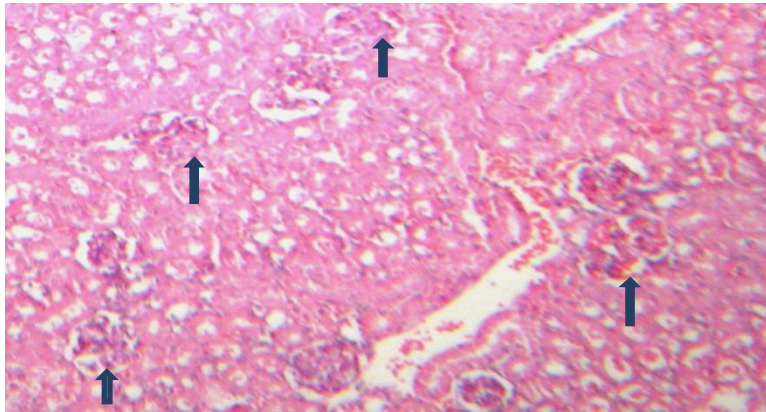


Figure (3b): Liver, the exposed group: The portal tract is enlarged with peri-portal fibrosis & early fibrous bridges (arrows) attempts (ie. Incomplete bridge formation) The hepatic artery shows mild congestion. The hepatocytes show diffuse macro & microvesicular steatosis. No established cirrhosis. H&E, x200.

Figure (4a,b) represents kidney sections from control and exposed groups respectively. Kidney section of control group showed renal tubules that are intact with patent lumens, free of cellular or hyaline casts. The cell lining is viable, free of necro-degenerative changes. The interstitium is free of inflammatory exudates, granulomas, fibrosis, abnormal deposits or vascular injury. Also renal glomeruli are intact with normo-cellularity, free of necro-degenerative changes, inflammatory exudates, atrophy, sclerosis, abnormal deposits, mesangioproliferative activity, or vascular injury. Meanwhile kidney section of exposed group showed renal tubules with necro-degenerative change, swollen edematous cell lining. There is focal partial luminal

obliteration by hyaline casts. Also renal glomerulus showed fibrous atrophy, necrosis and hyaline degeneration.

Table (1) shows the level of hematological parameters in control and exposed groups. Results of the analysis were given as mean  $\pm$  standard deviation. The level of hemoglobin, RBCs and hematocrit in exposed group decreased compared to the control group ( $p < 0.02$ ). The level of WBCs and platelets in exposed group increased compared to the control group ( $p < 0.04$ ). No significant difference in MCV, MCH and MCHC were found between exposed and control groups.



Figure( 4a) : Kidney, the control group: Renal tubules are intact with patent lumens, free of cellular or hyaline casts. The cell lining is viable, free of necro-degenerative changes. The interstitium is free of inflammatory exudates, granulomas, fibrosis, abnormal deposits or vascular injury. Renal glomeruli are intact (arrows) with normo-cellularity, free of necro-degenerative changes, inflammatory exudates, atrophy, sclerosis, abnormal deposits, mesangioproliferative activity, or vascular injury. H&E, x100.

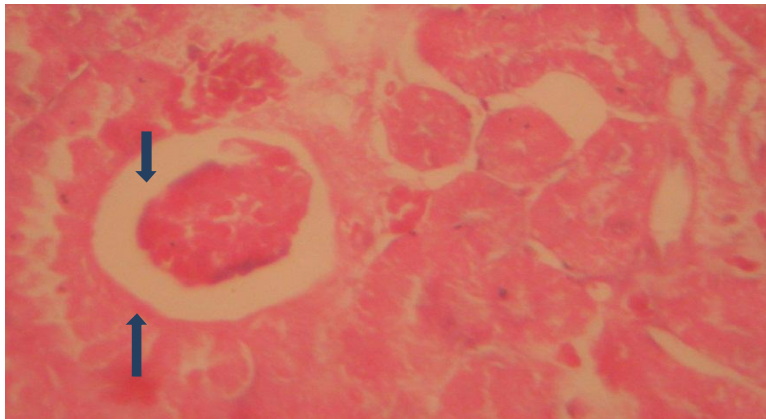


Figure (4b): Kidney, the exposed group: Renal tubules at the Rt. Of the field show necro-degenerative change, swollen edematous cell lining. There is focal partial luminal obliteration by hyaline casts (thin arrows). The glomerulus (bold arrows) show fibrous atrophy, necrosis & hyaline degeneration. H&E x250.

Table (1): Hematological parameters of newborn rates after whole body exposure to (50 Hz, 0.5 mT MF) for 30 days/24 h ( Mean± S.D.)

Parameters	Control	Exposed	<i>P</i> -value
WBCx10 <sup>3</sup> cells/μl	5.2±0.17	5.97±0.18	0.04
RBCx10 <sup>6</sup> cells/μl	5±0.23	4.07±0.03	0.02
Hemoglobin g/dl	14.47±0.66	11.73±0.12	0.02
Hematocrit	44.81±2.15	36.3±0.36	0.02
MCV	89.6±0.2	89.2667±0.26	0.374
MCH pg	28.9±0.0577	28.8667±0.066	0.725
MCHC g/dl	32.3±0.05774	32.3±0	1.0
Platelets x10 <sup>3</sup> μl	196.7	231.7	0.04

#### 4. Discussion

The present study is concerned with the effects of ELF-MF on the structure of DNA (isolated from liver and spleen tissues), pathological changes in liver and kidney tissues and some hematological parameters. The data indicated that 50 Hz, ELF-MF at a flux density of 0.5 mT exposure does not produce enough energy to induce DNA damage figures (1,2), this result is in consistent with the studies of **Milena et al.** [17] and **McNamee et al.** [18] who reported that there was no significant effect on DNA strand breaks upon ELF-MF exposure. In consistence this dose causes pathological changes which might be due to ELF-MF induced oxygen free radicals which can evoke an interaction with membrane lipids, proteins and nucleic acids leading to extensive tissue damage that was confirmed by histopathological examination ( Fig. 3,4). Accordingly the liver is a hematopoietic organ and any anatomic changes within this organ, cause alterations in hematological parameters.

The present data demonstrated that ELF-MF significantly decreased the level of RBCs, hemoglobin and hematocrit. This was in agreement with **Cakir et al.** [19]. Additionally the field significantly increased the value of WBCs and platelets and also no significant changes in MCV, MCH and MCHC were observed (Table 1). **Lino et al.**, and **Chater et al.**, [20,21] stated that hemoglobin is sensitive to EMF, **Higashi et al.**, [22] reported that RBCs orient with the applied MF and **Atef et al.** [23] hypothesized the change in conformation of Hb under MF action. **Cabrales et al.** [24] observed that hematocrit and hemoglobin levels decreased significantly compared to the control group after ELF-EMF exposure. **Regan et al.** [25] explained the reason for the observed hematological variability in response to ELF-EMF exposure as spleen hyper function. **Oroza et al.** [26] observed that for exposed rats to magnetic fields for 1,2 and 4 weeks, only the 4 week exposure induced an increase in WBCs count. By contrast **Fiorani et al.** and **Selmsoui et al.** [27,28] indicated that MF had no significant effect on RBCs, WBCs and Hb. **Osbakken et al.** [29] observed that spleen hyper function increases the rate of distraction of red blood cells, white blood cells and platelets. The reasons for these conflicting results probably stem from differences in exposure setups and experimental conditions.

#### Conclusion:

In conclusion the present work show that ELF-MF might possess a capability under specific conditions to influence some hematological and pathological parameters in newborn rats at significant values.

#### Corresponding author

Reem H. El-Gebaly  
Department of Biophysics, Faculty of Science, Cairo University, Egypt  
[r\\_elgebaly@msn.com](mailto:r_elgebaly@msn.com)

#### References

- 1-Wertheimer N, Savitz DA, Leeper E., 1995. Childhood cancer in relation to indicators of magnetic fields from ground current sources. *Bioelectromagnetics*, 16;86-96.
- 2-Aldrich TE, Andrews KW, Liboff AR., 2001. Brain cancer risk and electromagnetic fields (EMFs): assessing the geomagnetic component. *Arch Environ Health*; 56(4):314-9.
- 3- Till U., Timmel C.R., Brocklerhurst B., and Hore P. J., 1998. The influence of very small magnetic fields on radical recombination reactions in the limit of slow recombination. *Chem. Phys. Lett.*, 208: 7-14.
- 4-Simko M. and Mattsson M. O., 2004. Extremely Low Frequency Electromagnetic fields as effectors of cellular responses *in vitro*: Possible Immune Cell Activation. *J. Cell Biochem.*, 93: 83-92.
- 5-Rollwitz J. Lupke M. and Simko M., 2004. Fifty-hertz magnetic fields induce free radical formation in mouse bone marrow-derived promonocytes and macrophages. *Biochim. Biophys. Acta.*, 1674: 231-238.
- 6-Rogers WR, Reiter RJ, Smith HD, Barlow-Walden L, 1995. Rapid onset/offset, variably scheduled 60 Hz electric and magnetic field exposure reduces nocturnal serum melatonin concentration in nonhuman primates. *Bioelectromagnetics Supplement*, 3:119-122.
- 7- Lai H. and Singh P. N., 1997. Acute exposure to a 60 Hz magnetic field increase DNA strand breaks in rat brain cells. *Bioelectromagnetics*, 18: 156-165.
- 8- Reese J.A., Jostes R.F. and Frazier M.E., 1988. Exposure of mammalian cells to 60 Hz magnetic or electric fields: analysis for DNA single-strand breaks. *Bioelectromagnetics*, 9:237-247.
- 9-Frazier M.E., Reese J.A., Morris J.E. Jostes R.F and Miller D.L., 1990. Exposure of mammalian cells to 60 Hz magnetic or electric fields: analysis of DNA repair of induced single-strand breaks. *Bioelectromagnetics*, 11:229-234.
- 10- Fairbairn D.W. and O'Neill K.L., 1994. The effect of electromagnetic exposure on the formation of single-strand breaks in human cells. *Cell. Mol. Biol.*, 40:561-567.
- 11-Ivancsits S, Diem E, Pilger A, Rudiger HW, Jahn O., 2002. Induction of DNA strand breaks by intermittent exposure to extremely-low-frequency

- electromagnetic fields in human diploid fibroblasts. *Mutat Res.*, 519:1–13.
- 12-Ivancsits S, Diem E, Jahn O, Rudiger HW. 2003a. Intermittent extremely low frequency electromagnetic fields cause DNA damage in a dose-dependent way. *Int Arch Occup Environ Health*, 76:431–436.
- 13-Ivancsits S, Diem E, Jahn O, Rudiger HW., 2003b. Age-related effects on induction of DNA strand breaks by intermittent exposure to electromagnetic fields. *Mech Ageing Dev.*, 124:847–850.
- 14-National Research Council., 1996. Guide for the care and use of laboratory animals: National Academy Press, Washington DC
- 15-Kasibhatla S, Gustava P, Mendes A, Finucane D, Brunner T, Wetzal E, and Green DR, 2006. Analysis of DNA Fragmentation Using Agarose Gel Electrophoresis, Cite as: Cold spring Hrb. Protocol; doi:10.1101/pdb.prot4429.
- 16-Dacie SJ and Lewis SM, 1991. Practical Hematology. Churchill livingstone 7<sup>th</sup>ed, 179-200
- 17- Milena V, Massimo M, Giuseppina S, Bruno B and Rossana P., 2006. Effects of co-exposure to extremely low frequency (50 Hz ) magnetic fields and xenobiotics determined *in vitro* by the alkaline comet assay. *Science of the Total Environmental.*; 361:208-219.
- 18-McNamee JP, Bellier PV, McLean JRN., Marro L, Gajda GB and Thansandote A., 2002. DNA damage and apoptosis in the immature mouse cerebellum after acute exposure to a 1mT, 60 Hz magnetic field. *Mutation Research*, 513: 121-123.
- 19-Cakir D, Yokus B, Zulkuf M, Sert C and Mete N., 2009. Alterations of hematological variations in rats exposed to extremely low frequency magnetic fields (50 Hz). *Archives of Medical Research*, 40: 352-356.
- 20-Lino M., 1997. Effects of a homogeneous magnetic field on erythrocyte sedimentation and aggregation. *Bioelectromagnetics*; 18:215-222.
- 21-Sihem Chater S, Abdelmelek H, Pequignot JM, *et al.*, 2006. Effects of subacute exposure to static magnetic field on hematologic and biochemical parameters in pregnant rats. *Electromagn Biol Med.*; 25:135-144.
- 22-Higashi T, Yamagishi A, Takeuchi T, *et al.*, 1993. Orientation of erythrocytes in a strong static magnetic field. *Blood*; 82:1328-1334.
23. Atef MM, Abd el-Baset MS, El-Kareem A., 1995. Effects of a static magnetic field on hemoglobin structure and function. *Int J Biol Macromol.*; 2:105e111.
- 24-Cabrales LB, Ciria HC, Bruzon RP., 2001. ELF magnetic field effects on some hematological and biochemical parameters of peripheral blood in mice. *Electro-Magnetobiology*; 20:185-191.
- 25- Regan HA, Buscbom RL, Pipes MJ, *et al.*, 1983. Hematologic and serum chemistry studies in rats exposed to 60 Hz electric fields. *Bioelectromagnetics*; 4:79-90
- 26-Oroza MA, Calcicedo L, Sanchez-Franco F, *et al.*, 1987. Hormonal, hematological and serum chemistry effects of weak pulsed electromagnetic fields on rats. *J Bioelectricity*; 6:139-151.
- 27-Fiorani M, Biagiarelli B, Vetrano F, *et al.*, 1997. *In vitro* effects of 50 Hz magnetic fields on oxidatively damaged rabbit red blood cells. *Bioelectromagnetics*; 18:125-131.
- 28-Selmaoui B, Bogdan A, Auzeby A, *et al.*, 1996. Acute exposure to 50 Hz Magnetic field does not affect hematologic or immunologic functions in healthy young men. *Bioelectromagnetics*; 17:364-372.
- 29-Osbakken M, Griffith J, Taczanowsky P. A., 1986. Gross morphologic, histologic, hematologic, and blood chemistry study of adult and neonatal mice chronically exposed to high magnetic fields. *Magnet Reson Med.*; 3:502-517.

1/22/2012