

Role of Selenium in Attenuating Cardiac and Hepatic Damages Induced By the Antitumor Agent, Doxorubicin

Safinaz S. Ibrahim*, Maged A. Barakat and Hebatalla M. Helmy

Biochemistry Department, Faculty of Pharmacy, Cairo University, Cairo, Egypt
*safinazsibrahim@cu.edu.eg

Abstract: Background and Objectives: The clinical use of doxorubicin, one of the most effective antitumor agents, soon proved to be hampered by such serious problems as the development of cardiomyopathy and liver damage. The current study aims at evaluating the role of trace element, selenium, in attenuating cardiac and hepatic damages induced by the antitumor agent, doxorubicin. **Materials and Methods:** Animals were divided into normal control group and doxorubicin -treated group injecting doxorubicin i.p. as 6 equal doses of 2.5 mg/kg, twice weekly/ 3 weeks. The doxorubicin - treated animals were divided into 2 groups, one kept without further treatment (doxorubicin -group), second group, (doxorubicin + selenium) received selenium (Na Selenite) 0.5 mg/kg orally, 3 times/week/4 weeks including one week before the doxorubicin 1st dose. Serum creatine phosphokinase, lactate dehydrogenase, as cardiac damage markers, and alanine aminotransferase, as indicator of hepatic damage, were measured. Malondialdehyde and nitric oxide levels, as cardiac oxidative status indices, cardiac glutathione content, glutathione peroxidase, glutathione-S-transferase and superoxide dismutase activities, as measures for cardiac antioxidant capacity, were also investigated. Histopathological changes in cardiac and liver tissues were examined. The results were analyzed statistically by one-way analysis of variance with subsequent multiple comparisons using Tukey test. **Results:** doxorubicin induced significant increase in serum lactate dehydrogenase; creatine phosphokinase; alanine aminotransferase activities, cardiac nitric oxide, malondialdehyde levels, superoxide dismutase, glutathione peroxidase, glutathione-S-transferase activities, and reduction in glutathione content. Selenium co-administration caused significant decrease in serum lactate dehydrogenase and creatine phosphokinase levels; normalization of serum alanine aminotransferase; significant decrease in cardiac malondialdehyde, nitric oxide levels, glutathione peroxidase, glutathione-S-transferase, superoxide dismutase activities and significant elevation in cardiac glutathione content, compared to doxorubicin -treated group values. Histopathological examination of cardiac and liver tissues supported the previous biochemical results. **Conclusions:** Chronic doxorubicin administration caused cardiomyopathy and hepatic damage. Selenium co-administration produced partial, but significant, protection against cardiomyocyte damage; however, it alleviated hepatic damage-induced by the antitumor agent, doxorubicin.

[Safinaz S. Ibrahim, Maged A. Barakat and Hebatalla M. Helmy. Role of Selenium in Attenuating Cardiac and Hepatic Damages Induced By the Antitumor Agent, Doxorubicin. Life Science Journal 2011;8(1):1-12]. (ISSN: 1097-8135). <http://www.lifesciencesite.com>.

Key words: Doxorubicin, cardiomyopathy, liver damage, selenium

1. Introduction

Anthracyclines rank among the most effective anticancer drugs ever developed [1]. The first anthracycline was isolated early in the 1960s from the pigment producing *Streptomyces Peucetius*, a species of actinobacteria [2] and was named doxorubicin (Dox). Doxorubicin is an essential component of treatment of breast cancer [3], soft tissue sarcomas [4] and many other cancers [5]. Because Dox has been shown to produce free radicals, it was suggested earlier that free radical injury might be a mechanism of Dox antitumor activity [6]. There now appears to be general agreement that oxidative stress is unlikely to be a significant contributor to the antitumor activity of Dox [7]. Liver is the main site of Dox metabolism, reduction of side chain carbonyl group by NADPH-

Cyto P450 yields a more polar and toxic metabolite, doxorubicinol. Such metabolite accumulates in the heart and contributes significantly to chronic cumulative cardiotoxicity of Dox [8]. The enormous value of Dox in treating a variety of solid and hematologic malignant conditions is unquestioned. However, as with any other anticancer agent, the clinical use of Dox soon proved to be hampered by such serious problems as the development of resistance in tumor cells [9] or toxicity in healthy tissues, most notably in the form of chronic cardiomyopathy and congestive heart failure[1]. These adverse effects of the drug can preclude its use in some patients and limit the duration of its use in many others [10].

Selenium (Se) plays an important biological role in living organisms, mostly through its

incorporation in a family of proteins, selenoproteins. The main biological form of Se is selenocysteine, a cysteine analog that is synthesized from a serine bound to tRNA. The biological roles ascribed to Se include the prevention of cardiovascular disease [11] and cancer [12]. In the heart, Se supplementation caused increase in the cardiomyocyte glutathione peroxidase (GPx) activity, the total antioxidant activity, glutathione (GSH) concentration and catalase activity, leading to decreased generation of reactive oxygen species (ROS)[13]. The present study aims at evaluating the attenuating effect of Se, as an adjuvant therapy, on Dox- induced cardiac and hepatic damages.

2. Materials and methods.

A- Animals:

Total numbers of 32 male albino rats of the Wister strain, weighing 170-200 g, were used in the present study. The animals were obtained from the central animal facility at the Faculty of Pharmacy, Cairo University, Cairo, Egypt. All rats were housed in a room with a controlled environment, at a constant temperature of $23 \pm 1^{\circ}\text{C}$, humidity of $60\% \pm 10\%$, and a 12 hrs light/dark cycle. The animals were housed in groups and kept at constant nutritional conditions throughout the experimental period. The experimental protocols were approved by the Ethical Committee of Cairo University.

B- Drugs and chemicals:

Doxorubicin HCL was obtained from Pharmacia & Upjohn, Milan, Italy. Sodium selenite was obtained from Sigma Chemical Company, USA. Other chemicals in the experiments were of analytical pure grade and supplied by British Drug House (BDH, UK), Merck (Germany) and Sigma Chemical Company (USA).

C- Experimental design:

Animals were divided into a normal control group (10 rats), receiving the appropriate volume of saline i.p, and Dox-treated group. Doxorubicin was dissolved in saline and injected i.p., as a total cumulative dose equal to 15 mg/kg, divided into 6 equal doses, 2.5 mg/kg each. They were injected twice weekly/ 3 weeks [14]. Dox-treated animals were divided into two groups, one kept without further treatment (Dox-group), and a second group (Dox + Se) received Se, as sodium selenite, 0.5 mg/kg, orally, 3 times/week/4 weeks including one week before the 1st Dox dose[15].

D- Serum and tissue sampling:

24 hours following the last Dox injection, rats were sacrificed by decapitation. Blood sample of

each animal was collected into a dry centrifuge tube. Serum was separated by centrifugation at 3000 r.p.m. /15 minutes and used to determine creatine phosphokinase (CPK), lactate dehydrogenase (LDH) and alanine aminotransferase (ALT). Serum CPK activity was determined using a kit provided by STANBIO, USA. CPK catalyses the transphosphorylation of ADP to ATP through a series of coupled enzymatic reactions. NADH is provided at a rate directly proportional to CPK activity. The method determines NADH absorbance increase per minute at 340 nm [16]. Serum LDH activity was determined using a kit provided, also, by STANBIO, USA. LDH specifically catalyzes the oxidation of lactate into pyruvate with subsequent reduction of NAD to NADH. Rate of NADH formation is proportional to LDH activity. The method described determines NADH absorbance increase per minute at 340 nm [17]. Serum ALT activity was determined, using a kit provided by Quimica Clinica Aplicada, Spain[18].

Histopathological study:

The hearts and livers were removed by dissection, washed by ice-cold isotonic saline and blotted between two filter papers. Autopsy samples were taken from heart and liver in different groups of rats and fixed in 10% formol saline for 24 hrs. Washing was done, then, serial dilutions of alcohol were used for dehydration. Paraffin bees wax tissue blocks were prepared for sectioning the studied tissues. The obtained sections were stained by hematoxylin and eosin stains [19] for histopathological examinations through the light microscope.

Biochemical parameters:

10% w/v homogenate was prepared in ice-cold deionized water for the remainder of the heart tissues of the different groups.

Measurement of cardiac oxidative status indices:

A portion of the homogenate was mixed with ice-cold 2.3% KCL (in ratio of 1:1) and centrifuged at 3000 r.p.m./15 minutes. Thiobarbituric acid (TBA) – reactive substance, malodialdehyde (MDA), content was determined in the supernatant [20], depending on measuring the coloured complex formed between TBA and MDA in acidic medium. Another aliquot of homogenate is centrifuged at 17.000 r.p.m./4°C/20 minutes. The resulted supernatant was used for the determination of nitric oxide (NO), as nitrite (NO_2^-) and nitrate (NO_3^-) concentrations [21], using Griess reagent after the enzymatic reduction of nitrate to nitrite. The Griess reaction involves the reaction of nitrite with

sulfanilamide in an acidic solution to yield a diazonium salt, followed by coupling with N-(1-naphthyl) ethylenediamine to yield a colored azo dye that can be measured colourimetrically at 540 nm.

Measurement of some cardiac antioxidant systems:

A portion of homogenate was mixed with ice-cold 7.5% sulfosalicylic acid (in a ratio 1:1) and centrifuged at 3000 r.p.m/ 15 minutes. The resulted supernatant was used for determination of GSH [22]. Another part of homogenate was mixed with equal volume of ice-cold Tris- EDTA buffer (pH =7.6), centrifuged at 39.000 r.p.m./ 4° C/ 20 minutes. The supernatant was used for determination of superoxide dismutase SOD; glutathione peroxidase (GPx) and glutathione S-transferase (GST). Determination of GST activity [23, 24] depends on the ability of GST to catalyze the formation of glutathione adduct with 1-chloro,2,4 dinitrobenzene(CDNB). This adduct was measured by noting the net increase in absorbance at 340nm. Determination of GPx [25] depends on measuring the rate of oxidized GSH formation, by following up the decrease in absorbance of the reaction at 340 nm as NADPH was converted to NADP. Superoxide dismutase activity was determined [26], depending on the fact that the spontaneous autoxidation of pyrogallol, at alkaline pH less than 9.5, produces superoxide anion, which in turn enhances further oxidation of pyrogallol with a resultant increase in absorbance at 420 nm. The presence of SOD in the reaction medium retards pyrogallol autoxidation by scavenging the formed superoxide anion.

Statistical analysis:

The results were analyzed statistically by one-way analysis of variance (ANOVA test) with subsequent multiple comparisons using Tukey test. Differences were considered statistically significant at p less than 0.05. The results were presented as the mean \pm standard error of the mean (SEM). Data obtained were submitted to a computerized statistical treatment using SPSS statistical package, version 17. Graphs were represented by Harvard graphics version 4 computer program.

3. Results:

Results revealed that Dox caused significant increase in serum levels of LDH and CPK, amounting to 182.4% and 183.6% respectively, as compared to the normal values (Fig. 1). Selenium co-administration caused significant decrease in the activities of LDH and CPK reaching to 139.5% and 153.6%, respectively of the control values. Figure (2) illustrated that, Dox caused a significant increase in cardiac MDA and NO contents, amounting to 183.36% and 177.7%, respectively, compared to the

control values. Concomitant administration with Se caused significant decrease in MDA and NO levels reaching to 126% and 120%, compared to the control values.

As shown in figure (3), Dox administration caused a significant decrease in cardiac GSH level reaching to 64% of the normal values. Co-administration of Se significantly elevated GSH content to about 77.9% of the control values. Figure (4) showed significant increases in cardiac activities of GPx and GST in the Dox-treated rats, amounting to 410% and 184% respectively, compared to the normal values. Meanwhile, the co-administration of Se caused significant decrease in the levels of GPx and GST to about 166% and 136% of the normal values. Figure (5) showed significant increases in cardiac activity of SOD in the Dox-treated rats amounting to 225% compared to the normal value. Co-administration of Se caused significant decrease in the level of SOD to about 172% of the normal values.

Results of figure (6) revealed that Dox administration caused significant elevation in the serum ALT level to reach 118% of the normal control level. Selenium co-administration caused normalization of the elevated ALT level.

Cardiac histopathological results showed that; in the control sections, the cardiac muscle fibers were grouped in bundles with connective tissue in between. The single muscle fiber had acidophilic cytoplasm and a central nucleus (Figure 7). In the cardiac sections obtained from rats administered Dox, hyalinization was observed in the myocardial bundles associated with either inflammatory cells infiltration only or inflammatory cells and edema in focal manner in between the bundles. Edema was also noticed in the subendocardial layer. The subendocardial adipose tissue was infiltrated by inflammatory cells (Figures 8, 9, 10). In the cardiac sections obtained from rats administered Dox + Se, there was mild hyalinization in the myocardial muscle bundles (Figure 11).

Examination of liver sections of the different groups illustrated that: Liver tissue of the normal group showed hepatic lobules with normal architecture (Figure 12). In case of liver sections of rats administered Dox, congestion was observed in the central vein, in addition to kupffer cells proliferation in diffuse manner between the fatty degenerated hepatocytes (Figures 13). In case of liver sections of rats administered Dox + Se, least liver damage was shown, just kupffer cells proliferation was observed in between hepatocytes (Figure 14).

4. Discussion:

Doxorubicin-induced cardiomyopathy has long been a serious side effect in treating human cancers, which limits the clinical dosage of Dox [27]. The mechanism of Dox-induced cardiotoxicity is attributed to the formation of ROS and subsequent changes of membrane fluidity and integrity. Oxidative stress is generally held as the mediating mechanism in the multiple biological processes leading to Dox cardiotoxicity [28]. Nutritional strategies designed to

augment cellular defense systems have been identified as a promising approach to combat oxidative stress-associated disease conditions. In this respect, dietary supplementation with Se, potentially adjusting antioxidant enzymatic status, could offer protection in preventing free radical-induced cardiac injury. In the present study, role of trace element, selenium, in attenuating cardiac and hepatic damages induced by antitumor agent, doxorubicin was studied.

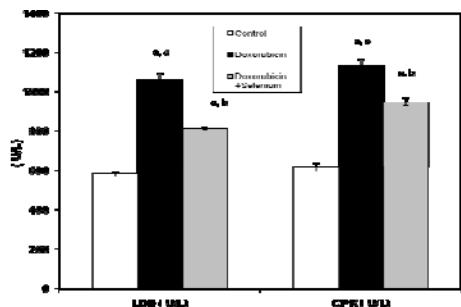


Fig (1): Effect of selenium on doxorubicin-induced alterations in serum lactate dehydrogenase (LDH) and creatine phosphatase (CPE) activities in rats. Values are given as mean ± SD (n=6) of observations are given in parentheses. ^a Significant difference from control group at P<0.05. ^b Significant difference from Doxorubicin group at P<0.05. ^c Significant difference from Doxorubicin + Selenium group at P<0.05.

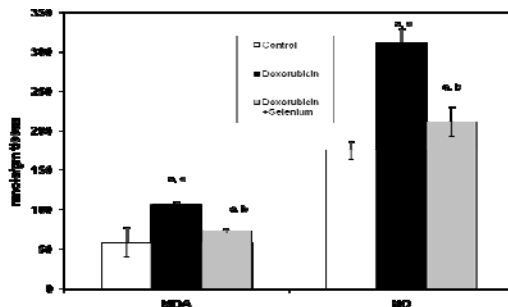


Fig (2): Effect of Selenium on doxorubicin-induced alterations in cardiac malondialdehyde (MDA) and nitric oxide (NO) levels in rats. Values are given as mean ± SD (n=6) of observations are given in parentheses. ^a Significant difference from control group at P<0.05. ^b Significant difference from Doxorubicin group at P<0.05. ^c Significant difference from Doxorubicin + Selenium group at P<0.05.

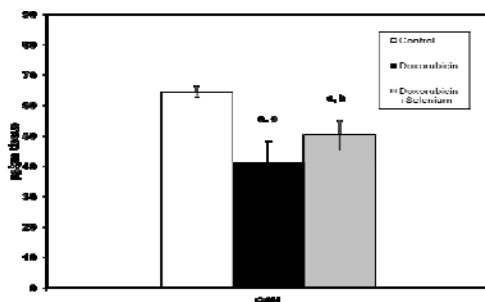


Fig (3): Effect of Selenium on doxorubicin-induced alterations in cardiac glutathione (GSH) content in rats. Values are given as mean ± SD (n=6) of observations are given in parentheses. ^a Significant difference from control group at P<0.05. ^b Significant difference from Doxorubicin group at P<0.05. ^c Significant difference from Doxorubicin + Selenium group at P<0.05.

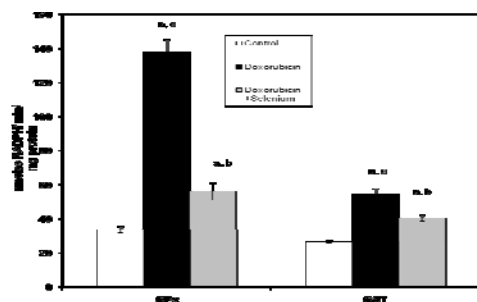


Fig (4): Effect of Selenium on doxorubicin-induced alterations in cardiac glutathione peroxidase (GPx) and glutathione-S-transferase (GST) activities in rats. Values are given as mean ± SD (n=6) of observations are given in parentheses. ^a Significant difference from control group at P<0.05. ^b Significant difference from Doxorubicin group at P<0.05. ^c Significant difference from Doxorubicin + Selenium group at P<0.05.

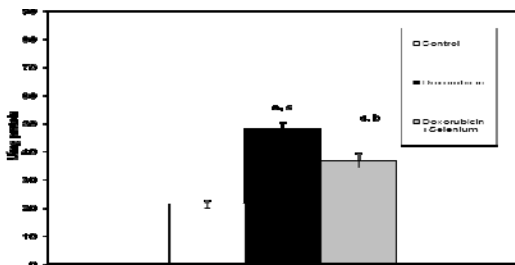


Fig (5): Effect of Selenium on doxorubicin-induced alterations in cardiac superoxide dismutase (SOD) activity in rats. Values are given as mean ± SD (n=6) of observations are given in parentheses. ^a Significant difference from control group at P<0.05. ^b Significant difference from Doxorubicin group at P<0.05. ^c Significant difference from Doxorubicin + Selenium group at P<0.05.

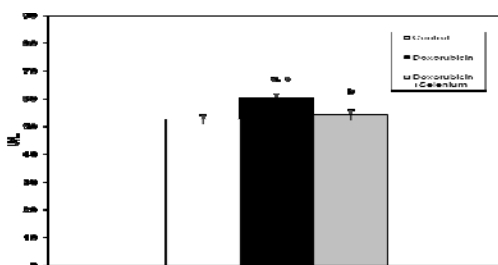
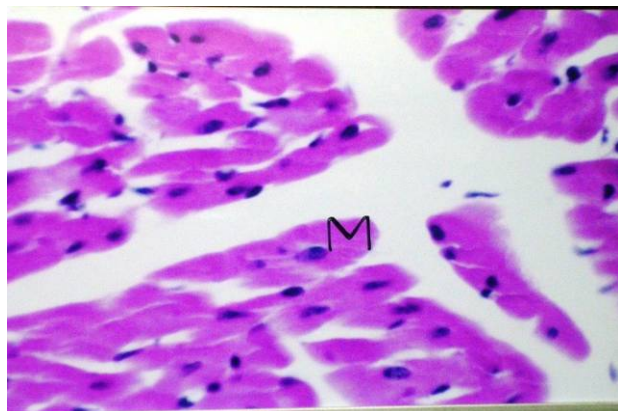
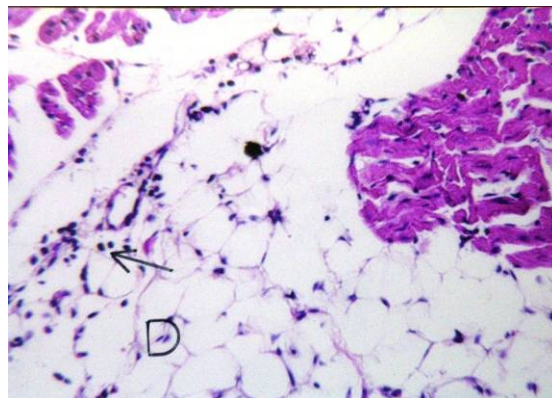


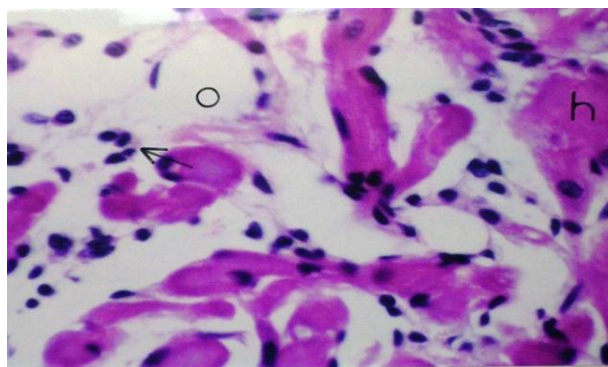
Fig (6): Effect of Selenium on doxorubicin-induced alteration in serum alanine aminotransferase (ALT) activity in rats. Values are given as mean ± SD (n=6) of observations are given in parentheses. ^a Significant difference from control group at P<0.05. ^b Significant difference from Doxorubicin group at P<0.05. ^c Significant difference from Doxorubicin + Selenium group at P<0.05.



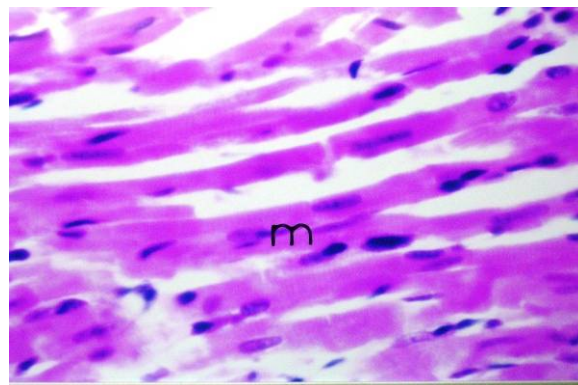
Figure(7): A photomicrograph of cardiac muscle fibers of control group showing normal histological structure of myocardium(M) (H&E x160).



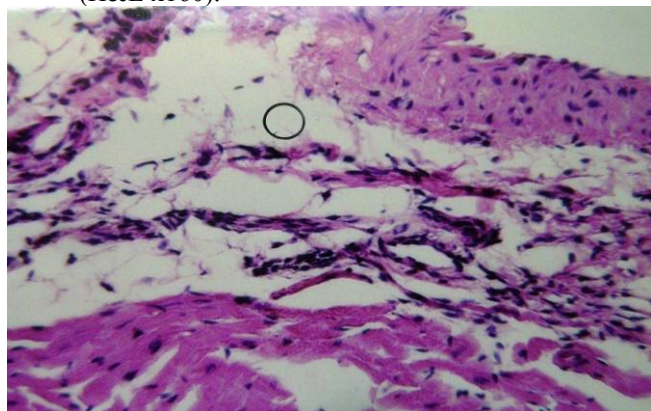
Figure(10): A photomicrograph of cardiac muscle fibers of Dox group showing inflammatory cells infiltration (arrow) in the subendocardial adipose tissue(D) (H&E x64).



Figure(8): A photomicrograph of cardiac muscle fibers of Dxo group showing Oedema(o) with inflammatory cells infiltration (arrow) in focal manner between the myocardial bundles. (H&E x160).



Figure(11): A photomicrograph of cardiac muscle fibers of Dox+Se group showing mild hyalinization in myocardial bundles(m) (H&E x160).



Figure(9): A photomicrograph of cardiac muscle fibers of Dox group showing Subendocardial oedema(o). (H&E x64).

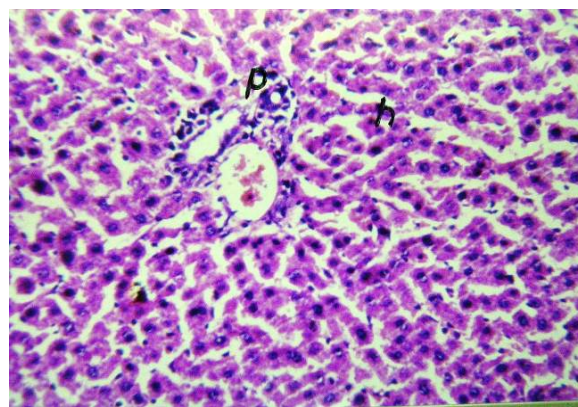
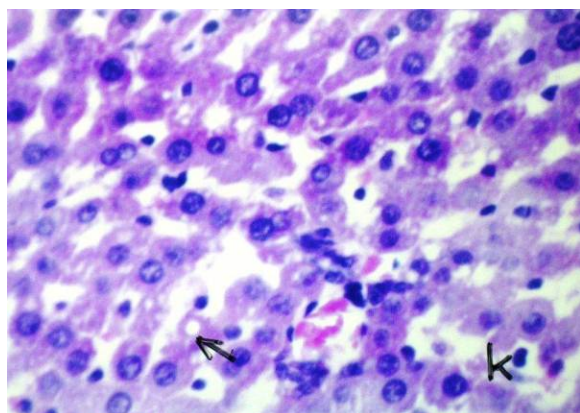


Figure (12): Photomicrograph of liver of normal group showed hepatic lobules (h) and portal vein (p) with normal architecture (H&E x64).



Figure(13): Photomicrograph of liver of Dox group showing diffuse kuffer cells proliferation(k) inbetween the fatty degenerated hepatocytes (arrow) (H&E x160).

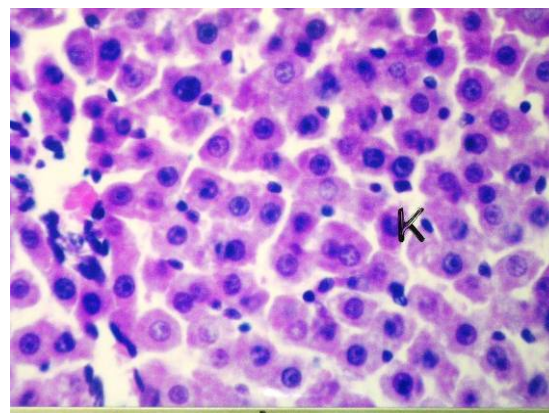


Figure (14): Photomicrograph of liver of Dox + Se group showing diffuse kuffer cells proliferation(k) inbetween the fatty hepatocytes (H&Ex160).

Results of the present study revealed that 15 mg/kg total cumulative dose of Dox induced cardiac and hepatic damages, manifested biochemically by significant increase in serum activities of LDH; CPK and ALT. Additionally, Dox caused elevation in cardiac NO, MDA levels, SOD, GPx, GST activities, and reduction in GSH content. Histopathological examination of heart and liver sections of Dox-treated animals supported these biochemical results. Selenium administration, concomitant to Dox therapy, caused significant decrease in the serum activities of LDH and CPK; cardiac MDA, NO levels, GPx, GST and SOD activities and significant elevation in cardiac GSH content, compared to Dox-treated group values, as well as normalization of serum ALT level.

The present results showed significant increase in serum levels of LDH and CPK in Dox-treated group. These enzymes are considered important markers of cardiac injury. Many previous studies have demonstrated similar results in rats following Dox administration [29, 30]. Different types of Dox cardiotoxicity can be recognized [31]: “Acute” cardiotoxicity occurs during Dox administration, however, these effects are never of major concern because these are generally reversible and/or clinically manageable. “Early chronic” cardiotoxicity develops later in the Dox treatment course and characterized by dilated cardiomyopathy, with subsequent development of congestive heart failure [32]. It is now well established that Dox cardiotoxicity may manifest even decades after the completion of anticancer treatment [33]. Co-administration of Se with Dox therapy resulted in decrease in the elevated activities of serum LDH and CPK. This finding is in harmony with this stated by Simoni *et al.*[34], who reported that the elevation in

serum LDH activity, as a result of hemoglobin cardiotoxicity, is significantly decreased by Se dietary supplementation. Our biochemical results are supported by the histopathological examination of the cardiac tissue, since, the marked morphological changes shown in the hearts of Dox- treated animals have been partially preserved by Se administration.

Dox therapy caused significant increase in MDA level. Previous studies reported similar results [35, 36]. This elevation might be attributed to Dox mediated oxidative stress. Heart tissue is rich in mitochondria, which occupy about forty percent of the total intracellular volume of cardiomyocytes [37]. Dox has high affinity for cardiolipin, a negatively charged phospholipid abundant in the mitochondrial inner membrane, leading to mitochondrial accumulation of Dox [38]. Under clinically relevant plasma Dox concentrations, the heart becomes a site of redox reactivity. The quinone functionality of Dox is transformed, in the presence of NADH, into a semiquinone via one-electron reduction by complex I of the electron transport chain [39]. The semiquinone form reacts with O₂ to produce a superoxide radical (O^{•-}), whereby Dox returns to the quinone form. The cycling of Dox between quinone and semiquinone generates large amounts of O₂, which further give rise to a variety of ROS/RNS species [40]. ROS can damage membrane lipids and other cellular components and consequently lead to cardiomyocyte apoptosis or death [41]. Our results showed that lipid peroxidation induced by Dox is significantly decreased in the pretreatment of Se, as manifested by significant reduction in the elevated level of cardiac MDA, which is consistent with previous studies [34, 42]. Previously, it was reported that Se supplementation can protect against free radical

damages by increasing myocardial Se content and improving the expression and activity of GPx [43].

The present study revealed a marked increase in cardiac NO level in those Dox-treated rats. This finding is in agreement with the results reported by Saad *et al* [36] who used a model of doxorubicin chronic cardiotoxicity similar to that used in our study. The increase in NO level can be explained on the basis of the ability of Dox to mediate the induction of NOS expression and NO release in heart [44]. Several reports indicate that exposure of endothelial cells to H₂O₂ promotes eNOS expression [45]. Previous studies also suggested that stimulation of endothelial cells with calcium-mobilizing agents could activate eNOS [46]. Because Dox-induced toxicity is mediated by intracellular H₂O₂ as well as the calcium influx, Dox treatment causes an increase in eNOS transcription and protein activity in aortic endothelial cells and thus NO synthesis. On the same line, recent study provides evidence of upregulation of iNOS gene and protein expressions in Dox-induced cardiomyopathy [47]. The concomitant overproduction of NO and ROS is known to yield highly reactive nitrogen species, peroxynitrite, which may attack and destroy important cellular biomolecules [48]. Selenium, in the present study, caused significant decrease in the elevated cardiac NO level shown in the Dox-treated group, which is in agreement with that reported by Ayaz and Turan [49]. The exact mechanism by which Se influence cardiac NO synthases expression is unknown. Of interest in this context is the report that treatment of nuclear extracts of lipopolysaccharide-activated human T cells with relatively high concentrations of selenite inhibited nuclear factor- κ B binding and thus decreased NO production [49]. This is because nuclear factor- κ B is a transcription factor that regulates a number of cellular genes, such as those encoding iNOS [50].

Doxorubicin administration, as shown in our results, caused a significant decrease in cardiac GSH content, which is quite compatible with previous studies [35]. The overproduction of ROS, caused by Dox administration, can account for this decrease in GSH content, as these species are detoxified by endogenous antioxidants mainly GSH causing their cellular stores to be depleted [51]. The decrease of cardiac GSH content may also be attributed to the enhanced activities of GSH metabolizing enzymes by Dox administration, as shown in the present study. One is GPx which reduces H₂O₂ and various peroxides using GSH as reducing agent. The other is GST which consumes GSH in the conjugation of Dox toxic metabolites [52]. The present study showed that cardiac GSH concentration is higher in (Se+ Dox) -treated rats rather than those administered Dox alone,

which is in agreement with recent results [53]. Such effect might be attributed to the antioxidant properties of Se and its ability to reduce Dox-induced oxidative stress. Selenium reduces the consumption of GSH by ROS [53]. Because GSH is one of the essential compounds for maintaining cell integrity [54] and the GSH redox cycle is one of the most important intracellular antioxidant systems, the increase in GSH content could be one of the mechanisms for cardiac protection by Se supplementation [53]. In addition, we assumed that the observed increase in cardiac GSH content might be related to the decreased activities of GSH-utilizing enzymes, GPx and GST, shown in the (Dox + Se)-treated group, leading to preservation of their substrate, GSH.

Our results showed significant increase in cardiac activity of SOD in the Dox-treated rats, which is consistent with some studies [35, 55]. The increase in SOD activity can be explained on the basis that the redox cycling of Dox between quinone and semiquinone forms generates large amounts of O₂ [40], which in turn stimulate SOD as an adaptive response to counteract oxidative stress. The increased activity of SOD could lead to overproduction of hydroperoxides, in consequence, GPx might be stimulated in response to the accumulated peroxides. This assumption was supported by our results, which showed a significant enhancement in cardiac GPx activity in the Dox-treated group, and also by some authors [36]. On the same line, GPx have been reported to be over expressed in Dox-treated cells, especially those tumor resistant ones [56]. The current study revealed that Se administration caused significant decrease in Dox-induced elevation in SOD cardiac activity, which still higher than that of the normal group value. This result is in harmony with several previous studies. Selenium has been reported to decrease the elevated activity of SOD in heart as a result to cadmium toxicity [57] and hemoglobin mediated cardiotoxicity [34], which used Se dose similar to that used in our study. It is now well established that Se, through its incorporation in selenoproteins, could actively protect against free radicals generation, and hence, ROS-induced damage [58]. As a result of this protective effect, Se consumption could attenuate superoxide radical production, and consequently, decreased the activity of such antioxidant enzyme. Also, our study showed that pretreatment with Se relieved Dox induced hyperactivity of cardiac GPx, which is in harmony with Ayaz and Turan [49]. Glutathione peroxidase is one of the most active antioxidant enzymes in the myocardium [59], and selenium, present in its active site, is essential for its activity. One of the major roles of this essential trace element in the body is to act as cofactor of this key antioxidant enzyme in which it

contributes to both catalytic activity and spatial conformation [60]. Therefore, any significant modification of Se status would lead to changes in the activity of GPx and have important consequences on the susceptibility of the tissues to oxidative stress [13, 61]. Selenium has prophylactic action, when it is administered before doxorubicin, it increases myocardial selenium content and improves both expression and activity of GPx. This may account for the increased cardiac GPx activity in (Se+ Dox)-treated group, compared to the normal control value, as shown in our results. Upon pretreatment with Se, myocardial tissues became already protected, and therefore, when exposed to Dox, we assume that there is no need for farther dramatic increase in cardiac GPx activity as an adaptive mechanism. This might be an explanation for the decrease in GPx cardiac activity in (Se+Dox) group value, compared to that result shown in the group treated with Dox alone. Additionally, the obtained biochemical results were supported by each other, since, as we mentioned later, Se supplementation caused decrease in the SOD activity, which consequently, leads to decreased production of H₂O₂ and hence, decreased activity of GPx enzyme.

Results of the present study revealed significant increase in cardiac GST activity in rats treated with Dox, which is in agreement with many studies [62]. GSTs are family of dimeric proteins that possess a multitude of functions including the enzymatic conjugation of GSH to electrophilic xenobiotics [63]. It has been reported that cellular exposure to xenobiotics and antioxidants leads to coordinated induction of a battery of genes encoding detoxifying enzymes including GST [64]. Indeed, GSTs belong to phase II enzymes that in contrast to phase I, who can participate in both metabolic activation and inactivation, predominately participate in the detoxification of xenobiotics [65]. It has been known that Dox is metabolized via aldo-ketoreductases yielding C13 hydroxyl derivative, doxorubicinol. This metabolite is actually more polar and toxic than Dox itself. Doxorubicinol accumulates in the heart and contributes significantly to chronic cumulative cardiotoxicity induced by Dox [8]. It has been reported that Dox toxic metabolites are efficiently conjugated with reduced GSH, a reaction that is catalyzed by GST [52]. Moreover, GST, due to its peroxidase activity, can serve to reduce Dox-induced peroxides [52]. In brief, GST has showed elevation after Dox injection to detoxify Dox and its metabolites and to attenuate the elevated oxidative stress [66]. The current study revealed that Se caused significant decrease in Dox-induced elevation in GST cardiac activity, which still higher than that of the normal group value. This result is in agreement with

previous studies stated that Se afforded reduction in cadmium- induced elevation in GST cardiac activity [57]. The protective effects of Se are mainly related to its physiological antioxidant properties, and hence, decreased generation of ROS and RNS. Thus, Se supplementation could decrease the activity of GST enzyme responsible for the detoxification of such free radicals.

Our results showed an elevation in serum ALT upon Dox administration which agrees with many previous studies [67, 68] and supported by the present histopathological examinations. Doxorubicin-induced hepatotoxicity might be less severe than its cardiotoxicity, which can be related to the fact that liver mitochondria, unlike cardiac mitochondria, lack the NADH-related pathway of reducing equivalents from the cytosol to the respiratory chain. As a result, liver mitochondria do not generate significant amounts of Dox semiquinones [69]. Selenium co-administration was shown to decrease the elevated serum ALT when administered with Dox, as reported previously [34]. Selenium supplementation could reduce hepatotoxicity by rendering hepatic tissues less susceptible to lipoperoxidative attack by the drug [70]. Selenium prevents hepatocyte oxidative damage and thus leakage of liver enzymes into serum as in the cases of cadmium hepatotoxicity [71]. This biochemical result is supported by the histopathological examination of liver sections of the different groups which illustrated that, in the liver sections of rats administered Dox, congestion and kupffer cells proliferation were observed, while sections from rats administered Dox+Se showed least liver damage.

In conclusion, Se supplementation produced partial, but significant, protection against Dox-induced cardiomyocyte damage; however, such trace element could alleviate the Dox-induced hepatic damage, as evidenced by the biochemical measurements and histopathological examinations of the cardiac and hepatic tissues.

Acknowledgements:

We are thankful to Dr. Mohamed A Ali, Assistant professor of Histology, Faculty of Medicine, Cairo University, for his professional help in carrying out the histopathological examination.

Corresponding Author:

Safinaz S. Ibrahim
Biochemistry Department, Faculty of Pharmacy,
Cairo University, Cairo, Egypt
safinazsibrahim@cu.edu.eg

5. References

1. Weiss RB (1992): The anthracyclines: will we ever find a better doxorubicin? *Semin Oncol*, 19, 670–686.
2. Arcamone, F., Cassineli, G., Fantini, G., Grein, A., Orezzi, P., Pol, C., and Spalla, C. (1969): Adriamycin, 14-hydroxydaunomycin, a new antitumor antibiotic from *S. peucetius* var. *caesius*. *Biotechnol. Bioengin.* 9, 1101-1110.
3. Bonadonna, G.; M. and Valagussa, P. (1996): Sequential or alternating doxorubicin and CMF regimens in breast cancer with more than three positive nodes. *JAMA*, 237, 542-547.
4. Bacci, G.; Ferrari, S. and Delepine, N. (1998): predictive factors of histologic response to primary chemotherapy in osteosarcoma of extremity. *J. Clin. Oncol.*, 16, 658-663.
5. Kufe DW, Holland JF, Frei E, (2003): American Cancer Society: Cancer medicine 6., BC Decker, Hamilton.
6. Muindi JR, Sinha BK, Gianni L, Myers CE (1984): Hydroxyl radical production and DNA damage induced by anthracycline iron complex. *FEBS Lett*, 172, 226–230.
7. Gewirtz DA (1999): A critical evaluation of the mechanisms of action proposed for the antitumor effects of the anthracycline antibiotics adriamycin and daunorubicin. *Biochem Pharmacol* 57: 727–741.
8. Olson, RD, Mushlin, PS, Brenner, DE, Fleischer, C, Change, BK and Baucke, RJ (1988): Doxorubicin cardiotoxicity may be caused by its metabolite, doxorubicinol. *Proc. Natl. Acad. Sci. USA.*, 85: 3585-3589.
9. Lage, M, Helbach H, Dietel M, and Schandorf, D (2000): Modulation of DNA topoisomerase II activity and expression in melanoma cells with acquired drug resistance. *Br J Cancer* 82: 488 – 491.
10. Bryant J, Picot J, Levitt G, Sullivan I, Baxter L, Clegg A. (2007): Cardioprotection against the toxic effects of anthracyclines given to children with cancer: a systematic review. *Health Technol Assess* 11: 1-84.
11. Rayman MP (2002): The argument for increasing selenium intake. *Proceeding of the Nutrition Society.* 61: 203–215.
12. Combs GF and Lu J (2001): Selenium as a cancer preventative agent. In *Selenium. Its Molecular Biology and Role in Human Health*, pp 205–219. Ed DL Hatfield. Boston: Kluwer Academic Publishers.
13. Tanguy S, Boucher F, Besse S, Ducros V, Favier A, de Leiris J. (1998): Trace elements and cardioprotection: increasing endogenous glutathione peroxidase activity by oral selenium supplementation in rats limits reperfusion-induced arrhythmias. *J. Trace Elem. Med. Biol.*; 12: 28–38.
14. Matsui H, Morishima I, Numaguchi Y, Toki Y, Okumura K, Haayakawa T. (1999): Protective effect of carvedilol against doxorubicin-induced cardiomyopathy in rats. *Life Sci.*; 65(12): 1265-74.
15. Eun-sung Park, Sun-dong Kim, Min-hye Lee, Heung-shik S. Lee, In-se LEE, Je-Kyung Sung (2003): Protective effects of N-acetylcysteine and selenium against doxorubicin toxicity in rats. *J. Vet. Sci.*, 4(2), 129-136.
16. Rosalki SB. (1967): An improved procedure for serum creatine phosphokinase determination. *J Lab Clin Med.* 69(4):696-705.
17. Buhl SN, Jackson KY. (1978): Optimal conditions and comparison of lactate dehydrogenase catalysis of the lactate-to-pyruvate and pyruvate-to-lactate reactions in human serum at 25, 30, and 37 degrees C. *Clin Chem.* 24(5):828-31.
18. Reitman, S and Frankel, S (1957): a colorimetric method for the determination of serum glutamic oxaloacetic acid and glutamic pyruvic transaminases. *Am. J. Clin. Pathol.*, 28, 56.
19. Bancroft, J.D; Stevens, A. and Turner, D.R. (1996): theory and practice of histopathological techniques. fourth Ed. Churchill Livingstone, New York, London, San Francisco, Tokyo
20. Uchiyama M, Mihara M. (1978): Determination of malonaldehyde precursor in tissues by thiobarbituric acid test. *Anal Biochem*; 86: 271-288.
21. Tracey WR, Tse J, Carter G. (1995): Lipopolysaccharide-induced changes in plasma nitrite and nitrate concentrations in rats and mice: pharmacological evaluation of nitric oxide synthase inhibitors. *J Pharmacol Exp Ther*; 272: 1011-1015.
22. Beutler E, Duron O, Kelly BM. (1963): Improved method for the determination of blood glutathione. *J Lab Clin Med* 61:882-888.
23. Habig, WH, Pabst, MJ and Jakoby, WB (1974): Glutathione S-transferase: the first enzymatic step in mercapturic acid formation. *J. Biol. Chem.*, 249, 7130-7139.

24. Gawai, KR and Pawar, SS (1984): Purification and characterization of glutathione S-transferase from liver cytosol of Phenobarbital treated rabbits *Xenobiotica*, 4, 605-607.
25. Paglia DE, Valtentine WN. (1967): Studies on the quantitative and qualitative characterization of erythrocyte glutathione peroxidase. *J Lab Clin Med*; 70: 158-161.
26. Marklund S, Marklund G. (1974): Involvement of superoxide anion radical in autooxidation of pyrogallol and convenient assay for superoxide dismutase. *Eur J Biochem*; 47: 469-474.
27. Horan PG, McMullin MF, McKeown PP. (2006): Anthracycline cardiotoxicity. *Eur Heart J*; 27: 1137-1138.
28. Kotamraju S, Chitambar CR, Kalivendi SV, Joseph J, Kalyanaraman B. (2002): Transferrin receptor-dependent iron uptake is responsible for doxorubicin-mediated apoptosis in endothelial cells - role of oxidant-induced iron signaling in apoptosis. *Journal of Biological Chemistry*; 277: 17179-17187.
29. Al-majed A, Gado A, Al-shabanah O, Mansour MA. (2002): Alpha-lipoic acid ameliorates myocardial toxicity induced by doxorubicin. *Pharmacol Res*; 46(6): 499-503.
30. Yagmurca M, Fadillioglu E, Erdogan H, Ucar M, Sogut S, Irmak MK. (2003): Erdosteine prevents doxorubicin-induced cardiotoxicity in rats. *Pharmacol Res*; 48: 377-82.
31. Wouters KA, Kremer LC, Miller TL, Herman EH, Lipshultz SE (2005): Protecting against anthracycline-induced myocardial damage: a review of the most promising strategies. *Br J Haematol*, 131, 561-578.
32. Jones RL, Swanton C, Ewer MS (2006): Anthracycline cardiotoxicity. *Expert Opin Drug Saf*, 5, 791-809.
33. Scully RE, Lipshultz SE (2007): Anthracycline cardiotoxicity in long-term survivors of childhood cancer. *Cardiovasc Toxicol*, 7, 122-128.
34. Simoni J, Simoni G, Garcia EL, Prien SD, Tran RM, Feola M, Shires GT. (1995): Protective effect of selenium on hemoglobin mediated lipid peroxidation in vivo. *Artif Cells Blood Substit Immobil Biotechnol*; 23(4): 469-86.
35. Balachandar AV, Malarkodi KP, Varalakshmi P. (2003): Protective role of DL-alpha-lipoic acid against adriamycin-induced cardiac lipid peroxidation. *Hum Exp Toxicol*. May; 22(5): 249-54.
36. Saad SY, Najjar TA, Alashari M. (2004): Cardiotoxicity of doxorubicin/paclitaxel combination in rats: effect of sequence and timing of administration. *J Biochem Mol Toxicol*. 18(2):78-86.
37. Goffart, S., von Kleist-Retzow, J.C., Wiesner, R.J. (2004): Regulation of mitochondrial proliferation in the heart: Power-plant failure contributes to cardiac failure in hypertrophy. *Cardiovasc. Res*. 64, 198-207.
38. Sarvazyan, N. (1996): Visualization of doxorubicin-induced oxidative stress in isolated cardiac myocytes. *Am. J. Physiol. Heart Circ. Physiol*. 271, H2079-2085.
39. Marcillat, O, Zhang, Y, and Davies, KJ (1989): Oxidative and non-oxidative mechanisms in the inactivation of cardiac mitochondrial electron transport chain components by doxorubicin. *Biochem. J*. 259, 181-189.
40. Takemura G, Fujiwara H (2007): Doxorubicin-induced cardiomyopathy from the cardiotoxic mechanisms to management. *Prog Cardiovasc Dis*; 49: 330-352.
41. Menna P, Minotti G, Salvatorelli E. (2007): *In vitro* modeling of the structure-activity determinants of anthracycline cardiotoxicity. *Cell Biol Toxicol*; 23: 49-62.
42. Ates B, Orun I, Talas ZS, Durmaz G, Yilmaz I. (2008): Effects of sodium selenite on some biochemical and hematological parameters of rainbow trout (*Oncorhynchus mykiss* Walbaum, 1792) exposed to Pb²⁺ and Cu²⁺. *Fish Physiol Biochem*; 34(1): 53-9.
43. Huang Y, Bai H, Zhang Z. (1999): Mechanism of selenium protecting against free radical damages during myocardial ischemia/reperfusion in rats. *Zhonghua Yi Xue Za Zhi*; 79(11):852-6.
44. Fogli S, Nieri P, Breschi MC. (2004): The role of nitric oxide in anthracycline toxicity and prospects for pharmacologic prevention of cardiac damage. *FASEB J*; 18 (6): 664-75.
45. Drummond GR, Cai H, Davis ME, Ramasamy S, Harrison DG. (2000): Transcriptional and Posttranscriptional Regulation of Endothelial Nitric Oxide Synthase Expression by Hydrogen Peroxide. *Circ. Res*. 86: 347-354.
46. Goetz RM, Thatte HS, Prabhakar P, Cho MR, Michel T, Golan DE (1999): Estradiol

- induces the calcium-dependent translocation of endothelial nitric oxide synthase; *Proc. Natl. Acad. Sci. U. S. A.* 96:2788–2793.
47. Liu B, Li H, Qu H, Sun B. (2006): Nitric oxide synthase expressions in ADR-induced cardiomyopathy in rats. *J Biochem Mol Biol.* 30; 39(6): 759-65.
 48. Weinstein DM, Mihm MJ, Bauer JA (2000): Cardiac peroxynitrite formation and left ventricular dysfunction following doxorubicin treatment in mice. *J Pharmacol Exp Ther*, 294, 396–401.
 49. Ayaz M, Turan B. (2006): Selenium prevents diabetes-induced alterations in [Zn²⁺] and metallothionein level of rat heart via restoration of cell redox cycle. *Am J Physiol Heart Circ Physiol.*; 290(3): H1071-80.
 50. Griscavage JM, Wilk S, Ignarro LJ. (1996): Inhibitors of the proteasome pathway interfere with induction of nitric oxide synthase in macrophages by blocking activation of transcription factor NF-kappa B. *Proc Natl Acad Sci USA.* 16; 93(8): 3308-12.
 51. Thomas JA. (1994): Oxidative stress: Oxidant defense and dietary constituents. In: Maurice E, Shils ME, Olson JA, Shike M, editors. *Modern Nutrition in Health and Disease*. Charlottesville, University of Virginia: Awaverly Company; pp. 501-512.
 52. O'Brien ML, Tew KD (1996): Glutathione and related enzymes in multidrug resistance. *Eur J Cancer*; 32A: 967–78.
 53. Danesi F, Malaguti M, Nunzio MD, Maranesi M, Biagi PL, Bordoni A. (2006): Counteraction of adriamycin-induced oxidative damage in rat heart by selenium dietary supplementation. *J Agric Food Chem.* 22; 54(4): 1203-8.
 54. Conklin, KA (2000): Dietary antioxidants during cancer chemotherapy: Impact on chemotherapeutic effectiveness and development of side effects. *Nutr. Cancer* 37, 1-18.
 55. Signal PK; Siveski-Iiskovic; Hill, M; Thomas, TP and Li, T (1995): Combination therapy with probucol prevents adriamycin-induced cardiomyopathy. *J Mol. Cell Cardiol.*, 27: 1055-1063.
 56. Doroshow, JH, Akman, S, Esworthy, S, Chu, FF & Burke, T (1991): Doxorubicin resistance conferred by selective enhancement of intracellular glutathione peroxidase or superoxide dismutase content, *Free Radical Res. Commun.* 12 – 13 Pt 2:779-81.
 57. Zikić RV, Stajn AS, Ognjanović BI, Sačić ZS, Kostić MM, Pavlović SZ (1998): The effect of cadmium and selenium on the antioxidant enzyme activities in rat heart. *J Environ Pathol Toxicol Oncol.*; 17(3-4): 259-64.
 58. Holben DH, Smith AM. (1999): The diverse role of selenium within selenoproteins: a review. *J. Am. Diet. Assoc.*; 99: 836–843.
 59. Dhalla NS, Elmoselhi AB, Hata T, Makino N. (2000): Status of myocardial antioxidants in ischemia-reperfusion injury. *Cardiovasc Res.* 18; 47(3): 446-56.
 60. Rotruck JT, Pope AL, Ganther HE, Swanson AB, Hafeman DG, and Hoekstra WG. (1973): Selenium: biochemical role as a component of glutathione per-oxidase. *Science* 179: 588–590.
 61. Pucheu S, Coudray C, Tresallet N, Favier A, de Leiris J. (1995): Effect of dietary antioxidant trace element supply on cardiac tolerance to ischemia-reperfusion in the rat. *J Mol Cell Cardiol.*; 27(10): 2303-14.
 62. Paranka NS, Dorr RT. (1994): Effect of doxorubicin on glutathione and glutathione-dependent enzymes in cultured rat heart cells. *Anticancer Res.*; 14(5A): 2047-52.
 63. Hayes, JD, and Pulford DJ (1995): The glutathione S-transferase supergene family: regulation of GST and the contribution of the isoenzymes to cancer chemoprotection and drug resistance. *Rev. Biochem. Mol. Biol.* 30: 445-600.
 64. Venugopal, R; Joseph, P and Jaiswal, AK (1997): Gene expression of DT-diaphorase in cancer cells. In: *Oxidative stress and signal induction*. (Forman, H.j. and Cadenas, E. eds.), P. 441. Chapman & Hall, New York.
 65. Wang, CJ; Wang, SW; Shiah, HS and Lin, JK (1990): Effect of ethanol on hepapyoxicity and hepatic DNA-binding of aflatoxin B1 in rats. *Biochem. Pharmacol.*, 40(4), 715-712.
 66. L'Ecuyer T, Allebban Z, Thomas R, Heide R Vander. (2004): Glutathione S-transferase overexpression protects against anthracycline-induced H9C2 cell death. *Am J Physiol Heart Circ Physiol.*; 286: 2057–2064.
 67. Deepa PR, Varalakshmi P. (2003): Protective effect of low molecular weight heparin on oxidative injury and cellular abnormalities in adriamycin-induced cardiac

- and hepatic toxicity. *Chem Biol Interact.* 25; 146(2): 201-10.
68. Jagetia GC, Reddy TK, Malagi KJ, Nayak BS, Naidu MB, Ravikiran PB, Kamath SU, Shetty PC, Reddy DS. (2005): Antarth, a polyherbal preparation protects against the doxorubicin-induced toxicity without compromising its Antineoplastic activity. *Phytother Res.*; 19(9): 772-8.
69. Nohl H, Gille L, Staniek K (1998): The exogenous NADH dehydrogenase of heart mitochondria is the key enzyme responsible for selective cardiotoxicity of anthracyclines. *Z Naturforsch [C]*, 53, 279–285.
70. Bulucu F, Ocal R, Karadurmus N, Sahin M, Kenar L, Aydin A, Oktenli C, Koc B, Inal V, Yamanel L, Yaman H.(2009): Effects of N-Acetylcysteine, Deferoxamine and Selenium on Doxorubicin-Induced Hepatotoxicity. *Biol Trace Elem Res.* 132:184-196.
71. Newairy AA, El-Sharaky AS, Badreldeen MM, Eweda SM, Sheweita SA. (2007): The hepatoprotective effects of selenium against cadmium toxicity in rats. *Toxicology.* 5;242(1-3):23-30.

10/2/2010