Case report: successful excision of one tertiary recurrent posterior fossa solid hemangioblastoma

Zhihua Li[1], Fuyou Guo[2,*], Laijun Song[2]

[1]*Department of Anatomy, Basic Medical College, Zhengzhou University, Henan* 450052, *China;* [2]*Department of Neurosurgery, The first Affiliated Hospital of Zhengzhou University, Zhengzhou, Henan* 450052, *China*

Received October 23, 2008

Abstract

Surgical treatment of the recurrent cerebellar solid hemangioblastoma remains to be challenged due to highly vascular benign neoplasms and abnormal anatomical structure, one rare case with tertiary recurrent cerebellar solid hemangioblastoma experienced successful operation, preoperative embolization and intraoperative neurophysiological monitoring as well as surgical technique were contributed to total resection in present report. [Life Science Journal. 2009; 6(1): 33 – 36] (ISSN: 1097 – 8135).

1 Introduction

Hemangioblastomas are highly vascular benign neoplasms that comprise approximately 1.5% – 2.5% of all intracranial tumors and 7% – 10% of primary posterior fossa lesions in the adult. They occur sporadically (80%) or in association with von Hippel-Lindau (VHL) disease (20%). The surgical removal of solid, large, and deep-seated hemangioblastomas remains challenging because it is difficult to control bleeding during the operation and post-operation complications[1,2]. Previous literature reported that 9% (2/22) of patients with posterior fossa solid hemangioblastomas (PFSHs) died after microsurgery owing to brain-stem injury and the intracranial hemorrhage[3]. Moreover, partial resection of hemagioblastoma was usually confronted tumor recurrence[4]. The tumor of an unusual case with tertiary recurrent PFSHs was successfully removed by us via preoperative embolization and intraoperative neurophysiological monitoring.

2 Case Presentation

A 50-year-old woman who had suffered from dramatic dizziness and vomiting (especially with position alteration) and gait titubation for one year was referred to our hospital in October 2006. Before admission, she had undergone initial surgical treatment in 1978 for sporadic hemangioblastoma. The second resection was performed in 1994 due to the recurrence. There was no family history of VHL disease. Neurological examination indicated the papilledema of funduscope and the Romberg sign was positive. CT scan revealed that the volume of tumor was 48 × 41 × 35 mm^3, and obstructive hydrocephlus and artifact of previous silver clip were simultanously observed. MRI showed that the diameter of the mass was 43 × 36 × 40 mm^3 at vermis with compression of brain stem and the fourth ventricle. Vascular-flow void was also be displayed on MRI due to major feeding or draining vessels in the surrounding tissue (Figure 1 A & B). Digital subtraction angiography showed highly vascular with feeders from the superior cerebellar artery and anterior inferior cerebellar artery (AICA). The staining of tumor was remarkably diminished after preoperative embolization (Figure 1 C & D).

Microsurgical treatment was performed via midline suboccipital approach. Real-time intraoperative neurophysiological monitoring of brain stem, facial and trigeminal nerves was applied to guide the extent of removal and disclose the margin of tumor. Histological identity demonstrated the tumor was comprised of capillary-sized blood vessels throughout the tissue. Hemangioblastoma was proved by definite pathological examination. Postoperative MRI showed that the tumor was completely excised (Figure 1 E & F). Obstructive hydrocephlus disappeared spontaneously with the resection of PFSHs,

*Corresponding author. Email: chyou666@hotmail.com

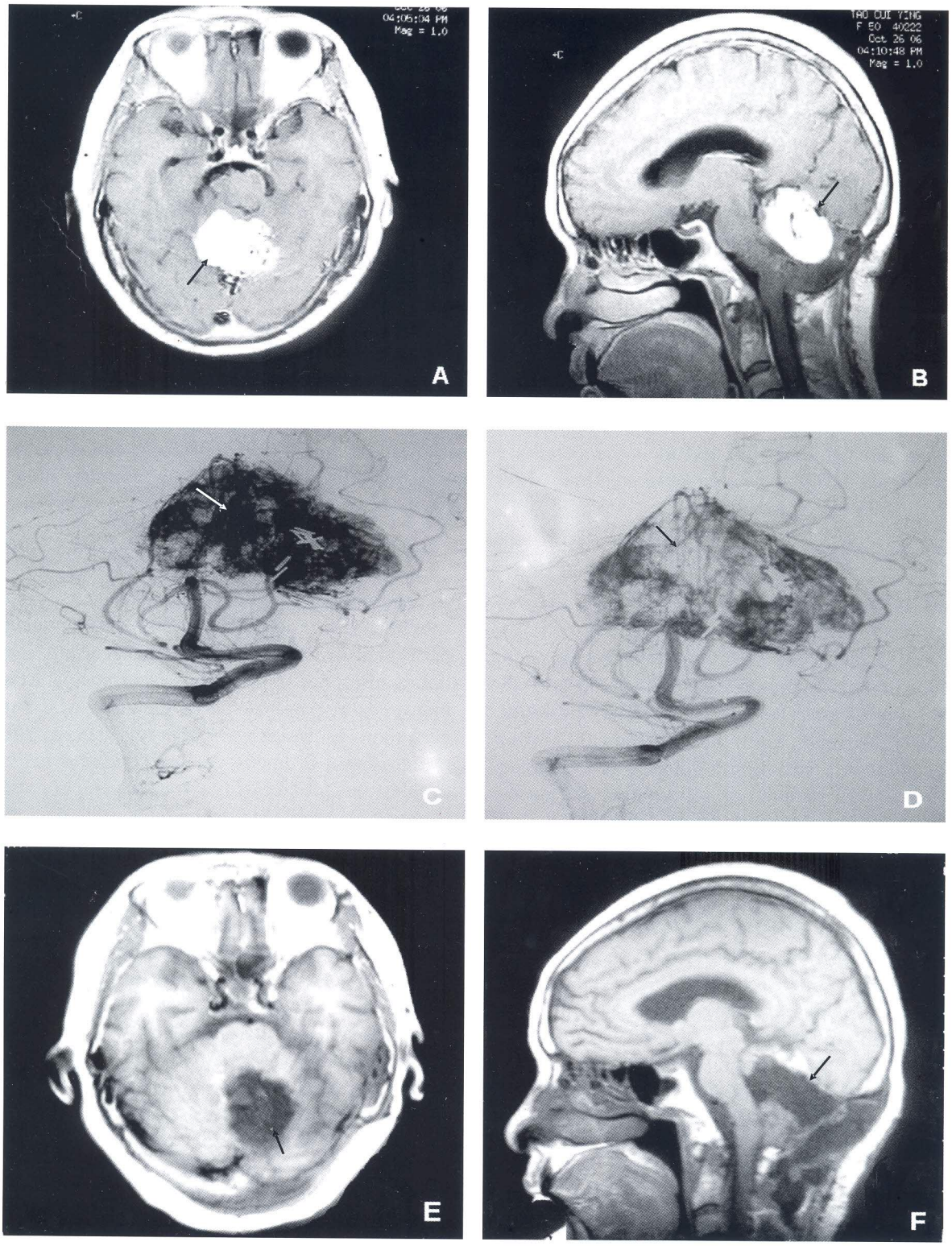

Figure 1. Uniform enhancement of tumor was observed after administrating the Gadolinium on axial and sagittal T1-weighted images respectively. A & B: Adjacent structure including brain stem and fourth ventricle were exceedingly compressed (arrow); C & D: Digital subtraction angiogram (DSA) demonstrated the tumor staining was significantly reduced after embolization (arrow); E & F: Axial and sagittal MRI exhibit large recurrent PFSH was total removed respectively (arrow).

and the symptoms caused by space-occuping lesion was prominently ameliorated. The patient made an uneventful recovery. She is under regular follow-up for 20 months and is showing satisfactory recovery.

3 Discussion

Microsurgical excision is the standard therapy for intracranial vascular tumors, which can alleviate mass effect and eliminate the need for adjuvant radiation therapy (if a total resection can be achieved)[4,5], gamma knife radiosurgery has been regarded as a useful and reliable therapy for residual, multiple lesions, small- or medium-sized hemangioblastoma[6,7]. It's challenging to choosing an optimal treatment for present case as the tertiary recurrent cerebellar solid hemangioblastoma was difficult to be removed safely and completely, especially when the normal anatomical structure had been thoroughly changed after two surgeries, which would lead easily to damage of the adjacent critical neurovascular structures. In addition, whole enhancement of the tumor on preoperative MRI and abundant artery feeding on DSA means immense risk for operation. Whereas, if the gamma knife was adopted for current patient, the main symptoms was usually exacerbated by delayed radiation edema, particularly this case with marked obstructive hydrocephalus may leads to sudden death due to elevated intracranial pressure in posterior fossa after radiation. Wolff[8] reported that deterioration of patient was associated with acute edema induced radiation, which could result in a block of the CSF pathways. Furthermore, satisfactory outcome of gamma knife for hemangioblastoma was obtained when the mean tumor diameter was 13 mm[9]. Unfortunately, the diameter of present tumor surpassed 4 cm, so microsurgical treatment was applied to it under special skills finally.

Successful microsurgical resection of a huge PFSHs requires preoperative embolization and surgical skill as well as intraoperative judgment. The principle of minimally invasive technique must be emphasized during the resections of recurrent PFSHs. The intraoperative profuse bleeding always results in major mortality and morbidity in surgical removal of solid hemangioblastoma. Preoperative embolization, if feasible, may significantly reduce tumor blood supply, facilitate surgical removal in sensitive areas, and allow complete tumor removal[10,11]. Moreover, normal perfusion pressure breakthrough (NPPB) was not only closely associated with the resection of giant arteriovenous malformation, but also observed in the PFSHs. Yan[12] has reported one case with solid cerebellar hemangioblastoma suffered NPPB during surgery, and gastrointestinal hemorrhage occurred on the second day after operation. Therefore, the patient underwent pre-operative embolisation before surgery, and neither abundant bleeding nor NPPB happened during the subsequent operation.

The combination of preoperative intervention with surgical resection is an effective strategy in the treatment of giant recurrent PFSH, which makes it possible to operate on patients who were previously regarded as inoperable. In addition, emphasis is placed on key principles of giant recurrent solid hemangioblastoma during excision. The tumor should be excised en bloc, and circumferential dissection within the surrounding gliotic plane would contribute to guarantee the whole resection, especially when plenty of vascular scar tissue and residual silver clips in tumor make it difficult to be excised piecemeal. Other skills such as hypothermia and controlled hypotension are believed to be effective methods to remove solid hemangioblastoma successively[13]. However, Todd[14] reported that intraoperative hypothermia did not improve the neurologic outcome after craniotomy among good-grade patients with aneurismal subarachnoid hemorrhage. Moreover, postoperative bacteremia was more common in the hypothermia group than in the normothermia group. Based on our experience, controlled hypotension in elder patients may result in serious complications such as cerebral infarct due to diminished blood flow and intraoperative hypothermia. Consequently, the operation for present patient was exclusively performed with neurophysiological monitoring of brain stem, facial and trigeminal nerves to guide the extent of removal. The most important advantage of neurophysiological monitoring is avoiding brain stem injury. The boundary of tumor and brain stem in this case could not be differentiated after two operations. Once operation contacts the vital structure, stimulation waves would appear for alarming. With the help of neurophysiological monitoring, total resection of tumor was achieved without damaging important brain tissue. The follow-up MRI demonstrated that the tumor had been completely removed. Numerous evidence supported that neurophysiological monitoring during surgery is useful to avoid damaging the vital brain structure, which contributes to safety of operation and decrease of postoperative disability rate[15,16]. Recent study similarly showed that intraoperative sonography was useful to significantly reduce the surgical time and ensure thorough resection of the tumor. Thus real-time intraoperative sonography was recommended as a routine procedure in the surgical treatment of hemangioblastoma[17].

Even in present rare case with tertiary recurrent PFSGs, an optimal result was still obtained under microsurgical

treatment combined with unique skills including preoperative embolization and neurophysiological monitoring. Especially for large PFSGs (diameter exceeding 4 cm) with obstructive hydrocephalus, microsurgical therapy should be the first choice as the most effective method. Gamma knife radiosurgery was thought to be necessary only for subtotal resection of PFSG.

References

1. Dow GR, Sim DW, O'Sullivan MG. Excision of large solid haemangioblastomas of the cerebellopontine angle by a skull base approach. Br J Neurosurg 2002; 16(2): 168 – 71.
2. Kamitani H, Hirano N, Takigawa H, *et al*. Attenuation of vascularity by preoperative radiosurgery facilitates total removal of a hypervascular hemangioblastoma at the cerebello-pontine angle: case report. Surg Neurol 2004; 62(3): 238 – 43.
3. Zhou L, Du G. Diagnosis and surgical treatment of posterior fossa solid hemangioblastomas. Chin Med J (Engl) 2000; 113(2): 129 – 32.
4. Wu ZL, Shi JX, Hang CH, *et al*. Clinical and pathological characteristics of intracranial haemangioblastoma. Chinese Journal of Surgery 2003; 41(8): 614 – 6.
5. Ertas G, Altundag MB, Ucer AR, *et al*. Treatment of recurrent cerebellar hemangioblastoma with external radiotherapy in a patient with von Hippel-Lindau disease: a case report and review of the literature. J Neurooncol 2005; 73(3): 273 – 5.
6. Rajaraman C, Rowe JG, Walton L, *et al*. Treatment options for von Hippel-Lindau's haemangioblastomatosis: the role of gamma knife stereotactic radiosurgery. Br J Neurosurg 2004; 18(4): 338 – 42.
7. Tago M, Terahara A, Shin M, *et al*. Gamma knife surgery for hemangioblastomas. J Neurosurg 2005; 102(Suppl): 171 – 4.
8. Wolff R, Karlsson B, Dettmann E, *et al*. Pertreatment radiation induced oedema causing acute hydrocephalus after radiosurgery for multiple cerebellar metastases. Acta Neurochir (Wien) 2003; 145(8): 691 – 6.
9. Wang EM, Pan L, Wang BJ, *et al*. The long-term results of gamma knife radiosurgery for hemangioblastomas of the brain. J Neurosurg 2005; 102(Suppl): 225 – 9.
10. Abo-AI Hassan A, Ismail M, Panda SM. Pre-operative endovascular embolization of a cerebellar haemangioblastoma: a case report. Med Princ Pract 2006; 15(6): 459 – 62.
11. Vazquez-Anon V, Botella C, Beltran A, *et al*. Preoperative embolization of solid cervicomedullary junction hemangioblastomas: report of two cases. Neuroradiology 1997; 39(2): 86 – 9.
12. Yan PX, Wang ZC, Yu CJ, *et al*. The diagnosis and microsurgical treatment of solid cerebellar hemangioreticuloma. Chinese Journal of Surgery 2004; 42(13): 777 – 80.
13. Zhou LF, Du GH, Mao Y, *et al*. Diagnosis and surgical treatment of brainstem hemangioblastomas. Surg Neurol 2005; 63(4): 307 – 16.
14. Todd MM, Hindman BJ, Clarke WR, *et al*. Mild intraoperative hypothermia during surgery for intracranial aneurysm. N Engl J Med 2005; 352: 135 – 45.
15. Kombos T, Suess O, Ciklatekerlio O, *et al*. Monitoring of intraoperative motor evoked potentials to increase the safety of surgery in and around the motor cortex. J Neurosurg 2001; 95(4): 608 – 14.
16. Yoshikawa K, Kajiwara K, Morioka J, *et al*. Improvement of functional outcome after radical surgery in glioblastoma patients: the efficacy of a navigation-guided fence-post procedure and neurophysiological monitoring. J Neurooncol 2006; 78(1): 91 – 7.
17. Wang Y, Wang Y, Gao X, *et al*. Intraoperative sonographically guided resection of hemangioblastoma in the cerebellum. J Clin Ultrasound 2006; 34(5): 247 – 49.