

In vivo confocal microscopic characteristics of fungal keratitis

Liya Wang^{1,*}, Jun Zhang², Shengtao Sun¹, Yueqin Zhang¹

¹Henan Ophthalmological Institute, Henan Key Laboratory of Keratopathy, Zhengzhou, Henan 450006, China; ²Department of Ophthalmology, The First Affiliate Hospital of Zhengzhou University, Henan Ophthalmological Institute, Henan Key Laboratory of Keratopathy, Zhengzhou, Henan 450006, China

Received January 30, 2008

Abstract

Objective. To analyze the images of fungal keratitis using confocal microscope *in vivo*. **Methods.** Thirty-eight patients, who were confirmed fungus infection by confocal microscopy, 10% KOH smear and fungal culture. The images were analyzed visually for morphology of the hyphae and the spore, as well as the length and the diameter of the hyphae and the spores were counted by NAVIS software. **Results.** (1) In 9 eyes, the branching hyper-reflective structures were revealed under confocal microscope. The diameter of the hyphae ranged 2 to 4 μm . (2) In 16 eyes, long line hyper-reflective structures were appeared under confocal microscope. The diameter of the hyphae ranged 3 to 6 μm and 150 – 300 μm in length. (3) In 11 patients, short rod hyper-reflective structures were showed *in vivo* confocal microscopy. The diameter ranged 3 to 6 μm and 40 to 60 μm in length. (4) In 2 cases, the round to oval hyper-reflective structures were detected by confocal microscopy. The diameter of the bulbs ranged from 12 to 15 μm . **Conclusions.** Confocal microscopy is a useful diagnostic tool to evaluate microscopic aspects of the hyphae and the spores *in vivo* of fungal keratitis. The hyphae appeared different configuration in different kinds of fungal keratitis, as well as in different layers of the cornea under confocal microscope. [Life Science Journal. 2008; 5(1): 51 – 54] (ISSN: 1097 – 8135).

Keywords: confocal microscopy; hyphae; spores; fungal keratitis

1 Introduction

Fungal keratitis is a major blinding eye disease in Asia. In China, the incidence of fungal keratitis has increased significantly during the past decade^[1]. How to diagnose fungal keratitis in early stage becomes a hard work for ophthalmologist at present. Laboratory diagnosis can be made by means of smear, staining, fungal culture, polymerase chain reaction, and confocal microscopy. Confocal microscopy is a relatively new, noninvasive technique for imaging the cornea in normal and abnormal states^[2]. Avunduk *et al*^[3] found that confocal microscopy was more sensitive in examining *Aspergillus fumigatus* keratitis *in vivo* than *in vitro*. Currently, the characteristic of fungal keratitis observed by confocal microscopy *in vivo* has not been clearly understood. In this study, we have investigated the characteristics of fungal keratitis by serial

image of confocal microscope, 10% KOH smear and fungal culture to establish the reliability and value of this technique in fungal keratitis diagnosis.

2 Materials and Methods

In this hospital-based retrospective study, we reviewed the medical history data of 38 patients with fungal keratitis visited at Henan Ophthalmological Institute between March 2006 and October 2006. All patients underwent laboratory investigations after ophthalmic examination and *in vivo* confocal microscopy: direct microscopic evaluation and corneal scraping culture. Thirty-eight patients (38 eyes) confirmed fungal keratitis were enrolled in this study. A diagnosis of fungal keratitis was made when corneal scraping examination revealed fungal presence in smears. Microbial cultures and confocal microscopic examination were performed 38 cases of patients with diagnosis of fungal keratitis. The clinical diagnosis was made

*Corresponding author. Email: Liyawang55@163.com

on the basis of the history of ocular trauma, and the corneal infiltrate with gray, elevated necrotic slough, and feathery margin in the cornea. The culture materials were collected from the corneal scraping in all patients at their first visit to our clinic. The samples were directly inoculated onto four medium, including blood agar, chocolate agar, sabouraud dextrose agar (SDA), and eosin methylene blue agar. Sabouraud dextrose agar plates were incubated at room temperature. The other three plates were maintained at 35 °C. The cultures were considered positive for fungus if the same color and morphology of colonies grew on more than two plates. All the patients underwent examination with a slit scanning confocal microscope Model 3 (confoscan 3 Fortane technologie Sal Italy). Each video frame displays a 440 $\mu\text{m} \times 330 \mu\text{m}$ focused area. Lateral resolution of the confocal microscope in the x, y plane is 1 μm or less, and z-axis resolution is approximately 5 μm . In contrast to a slit lamp where the maximum magnification is between 16 \times and 40 \times , the magnification of confocal microscope is 1000 \times . The curve of Z-Scan mold of confocal microscope represents the intensity profile of reflected light at each corneal layer. So the approximate depth of focus within the tissue can be determined by using the electronic Z-Scan mold. Image obtained from the clearest frame. Informed consent was obtained from all subjects for their participation in this study.

3 Results

38 patients have been diagnosed fungal keratitis by fungal culture and isolation. The subjects (38 eyes) com-

prised of 23 male and 15 female (17 – 75 years old), with mean age of 43 ± 12.1 years old. The duration from the onset of symptoms to presentation to our institution ranged from 3 – 45 days, with mean time 12 days. Every image of confocal microscope of all patients has been investigated by ophthalmologist and compared with the images of corneal scraping under microscope. Confocal microscopy of infiltrates revealed a high reflective substance at the center of ulcers. Confocal microscopy at the edge of infiltrates showed many kinds of hyphae and spores including branching hyper-reflective structures, bright line hyper-reflective structures, short rod hyper-reflective structures and round to oval hyper-reflective structures. Confocal scans from 9 patients revealed interlocking white lines, 4 μm in width (Figure 1). In 16 eyes, bright line hyper-reflective structures were appeared under confocal microscope. The diameter of the hyphae ranged 3 to 6 μm and 150 – 300 μm in length (Figure 2). In 11 patients, short rod hyper-reflective structures were checked (Figure 3). The diameter of the structures ranged 3 to 6 μm and 40 – 60 μm in length. In 2 cases, the round to oval hyper-reflective structures were detected (Figure 4). The diameter of the bulbs ranged 12 to 15 μm . The hyper-reflective structures were located parallel to the corneal surface in the superficial or middle of stroma. Fungal filaments were best seen at the edge of the infiltrate against a dark background due to the lower reflectivity. In doubtful scans, these filaments were seen clearly on inversion of bright and dark component. All of these filaments and oval bright structures on the corneal scraping smear also revealed under microscopy with morphology similar to that of the structures *in vivo*.

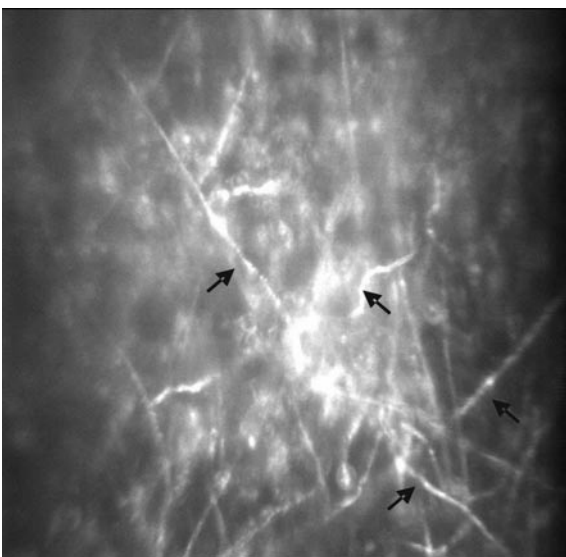


Figure 1. The branch hyper-reflective structure ($\times 1000$).



Figure 2. The long line hyper-reflective structures ($\times 1000$).

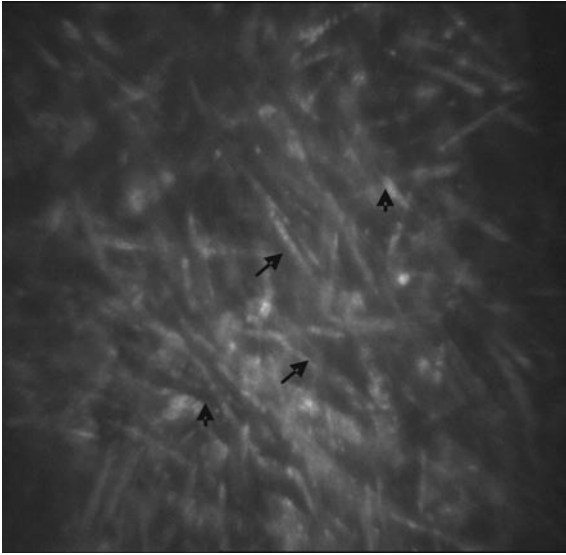

Figure 3. The short rod hyper-reflective structures ($\times 1000$).

Table 1 summarized the spectrum of thirty-eight eyes of 38 patients. Four genera were involved in this group of patients, including 18 (47.5%) isolates of fusarium species.

Table 1. Spectrum of 38 cases fungal keratitis

Species	Number of isolation	Percentage (%)
<i>Fusarium</i>	18	47.5
<i>Aspergillus</i>	7	18.8
<i>Alternaria</i>	6	16.3
<i>Penicillium</i>	3	7.5
Unidentified	4	10.5
Total	38	100

4 Discussion

Filamentous fungi are the commonest cause of mycotic keratitis in many countries in tropical latitudes and it is vital that a specific diagnosis is made as clearly as possible to ensure prompt institution of anti-fungal therapy^[4,5]. Our results also show filamentous fungi predominated in the fungal pathogens isolated in this region (Table 1). Although confocal microscopy examination may help to reach a rapid presumptive diagnosis, the *in vivo* confocal microscopic characteristic of fungal keratitis continues to be confused so many ophthalmologists. To date, direct microscopic examination of corneal scraping samples with potassium hydroxide wet mounts is leading technology. The positive rate of direct microscopic examination of potassium hydroxide wet mount was from 62% to 91% in




Figure 4. The round to oval hyper-reflective structure ($\times 1000$).

different reports^[6,7]. We could observe the clear and sharp picture of hyphae and spores with undisturbed structure and relationships under microscope, but this laboratory diagnostic methods is invasive. So the non-invasive reliable rapid diagnostic tools such as *in vivo* confocal microscopy may play an important role in fungal keratitis.

In this study, we selected 38 patients who were underwent corneal scraping, confocal microscopic examination and fungal culture simultaneously. On microscopy, they appeared thin, extensively branching, beaded filaments and sometimes round to oval spores also can be found. All of these structures also could be found *in vivo* confocal microscopy. Identification of the fungal organisms from confocal microscopy images is important, not only for rapidly diagnosing the fungal keratitis but also for monitoring the therapy of antifungal drugs^[8]. The results showed that all of the fungal keratitis appeared four kinds of characteristic *in vivo* confocal microscopy. Including (1) branching hyper-reflective structures: in this kind of structures, the hyphae appeared interlocking white lines, 2 to 4 μm in width in the superficial stroma (Figure 1). The interlocking white lines were located paralleled to the corneal surface with branching at all kinds of angle which made the hyphae wove together forming reticulation. This kind of structures can appear some kinds of physiological curve similar to hyphae showed under microscope. (2) The long line hyper-reflective structures: in this kind of structures, the confocal microscopy revealed long-line structures, 3 to 6 μm in width and 50 – 300 μm in length in the superficial or middle stroma (Figure 2). Typically, this kinds of hyphae run all kinds of orientation. (3) The

short rod hyper-reflective structures. The length of this kind of structure is a few short rather than long line hyper-reflective structure. This kind of structures appeared 3 to 6 μm in width and 40 – 60 μm in length (Figure 3). This kind of structures was observed in the superficial or middle layer of cornea in 11 eyes examined. Recently, Emmanuelle Brasnu and Tristan Bourcier reported a case in which HRTII-RCM examination of the *Candida albicans*-infected patient's cornea revealed numerous high-contrast elongated particles in anterior stroma, resembling *Candida* pseudofilaments^[9]. But in our study, this kind of particles was not appeared in pseudofilaments-inflected keratitis. The real reason is not clear. (4) The round to oval structure. It is difficult to observe the spores under confocal microscope. In the present study, we only found these structures in 2 eyes. Light microscopy of the corneal scraping of the 2 cases confirmed that the round to oval appearance in stroma using confocal microscopy was consistent with spores in stroma. In slight different planes, the organisms can appear as bright, round structures and between these planes they may be oval shaped. This observation may contribute to the variability seen in measuring the diameter of the spores by tandem scanning confocal microscopy. The diameter of the spores measured between 12 μm and 15 μm (Figure 4).

Using *in vivo* confocal microscopy for the present study of fungal keratitis, the hyphae always is taken as the corneal nerve in the anterior or midcorneal stroma. The nerve appears regular, elongated, and uniform and has a sharp margin (stromal nerves) or beaded (sub-basal plexus) structures that have an acute angled branching pattern and vary between 5 and 20 μm in thickness. Other linear structures such as fabric trabes in the repairing cornea always reflect not as brightly as the hyphae in stroma. In addition, the fabric trabes appear shaggy border compared with the hyphae in the inset. Moreover, few inflammation cells can find around the fabric trabes. In some cases, the morphology of the active keratocytes is similar to the hyphae. The active keratocytes which nuclei elongate demonstrated spindle-like, less than 30 μm in length^[10]. Some normal keratocytes morphology has also been shown around the active keratocyte. Otherwise, the spores always are taken as the *Acanthamoeba* cysts.

Usually, the *Acanthamoeba* cysts can appear bright round structure with double-walled organism^[11]. Furthermore, radial keratoneuritis was demonstrated, consisting of an irregularly swollen nerve fiber with probable amoebic infiltration. Otherwise, these patients always have the worn lens history before going to see ophthalmologist.

5 Conclusion

This study presents the characteristics of *in vivo* confocal microscopy findings of the largest series of fungal keratitis among the population in our region. Confocal microscopy is a useful diagnostic tool to evaluate microscopic aspects of the hyphae and the spore's morphologic changes in fungal keratitis. Hyphae appeared different configuration in different kinds of fungal keratitis, as well as in different layers of the cornea under confocal microscope.

References

1. Wang LY, Zhang Y, Wang Y, *et al.* Spectrum of mycotic keratitis in China. *Chinese Journal of Ophthalmology* 2000; 36(2): 138 – 40.
2. Florakis GJ, Moazami G, Schubert H, *et al.* Scanning slit confocal microscopy of fungal keratitis. *Arch Ophthalmol* 1997; 115: 1461 – 3.
3. Avunduk AM, Beuerman RW, Varnell ED, *et al.* Confocal microscopy of *Aspergillus fumigatus* keratitis. *Br J Ophthalmol* 2003; 87: 409 – 10.
4. Hagan M, Wright E, Newman M, *et al.* Causes of suppurative keratitis in Ghana. *Br J Ophthalmol* 1995; 79: 1042 – 8.
5. Bharathi MJ, Ramakrishnan R, Vasu S, *et al.* Epidemiological characteristics and laboratory diagnosis of fungal keratitis: a three year study. *Indian J Ophthalmol* 2003; 51: 315 – 21.
6. Chowdhary A, Singh K. Spectrum of fungal keratitis in north India. *Cornea* 2005; 24; 8 – 15.
7. Gopinathan U, Garg P, Fernandes M, *et al.* The epidemiological features and laboratory results of fungal keratitis: a 10-year review at a referral eye care center in south India. *Cornea* 2002; 21: 555 – 9.
8. Shi WY, Niu XG, Wang FH, *et al.* Evaluation of anti-fungal chemotherapeutic effects on fungal keratitis by confocal microscopy. *Chin J Ophthalmol* 2005; 41: 614 – 9.
9. Emmanuelle B, Tristan B, Bénédict D, *et al.* *In vivo* confocal microscopy in fungal keratitis. *Br J Ophthalmol* 2007; 91: 588 – 91.
10. Kaufman SC, Musch DC, Belin MW, *et al.* Confocal microscopy: a report by the American of ophthalmology. *Ophthalmology* 2004; 111: 396 – 406.
11. Pfister DR, Cameron JD, Krachmer, Krachmer, *et al.* Confocal microscopy findings of *Acanthamoeba* keratitis. *AM J Ophthalmol* 1996; 121: 119 – 28.